

PATIENT

Scotch Heise

SPECIES

Feline

BREED

DSH

SEX

Spayed Female

AGE

12 Years

WEIGHT

5.24 kg

INTERPRETED BY

Beth Johnson, DVM
 DACVIM

IMAGING PERFORMED BY

Amanda Stewart

HOSPITAL NAME

New Hamburg

REFERRING VET

Dr. Allison

INVOICE

35900

DATE

12/15/25

PRESENTING CLINICAL SIGNS

History: Findings: - Dental tartar - Normal thoracic aus - Soft abdomen on palpation - Unexplained weight loss, 1.2kg weight loss in last year Current Medications None

Abnormal PE/Chem/CBC/UA Results: Values -Normal CBC/Biochem/lytes/ TT4 19 mmol/L - SG 1.041, PH 5, 1+ protein Radiographic Findings None performed

ULTRASONOGRAPHIC EXAMINATION OF THE ABDOMEN

Urinary System

Urinary bladder is adequately distended with anechoic contents. No masses, inflammatory changes, echogenic sediment or cystoliths are observed. The urinary bladder, trigone and visible pelvic urethra are normal in thickness with a smooth mucosal surface.

Left kidney is normal in size (3.99 cm), shape and echogenicity. It has smooth peripheral margination. There is a normal 1:3 cortex to medulla ratio with appropriate corticomedullary distinction. There is no evidence of pyelectasia, mineral or infarcts observed.

Right kidney is normal in size (3.98 cm), shape and echogenicity. It has smooth peripheral margination. There is a normal 1:3 cortex to medulla ratio with appropriate corticomedullary distinction. There is no evidence of pyelectasia, mineral or infarcts observed.

Adrenal Glands

Left adrenal gland is normal in size (0.3 cm), shape and overall architecture, echogenicity and echotexture. Visible surrounding vasculature appears normal.

Right adrenal gland is normal in size (0.27 cm), shape and overall architecture, echogenicity and echotexture. Visible surrounding vasculature appears normal.

Spleen

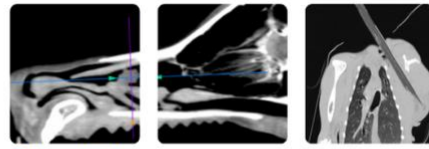
Spleen is subjectively normal in size with a normal smooth capsular contour. Parenchyma is appropriately finely textured and homogenous with normal echogenicity relative to surrounding tissue (hyperechoic to liver). No focal nodules or masses are observed. Splenic vasculature appears normal.

Liver

Liver is subjectively normal in size with normal smooth curvilinear peripheral contour. Parenchyma is appropriately hypoechoic to the spleen in echogenicity and appropriately mildly coarse and homogenous in echotexture. No focal lesions are observed. Visible vasculature and biliary tree appear normal without distension or congestion.

Gallbladder is non-distended in size. The wall is smooth without visible thickening. Luminal contents are primarily anechoic. There is no evidence of cystic or common bile duct dilation.

Gastrointestinal



PATIENT

Scotch Heise

The visible stomach wall is normal in thickness and layering. The lumen of the stomach is empty with no evidence of obstruction, foreign material or infiltrative disease. Pyloric outflow tract appears patent.

SPECIES

Feline

The visible small intestine demonstrates areas of moderate to severely thick muscularis layer relative to mucosa (disruption of the normal 1:3 muscularis:mucosa ratio). Small intestinal submucosa is slightly irregular, thick and hyperechoic, without evident loss of layering appreciated. The lumen of the small intestine is empty with no evidence of obstruction or foreign material.

BREED

DSH

The visible colon is normal in wall thickness (< 0.2 cm) and layering. Contents are consistent with normal formed feces and gas.

SEX

Spayed Female

Pancreas

The pancreas that is observed appears appropriately isoechoic to surrounding omental fat. Visible capsule is smooth and normal in contour. Visible pancreatic parenchyma is homogenous and unremarkable. There is no visible pancreatic duct dilation. There is no evidence of active peripancreatic inflammation.

AGE

12 Years

Free Abdomen

There is no visible free peritoneal effusion noted in these images.

WEIGHT

5.24 kg

There is no apparent pathologic lymphadenopathy noted in these images.

INTERPRETED BY

Beth Johnson, DVM
 DACVIM

ULTRASONOGRAPHIC FINDINGS

- Moderate inflammatory bowel disease pattern- Thick muscularis has been reported with infiltrative bowel disease including both benign inflammatory disease as well as infiltrative neoplasia such as lymphoma. No loss of layering or distinct characteristics of malignancy are present. Therefore, differentials cannot be further ranked without tissue sampling.

IMAGING PERFORMED BY

Amanda Stewart

INTERPRETATION OF THE FINDINGS & FURTHER RECOMMENDATIONS

HOSPITAL NAME

New Hamburg

- A gastrointestinal malabsorption panel (including cobalamin, folate, TLI and PLI) to Texas A&M GI Laboratory is recommended for further evaluation of GI and pancreatic function.
- Ideally, biopsies of the GI tract, being sure to include ileum, if possible, are recommended to definitively diagnose and therefore manage the infiltrative bowel disease.
- If biopsies cannot be obtained, empirical therapies could include a probiotic (if diarrhea is present, such as visbiome or proviable), empirical deworming with a 5-day course of Panacur and, if tolerated, a transition in diet, based on trial-and-error response, beginning with a hydrolyzed protein diet. Some patients respond to one brand/version of a hydrolyzed protein diet better than another brand, so several trials may be required.

REFERRING VET

Dr. Allison

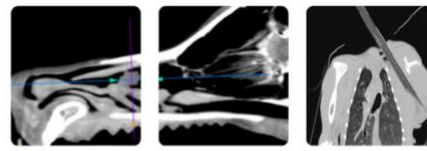
INVOICE

35900

DATE

12/15/25

- Additional considerations could include cobalamin supplementation (unless cobalamin level is evaluated and supplementation is not warranted) and prednisolone (if not contraindicated based on patient contraindications, co-morbidities, etc.).



PATIENT

Scotch Heise

SPECIES

Feline

BREED

DSH

SEX

Spayed Female

AGE

12 Years

WEIGHT

5.24 kg

INTERPRETED BY

Beth Johnson, DVM
 DACVIM

IMAGING PERFORMED BY

Amanda Stewart

HOSPITAL NAME

New Hamburg

REFERRING VET

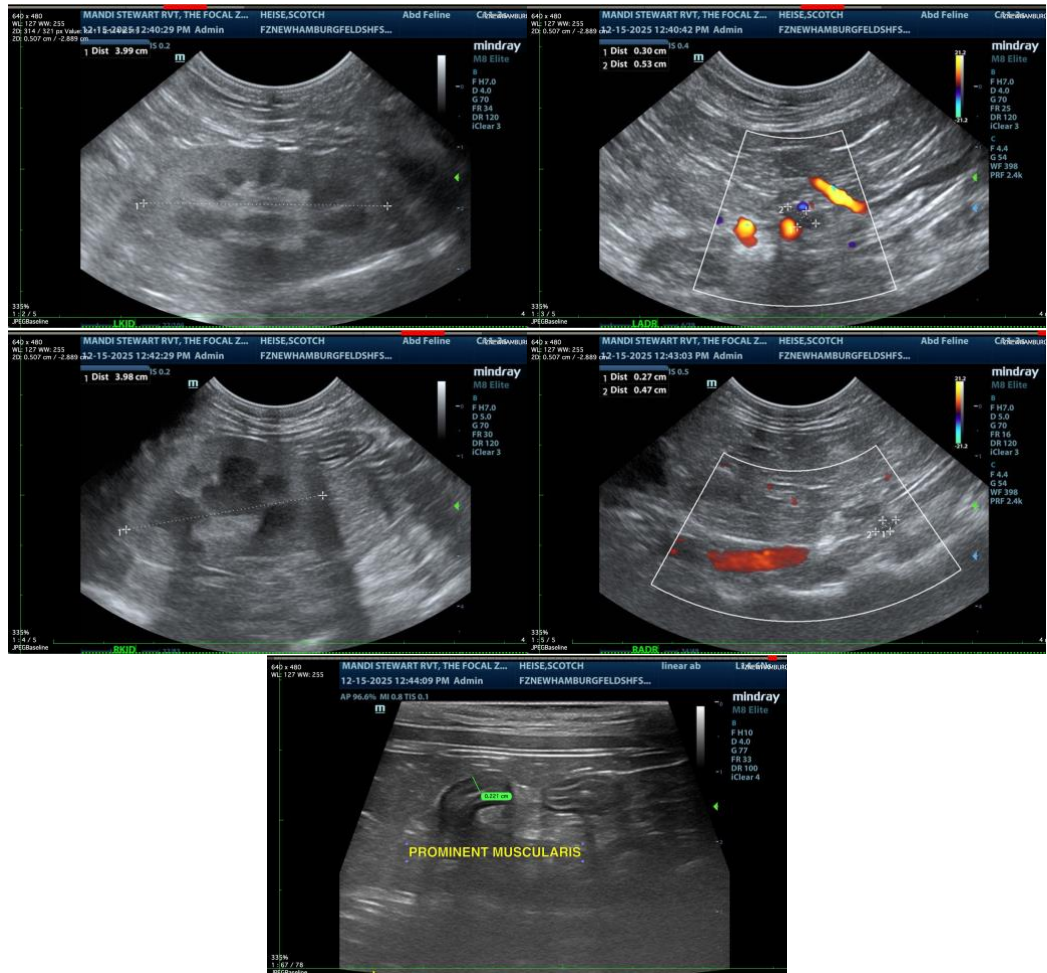
Dr. Allison

INVOICE

35900

DATE

12/15/25



The information and recommendations provided are based on the images presented by the referring veterinarian/sonographer. No evaluation can be communicated regarding pathology that was not visible in the image/video clips provided.

Thank you for this referral. If the clinical or image interpretation does not parallel your findings or if I can be of any further assistance please contact me.

Beth Johnson, DVM DACVIM

info@sonopath.com