



PATIENT

Sadie Steelman

SPECIES

Canine

BREED

Mixed Breed

SEX

Spayed Female

AGE

16 Years 11 Months

WEIGHT

7.4 Pounds

INTERPRETED BY

Beth Johnson, DVM
DACVIM

IMAGING PERFORMED BY

Kathleen Byrnes

HOSPITAL NAME

Animal Hospital of
Boone

REFERRING VET

Dr. Watson

INVOICE

35901

DATE

12/15/25

PRESENTING CLINICAL SIGNS

History: P presented for US due to V/D and lethargy, V/D has improved, and p ate a small amount this morning.

Abnormal PE/Chem/CBC/UA Results: Lymph 0.54, Eos 0.04 BUN 30, TP 8.3, Glob 5.2

ULTRASONOGRAPHIC EXAMINATION OF THE ABDOMEN

Urinary System

Urinary bladder is adequately distended. It has a normal uniform wall thickness. Contents include primarily anechoic fluid with a mild amount of echogenic non-shadowing debris, most consistent with exfoliated cells, mucous and/or small blood clots. Both sterile inflammation as well as urinary tract infection can present with echogenic debris. No masses or cystoliths are observed. The trigone and visible pelvic urethra are normal in thickness with a smooth mucosal surface.

Left kidney is normal in size (3.53 cm), shape and echogenicity. It has smooth peripheral margination. There is a normal 1:3 cortex to medulla ratio with appropriate corticomedullary distinction. There is no evidence of pyelectasia, mineral or infarcts observed.

The right kidney is normal in size, but subjectively flat/thin, but measures 3.5 cm long. It is irregular and diffusely echogenic with decreased corticomedullary distinction and poor visualization of internal architecture. There is no pyelectasia noted and no mineral is observed.

Adrenal Glands

Left adrenal gland is normal in size (0.42 cm at cranial pole and 0.41 cm at caudal pole), shape and overall architecture, echogenicity and echotexture. Visible surrounding vasculature appears normal.

Right adrenal gland is normal in size (0.62 cm at cranial pole and 0.56 cm at caudal pole), shape and overall architecture, echogenicity and echotexture. Visible surrounding vasculature appears normal.

Spleen

Spleen is subjectively normal in size with a normal smooth capsular contour. Parenchyma is appropriately finely textured and homogenous with normal echogenicity relative to surrounding tissue (hyperechoic to liver). Multifocal well-demarcated hyperechoic homogenous nodules are noted. Splenic vasculature appears normal.

Liver

Liver is subjectively normal in size with normal smooth curvilinear peripheral contour. Parenchyma is appropriately hypoechoic to the spleen in echogenicity and appropriately mildly coarse and homogenous in echotexture. No focal lesions are observed. Visible vasculature and biliary tree appear normal without distension or congestion.

Gallbladder is non-distended in size. The wall is smooth without visible thickening. Luminal contents are primarily anechoic. There is no evidence of cystic or common bile duct dilation.

Gastrointestinal



PATIENT

Sadie Steelman

What I believe is the caudal portion of the stomach, demonstrates some very mildly thick wall measuring 0.6 cm thick, with a mildly heterogenous appearance to the wall. The remaining stomach is normal in thickness and layering and the lumen is empty with no evidence of obstruction, foreign material or infiltrative disease. Pyloric outflow tract appears patent.

SPECIES

Canine

The visible small intestines are normal in wall thickness and layering. Small intestinal motility appears adequate (1-3 contractions per min). The lumen of the small intestine is empty with no evidence of obstruction, foreign material or infiltrative disease.

BREED

Mixed Breed

The visible colon is normal in wall thickness (< 0.2 cm) and layering. Contents are consistent with normal formed feces and gas.

SEX

Spayed Female

Pancreas

The pancreas that is observed appears appropriately isoechoic to surrounding omental fat. Visible capsule is smooth and normal in contour. Visible pancreatic parenchyma is homogenous and unremarkable. There is no visible pancreatic duct dilation. There is no evidence of active peripancreatic inflammation.

AGE

16 Years 11 Months

Free Abdomen

There is no visible free peritoneal effusion noted in these images.

WEIGHT

7.4 Pounds

There is no apparent pathologic lymphadenopathy noted in these images.

INTERPRETED BY

Beth Johnson, DVM
 DACVIM

Dorsal to the urinary bladder is a very small 0.22 cm thick ovoid hypoechoic density consistent with a possible very small sublumbar lymph node.

ULTRASONOGRAPHIC FINDINGS

Primary Findings

- The subtle focal gastric wall thickening likely represents a benign gastritis given patient's history- potentially infectious, inflammatory, dietary related, versus other. Having said that, early or emerging infiltrative neoplasia can't be definitively ruled out.
- Mild chronic kidney disease changes, most notable in the right kidney, could indicate early or emerging chronic kidney disease.
- A mild amount of echogenic urinary bladder debris.

Secondary Findings

- Hyperechoic splenic nodules- most consistent with benign myelolipomas. Other differentials such as fibrosis or calcification caused by old hematomas or infarcts, chronic inflammation, granulomatous disease or metastatic disease cannot be ruled out, but are considered less likely.
- Possible very mildly reactive sublumbar lymphadenopathy- infiltrative neoplastic disease cannot be ruled out but is considered less likely.

IMAGING PERFORMED BY

Kathleen Byrnes

HOSPITAL NAME

Animal Hospital of
 Boone

REFERRING VET

Dr. Watson

INVOICE

35901

DATE

12/15/25

INTERPRETATION OF THE FINDINGS & FURTHER RECOMMENDATIONS



PATIENT

Sadie Steelman

If not recently evaluated, urinalysis, and if indicated based on urinalysis results, urine culture is recommended. If protein is present in an otherwise quiet sediment, protein quantification with a urine protein to creatinine ration is recommended.

SPECIES

Canine

Three view thoracic radiographs are recommended for further assessment of cardio-pulmonary status as well as to further evaluate for any evidence of metastatic disease, if not recently evaluated.

BREED

Mixed Breed

A routine fecal/Giardia exam is recommended if not recently evaluated.

A gastrointestinal malabsorption panel (including cobalamin, folate, TLI and PLI) to Texas A&M GI Laboratory is recommended for further evaluation of GI and pancreatic function.

SEX

Spayed Female

A baseline cortisol is recommended. If baseline cortisol is less than 2, a full ACTH stimulation test is recommended to rule out hypoadrenocorticism.

AGE

16 Years 11 Months

If a diagnosis is not obtained, +/- a fecal enteropathogen PCR panel to Texas A&M GI Laboratory could be considered for further evaluation of possible infectious disease. Contact lab for recommendations on how long to discontinue antibiotics (if indicated) prior to obtaining a stool sample for submission.

WEIGHT

7.4 Pounds

Ultimately, if a diagnosis is not obtained and clinical signs persist, tissue sampling may be indicated. Given the mild gastric wall changes, upper GI gastroscopy/endoscopy could be considered for further visual evaluation and biopsies.

INTERPRETED BY

Beth Johnson, DVM
DACVIM

In the meantime:

Supportive/symptomatic medical management of clinical signs is recommended, including anti-emetics, gastroprotectants (+/- sucralfate, especially with any history of hematemesis), an appetite stimulant and fluid therapy if indicated, etc.

IMAGING PERFORMED BY

Kathleen Byrnes

Additionally, empirical deworming with a 5-day course of Panacur is recommended.

A full course of empirical Helicobacter triple therapy could be considered.

A probiotic, such a visbiome or proviable, may be helpful.

HOSPITAL NAME

Animal Hospital of
Boone

Finally, if tolerated, a transition in diet could be considered, based on trial-and-error response with some options to consider including a gastrointestinal biome diet vs a hydrolyzed protein diet (sometimes several trials with different brands are necessary) vs an easy to digest, bland or low-fat diet vs other.

REFERRING VET

Dr. Watson

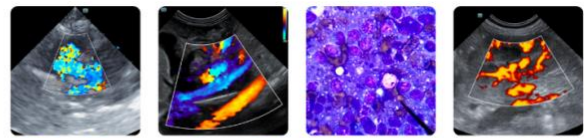
**Given different geographical areas of case submission and different units for labwork reporting, please include units, or a high/versus low/versus normal indicator, reference ranges, or even attach actual labwork results so that labwork abnormalities can be accurately interpreted for recommendations.

INVOICE

35901

DATE

12/15/25



PATIENT

Sadie Steelman

SPECIES

Canine

BREED

Mixed Breed

SEX

Spayed Female

AGE

16 Years 11 Months

WEIGHT

7.4 Pounds

INTERPRETED BY

Beth Johnson, DVM
 DACVIM

IMAGING PERFORMED BY

Kathleen Byrnes

HOSPITAL NAME

Animal Hospital of
 Boone

REFERRING VET

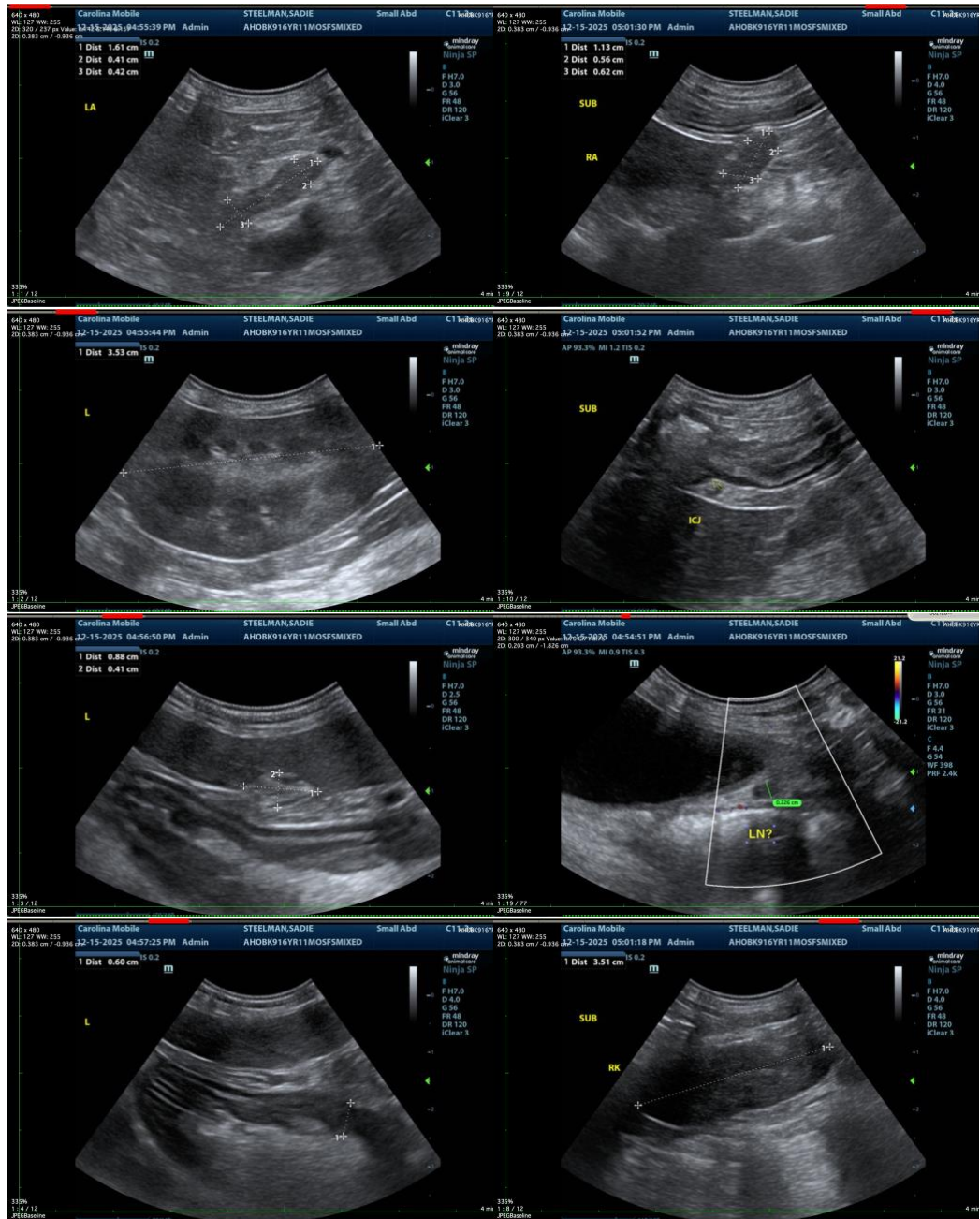
Dr. Watson

INVOICE

35901

DATE

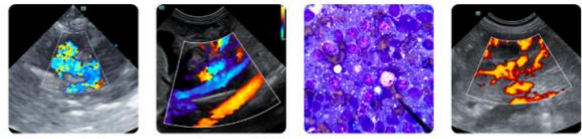
12/15/25



The information and recommendations provided are based on the images presented by the referring veterinarian/sonographer. No evaluation can be communicated regarding pathology that was not visible in the image/video clips provided.

Thank you for this referral. If the clinical or image interpretation does not parallel your findings or if I can be of any further assistance please contact me.

Beth Johnson, DVM DACVIM



PATIENT

info@sonopath.com

Sadie Steelman

SPECIES

Canine

BREED

Mixed Breed

SEX

Spayed Female

AGE

16 Years 11 Months

WEIGHT

7.4 Pounds

INTERPRETED BY

Beth Johnson, DVM
DACVIM

**IMAGING
PERFORMED BY**

Kathleen Byrnes

HOSPITAL NAME

Animal Hospital of
Boone

REFERRING VET

Dr. Watson

INVOICE

35901

DATE

12/15/25