

**DATE PRESENTING CLINICAL SIGNS**

12/14/22

Patient has experienced some recent weight loss, and unkempt haircoat, despite no recent changes to diet, medications, etc. Family history of neoplasia (paternal testicular neoplasia).

PATIENT

Baloo Hodgson

Current Medications: Omega 3 FA supplement, Adequan, Gallilprant, Gabapentin, Glucosamine, chondroitin
Lab Results: 11/27/22: CBC/Chem/UA/T4/FreeT4 unremarkable Patient has history of severe food allergies (primarily GI), well-managed with Ultamino. Multiple historical orthopedic issues, well-managed at this time. Historical Lyme infection.

SPECIES

Canine

Date of Previous IntraPet Ultrasound: No previous.
Sedation: Not required to complete full diagnostic ultrasound.
Stat Report: Not requested.

BREED

Labrador Retriever

ULTRASONOGRAPHIC EXAMINATION OF THE ABDOMEN**SEX**

Neutered Male

Urinary System

The urinary bladder is moderately distended with anechoic contents. No masses or inflammatory changes. A shadowing mineral density within the intraprostatic urethra is noted, which does not appear obstructive. Mineral embedded within the prostatic parenchyma can't be definitively ruled out. The urinary bladder, trigone and visible pelvic urethra are normal in thickness with a smooth mucosal surface.

AGE

10/5/12

Prostate is normal in size, echotexture and echogenicity for a neutered male.

WEIGHT

70 Pounds

The right kidney is normal in size (6.62 cm), shape and echogenicity. It has smooth peripheral margination. There is a normal 1:3 cortex to medulla ratio with appropriate corticomedullary distinction. There is no evidence of pyelectasia, mineral or infarcts observed.

INTERPRETED BYBeth Johnson, DVM
DACVIM

The left kidney is normal in size (5.61 cm), shape and echogenicity. It has smooth peripheral margination. There is a normal 1:3 cortex to medulla ratio with appropriate corticomedullary distinction. There is no evidence of pyelectasia, mineral or infarcts observed.

IMAGING PERFORMED BYStephanie Warga
RDMS, RVT**Adrenal Glands**

The right adrenal gland is normal in size (3.16 cm long x 0.52 cm at the cranial pole and 0.52 cm at the caudal pole), shape and contour. Corticomedullary structure is unremarkable. Visible surrounding vasculature appears normal.

HOSPITAL NAME

Banfield Columbia

The left adrenal gland is normal in size (2.44 cm long x 0.65 cm at the cranial pole and 0.69 cm at the caudal pole), shape and contour. Corticomedullary structure is unremarkable. Visible surrounding vasculature appears normal.

REFERRING VET

Dr. Wendell

Spleen

The spleen is subjectively normal in size with a normal smooth capsular contour. Parenchyma is appropriately finely textured and homogenous with normal echogenicity relative to surrounding tissue (hyperechoic to liver). No focal nodules or masses are observed. Splenic vasculature appears normal.

INVOICE

43458

Liver

The liver is subjectively normal in size with normal smooth curvilinear peripheral contour. Parenchyma is appropriately hypoechoic to the spleen in echogenicity and appropriately mildly coarse and homogenous in echotexture. No focal lesions are observed. Visible vasculature and biliary tree appear normal without distension or congestion.

Gallbladder is moderately distended with anechoic bile as well as mild suspended and gravity dependent echogenic debris. Given the appearance of the debris adhered to the inner wall, a benign polyp can't be

definitively ruled out. The wall is smooth without visible thickening. There is no evidence of cystic or CBD dilation. There is no evidence of effusion or inflammation.

Gastrointestinal

The visible stomach wall is normal in thickness and layering. The lumen of the stomach is mildly distended with echogenic non-shadowing luminal contents and gas consistent with normal ingesta. There is no evidence of obstruction, foreign material or infiltrative disease. Pyloric outflow tract appears patent.

The visible small intestines are normal in wall thickness and layering. Small intestinal motility appears adequate (1-3 contractions per min). The lumen of the small intestine is mildly distended with echogenic non-shadowing luminal contents and gas consistent with normal ingesta. There is no evidence of obstruction, foreign material or infiltrative disease.

The visible colon is normal in wall thickness (< 0.2 cm) and layering. Contents are consistent with normal formed feces and gas.

Pancreas

The pancreatic parenchyma is appropriately isoechoic to surrounding tissue. Visible capsule is smooth and normal in contour. There is no visible pancreatic duct dilation. There is no evidence of active peripancreatic inflammation.

Free Abdomen

There is no evidence of free peritoneal effusion noted in these images.

There is no apparent lymphadenopathy noted in these images.

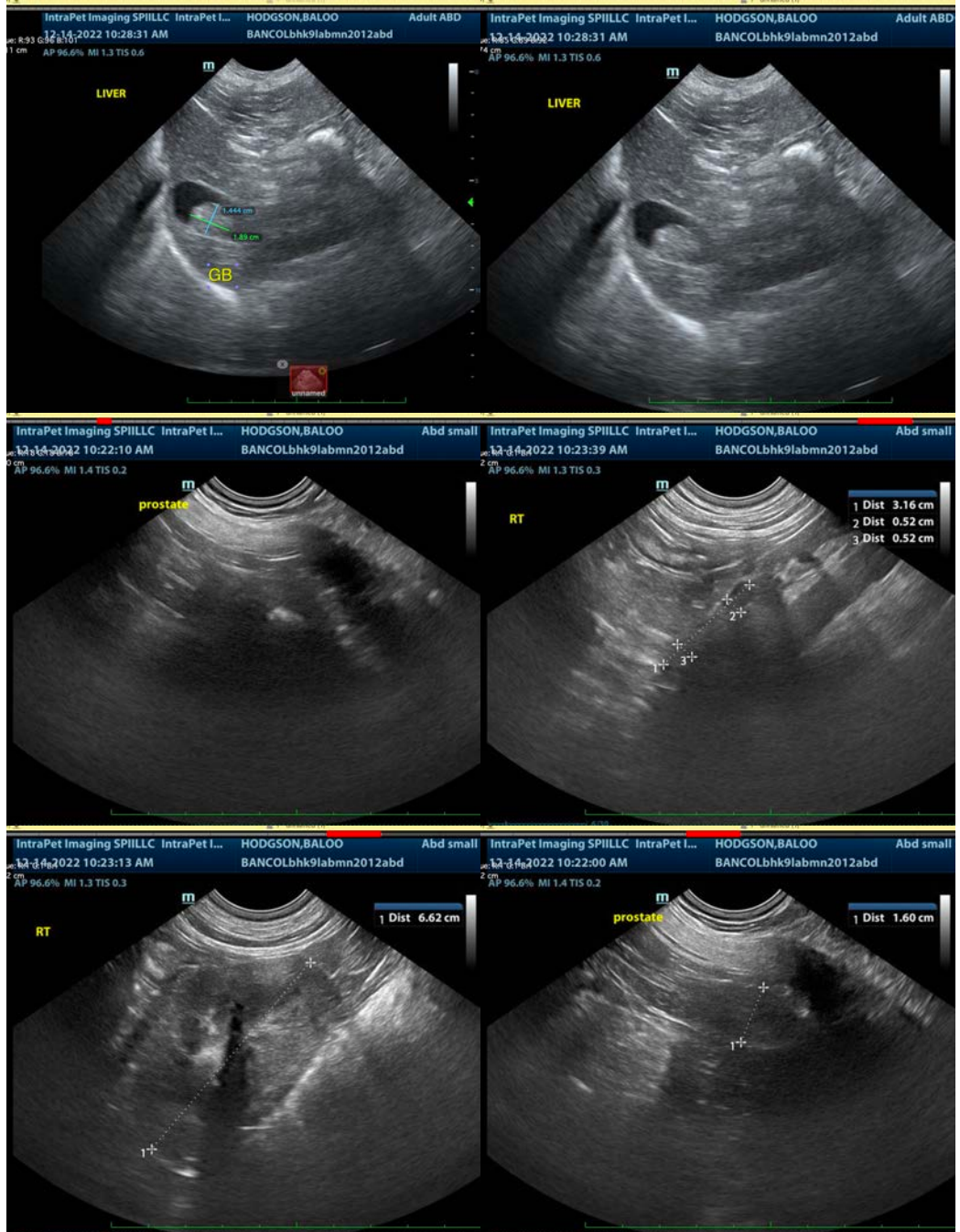
ULTRASONOGRAPHIC FINDINGS

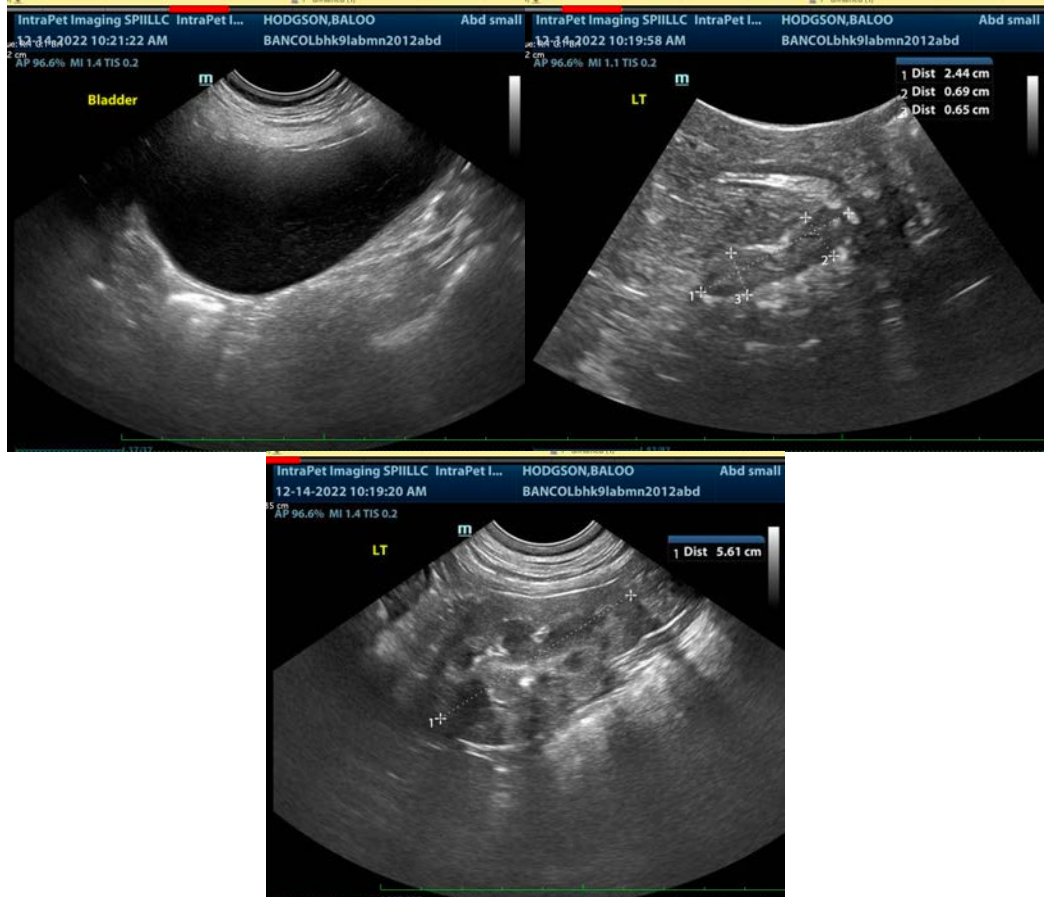
- **Mild gallbladder debris** - Cholecystic debris is of unknown clinical significance. It can be seen with biliary stasis from fasting or illness. Cholecystic debris is not necessarily related to hepatobiliary disease. Echogenic bile is most commonly an incidental finding in dogs and should be interpreted in combination with clinical signs such as nausea, inappetence, cranial abdominal discomfort and/or laboratory changes such as increased ALP and/or increased Tbili. A benign polyp cannot be definitively ruled out.
- Mineral density at the level of the intraprostatic urethra

INTERPRETATION OF THE FINDINGS & FURTHER RECOMMENDATIONS

This is a largely unremarkable/normal abdomen without an obvious cause for the patient's reported weight loss. Without laboratory changes or clinical signs to raise concern over gallbladder disease, monitoring of the sludge/polyp is recommended, and the same goes for the urinary tract mineral described above.

Given this patient's history of gastrointestinal disease, possible progression of the GI disease may be the cause for the weight loss. Recommendations are to further evaluate digestion and absorption, beginning with a gastrointestinal malabsorption panel (including cobalamin, folate, TLI and PLI) to Texas A&M GI Laboratory.





The information and recommendations provided are based on the images presented by the referring veterinarian/sonographer. No evaluation can be communicated regarding pathology that was not visible in the image/video clips provided.

Thank you for this referral. If the clinical or image interpretation does not parallel your findings or if I can be of any further assistance please contact me.

Beth Johnson, DVM, DACVIM
Beth.Johnson@sonopath.com