



PATIENT PRESENTING CLINICAL SIGNS

Jack Osterloh Hx of wt loss that has stabilized. Hx of CRF, Hypercalcemia with panel MSU indicated secondary renal hyperparathyroidism. Hematuria on UA.
Abnormal PE/Chem/CBC/UA Results: creat 1.9 USG 1.040 ca 10.4 now -

SPECIES ULTRASONOGRAPHIC EXAMINATION OF THE ABDOMEN

Feline

Urinary System

Urinary bladder is moderately distended. It has a normal uniform wall thickness (<0.2 cm). Contents include primarily anechoic fluid combined with suspended echogenic non-shadowing debris within the fluid. No masses or cystoliths are observed. The trigone and visible pelvic urethra are normal in thickness with a smooth mucosal surface.

BREED

DSH

SEX

Neutered Male

The kidneys are bilaterally normal in size, irregular in shape, and diffusely echogenic with decreased corticomedullary distinction and poor visualization of internal architecture. The left kidney has hyperechoic wedge-shaped cortical indentations consistent with chronic infarcts. There is no pyelectasia noted and no mineral is observed. The left kidney measures 3.7 cm. The right kidney measures 3.6 cm.

AGE

12 Years

Adrenal Glands

Right adrenal gland is normal in size (0.7 cm long x 0.3 cm thick) shape and contour. Corticomedullary structure is unremarkable. Visible surrounding vasculature appears normal.

Left adrenal gland is normal in size (0.8 cm long x 0.4 cm thick) shape and contour. Corticomedullary structure is unremarkable. Visible surrounding vasculature appears normal.

WEIGHT

9.1 Pounds

Spleen

Spleen is subjectively normal in size with a normal smooth capsular contour. Parenchyma is appropriately finely textured and homogenous with normal echogenicity relative to surrounding tissue (hyperechoic to liver). No focal nodules or masses are observed. Splenic vasculature appears normal.

INTERPRETED BY

Beth Johnson, DVM
DACVIM

Liver

Liver is subjectively normal in size with normal smooth curvilinear peripheral contour. Parenchyma is appropriately hypoechoic to the spleen in echogenicity and appropriately mildly coarse and homogenous in echotexture. No focal lesions are observed. Visible vasculature and biliary tree appear normal without distension or congestion.

HOSPITAL NAME

Rondout Valley Vet
Associates

Gallbladder is non-distended in size. The wall is smooth without visible thickening. Luminal contents are primarily anechoic. There is no evidence of cystic or common bile duct dilation.

REFERRING VET

Dr. Prescott

Gastrointestinal

The stomach wall is normal in thickness (canine < 0.5 cm and feline < 0.4 cm) and layering. The lumen of the stomach is empty with no evidence of obstruction, foreign material or infiltrative disease. Pyloric outflow tract appears patent.

INVOICE NUMBER

33420

The visible small intestines are normal in wall thickness and layering (canine duodenum < 0.5 cm and feline duodenum < 0.4 cm; other < 0.3 cm). Small intestinal motility appears adequate (1-3

DATE

12/14/21



PATIENT (contractions per min). The lumen of the small intestine is empty with no evidence of obstruction, foreign material or infiltrative disease.

Jack Osterloh

The visible colon is normal in wall thickness (< 0.2 cm) and layering. Contents are consistent with normal formed feces and gas.

SPECIES

Pancreas

Feline

Pancreatic parenchyma is appropriately isoechoic to surrounding tissue. Visible capsule is smooth and normal in contour. There is no visible pancreatic duct dilation. There is no evidence of active peripancreatic inflammation.

BREED

Free Abdomen

DSH

There is no evidence of peritoneal effusion. There is no apparent lymphadenopathy.

Other

SEX

Neutered Male

In the mid to caudal abdomen, there is a 2.0 cm around, walled off, fluid filled structure of undifferentiated tissue origin. Association with a kidney and/or the urinary bladder cannot be definitively ruled out.

ULTRASONOGRAPHIC FINDINGS

AGE

12 Years

- Urinary bladder sediment - Urine changes are most consistent with incidental suspended lipid in a cat, however, cellular debris or crystalluria cannot be ruled out and should be interpreted in combination with urinalysis results.

WEIGHT

9.1 Pounds

- Chronic kidney disease such as chronic glomerular or interstitial nephritis, chronic pyelonephritis, etc., with chronic infarcts noted in the left kidney.
- Fluid-filled structure in the mid to caudal abdomen – Differentials include a cyst potentially associated with the left kidney, but this association is unable to be clearly identified in these images. Potentially associated with the urinary system such as a ureter or even the urinary bladder, although similarly this association is not able to be identified. Finally a cystic lymph node or other unrelated fluid-filled cystic mass/structure are also differentials.

INTERPRETED BY

Beth Johnson, DVM
DACVIM

INTERPRETATION OF THE FINDINGS & FURTHER RECOMMENDATIONS

HOSPITAL NAME

Rondout Valley Vet
Associates

If not already evaluated, a urine culture is recommended to rule out an occult urinary tract infection as well as a urine protein/creatinine ratio if there is protein present in the urine and the culture is negative. Blood pressure is recommended given the reported chronic kidney disease and the appearance of the kidneys on ultrasound. I agree the appearance of the kidneys fits with chronic kidney disease in this patient. However, a specific gravity of 1.040 and the very mildly increased creatinine are not consistent with chronic kidney disease, which therefore makes renal secondary hyperparathyroidism less convincing as a differential for the hypercalcemia, although possible.

REFERRING VET

Dr. Prescott

Other differentials for the hypercalcemia include potentially transient hypercalcemia possibly associated with mild dehydration, idiopathic hypercalcemia, hypercalcemia of malignancy, etc. Recommendations include consultation with the endocrinologist from the Michigan lab who evaluated the lab work followed by management of the chronic kidney disease, including fully assessing and managing possible dehydration and then monitoring the hypercalcemia for improvement/progression. If the hypercalcemia persists and another cause is not determined, a trial

INVOICE NUMBER

33420

DATE

12/14/21



PATIENT

course of Calcitriol could be considered with very close management/monitoring of Phosphorus and Calcium during the treatment course, and only to be tried if Phosphorus is currently normal.

Jack Osterloh

SPECIES

Additional imaging of the abdomen with an abdominal CT scan may offer more information about the fluid-filled structure in the caudal abdomen, especially to determine whether or not it is associated with the urinary tract. Other options are to perform a fine needle aspirate of that structure for cytology and culture if patient's coagulation status is appropriate.

Feline

BREED

As a note, infiltrative disease such as lymphoma causing the hyperechoic nature of the kidneys is possible, but typically is combined with enlarged kidneys, which is not the case in this patient, making renal lymphoma much lower on the list of differentials.

DSH

SEX

Neutered Male

AGE

12 Years

WEIGHT

9.1 Pounds

INTERPRETED BY

Beth Johnson, DVM
DACVIM

HOSPITAL NAME

Rondout Valley Vet
Associates

REFERRING VET

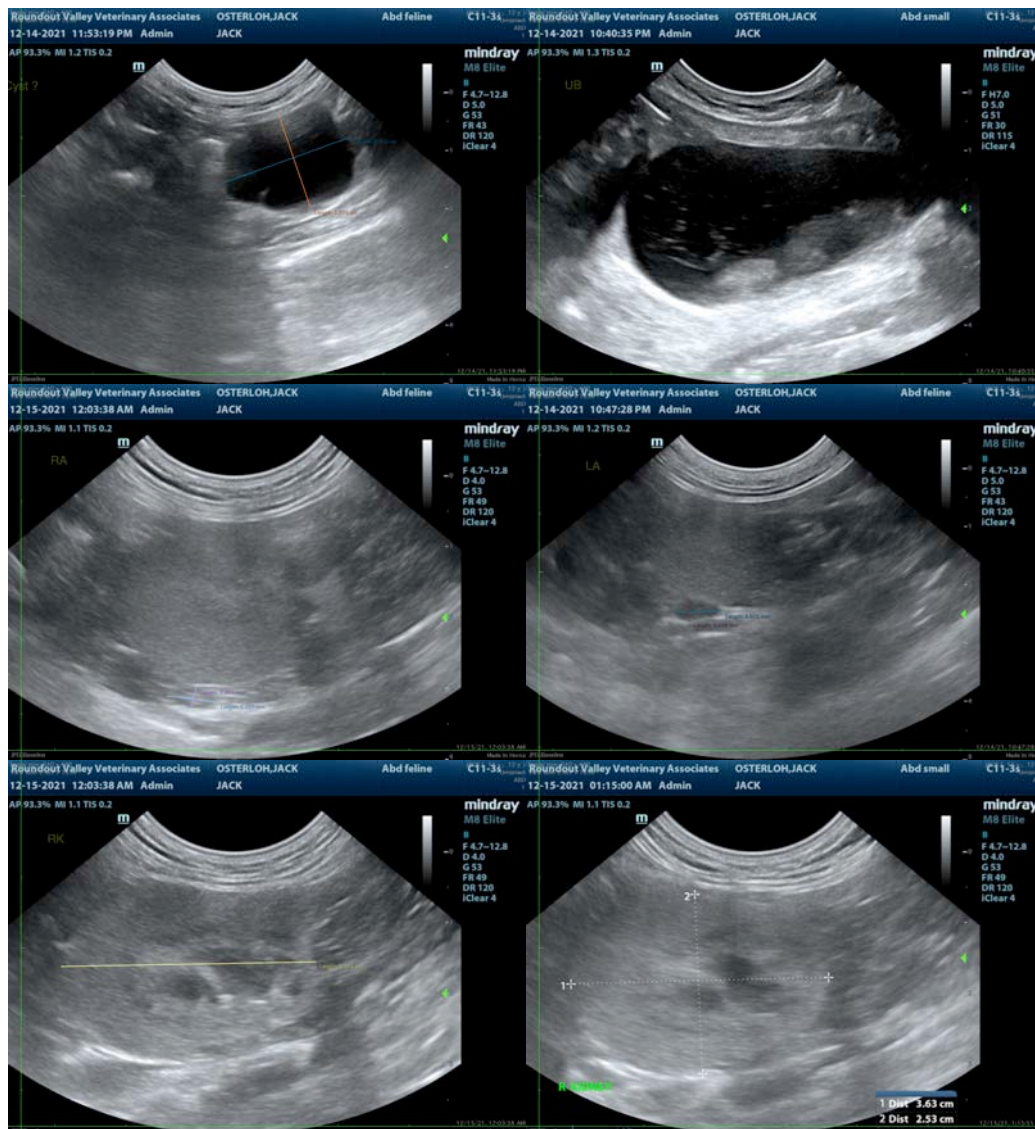
Dr. Prescott

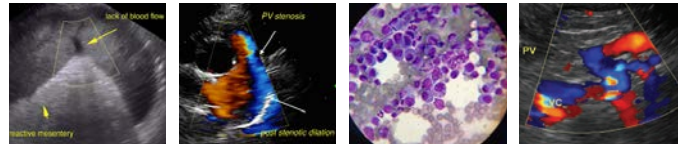
INVOICE NUMBER

33420

DATE

12/14/21





PATIENT

Jack Osterloh

SPECIES

Feline

BREED

DSH

SEX

Neutered Male

AGE

12 Years

WEIGHT

9.1 Pounds

INTERPRETED BY

Beth Johnson, DVM
DACVIM

HOSPITAL NAME

Rondout Valley Vet
Associates

REFERRING VET

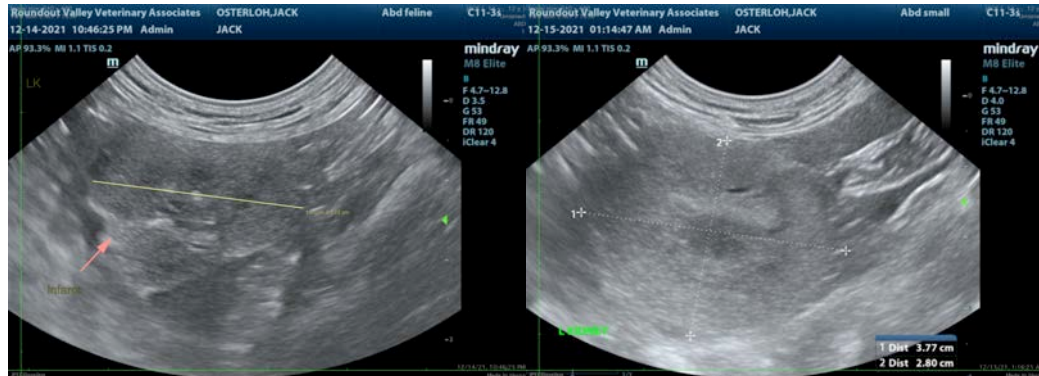
Dr. Prescott

INVOICE NUMBER

33420

DATE

12/14/21



The information and recommendations provided are based on the images presented by the referring veterinarian. No evaluation can be communicated regarding pathology that was not visible in the image/video clips provided.

Thank you for this referral. If the clinical or image interpretation does not parallel your findings or if I can be of any further assistance please contact me.

Beth Johnson, DVM, DACVIM
Beth.Johnson@sonopath.com