



PATIENT	PRESENTING CLINICAL SIGNS
Cooper Tarrant	Persistent hyperglobulinemia is what is being worked up. Also has history of previous FB surgery. Clinical signs are vomiting.
SPECIES	ULTRASONOGRAPHIC EXAMINATION OF THE ABDOMEN
Canine	Urinary System
BREED	Urinary bladder is moderately distended with normal uniform wall thickness. Contents include primarily anechoic fluid combined with gravity dependent, echogenic, non-shadowing debris within the trigone. No masses or cystoliths were observed, and the visible pelvic urethra is normal in thickness with a smooth mucosal surface. The dependent debris cannot be definitively ruled out, as tissue and color flow doppler would be helpful in determining debris versus tissue.
Golden Retriever	
SEX	The prostate is mildly enlarged for a dog that is neutered if he was neutered as a puppy. Parenchyma is diffusely homogeneous with normal echotexture and echogenicity. Normal distinct margins are present, and normal bilobed symmetry is maintained. If this dog was neutered later in life, this is a normal prostate for a recently neutered dog. If he was neutered as a puppy, it is considered subjectively enlarged.
Neutered Male	
AGE	Right kidney is normal in size (6.0 cm), shape and echogenicity. It has smooth peripheral margination. There is a normal 1:3 cortex to medulla ratio with appropriate corticomedullary distinction. There is no evidence of pyelectasia, mineral or infarcts observed.
8 Years	
WEIGHT	Left kidney is normal in size (5.3 cm), shape and echogenicity. It has smooth peripheral margination. There is a normal 1:3 cortex to medulla ratio with appropriate corticomedullary distinction. There is no evidence of pyelectasia, mineral or infarcts observed.
68.6 Pounds	
INTERPRETED BY	Adrenal Glands
Beth Johnson, DVM DACVIM	Right adrenal gland is normal in size (1.6 cm long, 0.6 cm at cranial pole and 0.47 cm at caudal pole), shape and contour. Corticomedullary structure is unremarkable. Visible surrounding vasculature appears normal.
IMAGING PERFORMED BY	Left adrenal gland is normal in size (2.4 cm long, 0.5 cm at cranial pole and 0.5 cm at caudal pole), shape and contour. Corticomedullary structure is unremarkable. Visible surrounding vasculature appears normal.
Dr. Adrienne Waffle	
HOSPITAL NAME	Spleen
Torch Lake VC	Spleen is subjectively normal in size with a normal smooth capsular contour. Parenchyma is appropriately finely textured and homogenous with normal echogenicity relative to surrounding tissue (hyperechoic to liver). No focal nodules or masses are observed. Splenic vasculature appears normal.
REFERRING VET	Liver
Dr. Adrienne Waffle	Liver is subjectively normal in size with normal smooth curvilinear peripheral contour. Parenchyma is appropriately hypoechoic to the spleen in echogenicity and appropriately mildly coarse and homogenous in echotexture. No focal lesions are observed. Visible vasculature and biliary tree appear normal without distension or congestion.
INVOICE	The gallbladder is moderately distended with anechoic bile and gravity dependent echogenic sediment. The wall is smooth without visible thickening. There is no evidence of cystic or CBD dilation. There is no evidence of effusion or inflammation.
33409	
DATE	
12/14/21	



PATIENT

Gastrointestinal

Cooper Tarrant

The stomach wall is normal in thickness (canine < 0.5 cm and feline < 0.4 cm) and layering. The lumen of the stomach is mildly distended with echogenic non-shadowing luminal contents and gas consistent with normal ingesta. There is no evidence of obstruction, foreign material or infiltrative disease. Pyloric outflow tract appears patent.

SPECIES

Canine

The visible small intestines are normal in wall thickness and layering (canine duodenum < 0.5 cm and feline duodenum < 0.4 cm; other < 0.3 cm). Small intestinal motility appears adequate (1-3 contractions per min). The lumen of the small intestine is diffusely mildly distended with echogenic, granular ingesta/chyme, and there is one proximal bowel loop that has a round, echogenic structure, suspected to be normal ingesta. However, foreign material cannot be ruled out. No obvious obstructive pattern is present.

BREED

Golden Retriever

SEX

Neutered Male

The visible colon is normal in wall thickness (< 0.2 cm) and layering. Contents are consistent with normal formed feces and gas.

Pancreas

AGE

8 Years

Pancreatic parenchyma is appropriately isoechoic to surrounding tissue. Visible capsule is smooth and normal in contour. There is no visible pancreatic duct dilation. There is no evidence of active peripancreatic inflammation.

Free Abdomen

WEIGHT

68.6 Pounds

There is no evidence of peritoneal effusion. There is no apparent lymphadenopathy.

ULTRASONOGRAPHIC FINDINGS

INTERPRETED BY

Beth Johnson, DVM
DACVIM

- Urinary bladder sediment/tissue in the trigone – most consistent with cellular debris or crystalluria. However, tissue cannot be ruled out.
- Gallbladder debris - Cholecystic debris is of unknown clinical significance. It can be seen with biliary stasis from fasting or illness. Cholecystic debris is not necessarily related to hepatobiliary disease. Echogenic bile is most commonly an incidental finding in dogs and should be interpreted in combination with clinical signs such as nausea, inappetence, cranial abdominal discomfort and/or laboratory changes such as increased ALP and/or increased Tbili.
- Subjectively enlarged, but benign appear prostate for a neutered dog
- The GI tract appears to be a normal post-prandial GI tract. However, foreign material cannot be ruled out. No obstructive pattern is present. However, an early or partial obstruction cannot be ruled out.

IMAGING PERFORMED BY

Dr. Adrienne Waffle

HOSPITAL NAME

Torch Lake VC

REFERRING VET

Dr. Adrienne Waffle

INTERPRETATION OF THE FINDINGS & FURTHER RECOMMENDATIONS

Given the urinary bladder changes, recommendations include urinalysis and urine culture as well as color flow doppler analysis of the trigone to determine if there is any color flow in the echogenic structure that resides there. If the structure is persistent and has color flow, then submission of urine to look for a BRAF gene mutation (which is associated with urinary bladder cancer) is recommended, especially given the concurrent mild prostatomegaly. Neoplasia is considered unlikely, but possible, and these diagnostics would definitively rule it out.

INVOICE

33409

DATE

12/14/21

Other recommendations include fully fasting this patient and then rechecking the GI tract with ultrasound and/or radiographs to further evaluate for possible foreign body, especially if the vomiting is



PATIENT

Cooper Tarrant

persistent. Regarding the persistent hyperglobulinemia, recommendations include SAM electrophoresis to determine whether the globulins are monoclonal or polyclonal, followed by potentially infectious disease testing if indicated. If not already performed, close evaluation of peripheral lymph nodes is also recommended given the hypoglobulinemia to rule out lymphoma. There is no evidence of intraabdominal lymphadenopathy.

SPECIES

Canine

BREED

Golden Retriever

SEX

Neutered Male

AGE

8 Years

WEIGHT

68.6 Pounds

INTERPRETED BY

Beth Johnson, DVM
DACVIM

IMAGING PERFORMED BY

Dr. Adrienne Waffle

HOSPITAL NAME

Torch Lake VC

REFERRING VET

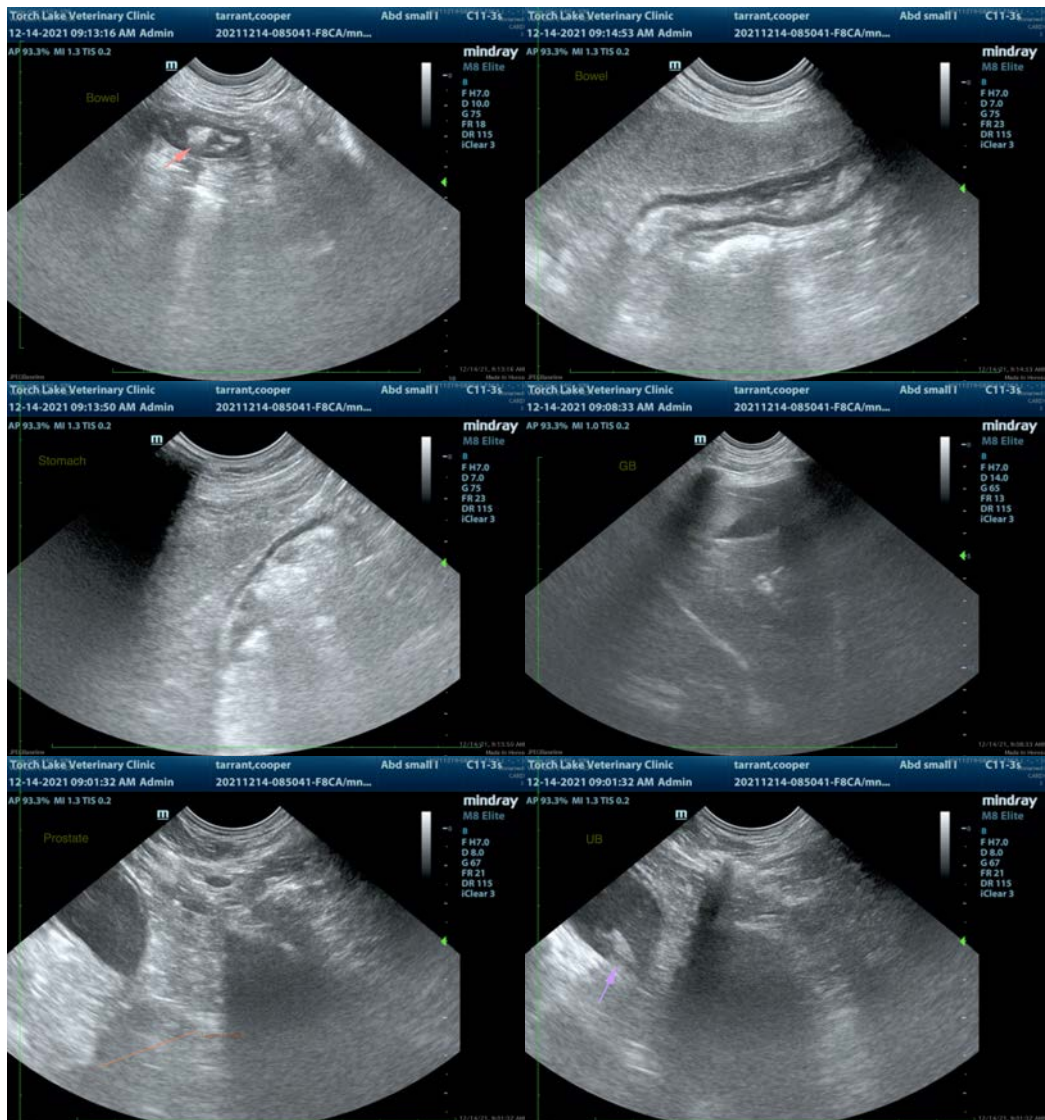
Dr. Adrienne Waffle

INVOICE

33409

DATE

12/14/21





PATIENT

Cooper Tarrant

SPECIES

Canine

BREED

Golden Retriever

SEX

Neutered Male

AGE

8 Years

WEIGHT

68.6 Pounds

INTERPRETED BY

Beth Johnson, DVM
DACVIM

IMAGING PERFORMED BY

Dr. Adrienne Waffle

HOSPITAL NAME

Torch Lake VC

REFERRING VET

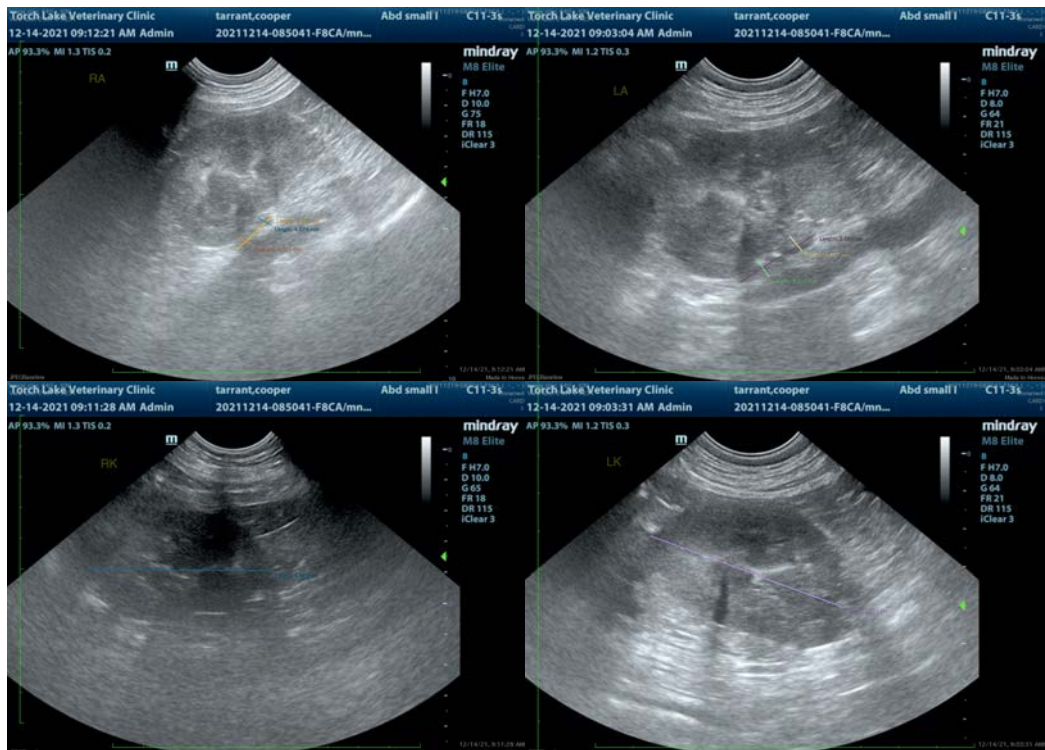
Dr. Adrienne Waffle

INVOICE

33409

DATE

12/14/21



The information and recommendations provided are based on the images presented by the referring veterinarian. No evaluation can be communicated regarding pathology that was not visible in the image/video clips provided.

Thank you for this referral. If the clinical or image interpretation does not parallel your findings or if I can be of any further assistance please contact me.

Beth Johnson, DVM, DACVIM
Beth.Johnson@sonopath.com