



PATIENT	PRESENTING CLINICAL SIGNS
Derby Stenkamp	Polyphagia and Weight loss for 6 months. Normal Drinking, urination, and defecation. Eating 4 small cans of food a day and crying for more.
SPECIES	Abnormal PE/Chem/CBC/UA Results: PE: BCS 2/5, coat is dull, hair loss around face (is a long term self mutilator and wears soft paws constantly). Stage II Dental Disease. UA: pH 5.0, SG 1.024, clear sediment CBC: N Chem: Glucose 64 mg/dL (runs about hear the last 2 years), Total Protein 8.9 g/dL, ALT 616 U/L, AST 225 U/L, ALP 244 U/L, Total Bili 1.1 mg/dL, Unconj 0.7 mg/dL, Conj 0.4 mg/dL, Cholesterol 439 mg/dL fPL, BNP, Total T4, Free T4: all normal. No Fecal
Feline	
BREED	ULTRASONOGRAPHIC EXAMINATION OF THE ABDOMEN
DMH	
SEX	Urinary System
Neutered Male	The urinary bladder is moderately distended with anechoic contents. No masses, inflammatory changes, echogenic sediment or cystoliths are observed. The urinary bladder, trigone and visible pelvic urethra are normal in thickness with a smooth mucosal surface.
AGE	The right kidney is normal in size (3.58 cm), shape and echogenicity. It has smooth peripheral margination. There is a normal 1:3 cortex to medulla ratio with appropriate corticomedullary distinction. There is no evidence of pyelectasia, mineral or infarcts observed.
12 Years 1 Month	
WEIGHT	The left kidney is normal in size (3.24 cm), shape and echogenicity. It has smooth peripheral margination. There is a normal 1:3 cortex to medulla ratio with appropriate corticomedullary distinction. There is no evidence of pyelectasia, mineral or infarcts observed.
7.3 Pounds	
INTERPRETED BY	Adrenal Glands
Beth Johnson, DVM DACVIM	The right adrenal gland is normal in size (0.30 cm), shape and contour. Corticomedullary structure is unremarkable. Visible surrounding vasculature appears normal.
IMAGING PERFORMED BY	The left adrenal gland is normal in size (0.26 cm), shape and contour. Corticomedullary structure is unremarkable. Visible surrounding vasculature appears normal.
Kaitlyn McDaniel	Spleen
HOSPITAL NAME	The spleen is subjectively normal in size with a normal smooth capsular contour. Parenchyma is appropriately finely textured and homogenous with normal echogenicity relative to surrounding tissue (hyperechoic to liver). No focal nodules or masses are observed. Splenic vasculature appears normal.
Elizabeth AH	Liver
REFERRING VET	Liver is subjectively enlarged (swollen contour) without disruption of architecture. It has a normal homogenous echotexture. Parenchyma is diffusely hyperechoic characterized by less prominent than normal portal vein walls and increased echogenicity relative to the spleen and falciform fat. No focal lesions are observed. Visible vasculature and biliary tree appear normal without distension or congestion.
Dr. Leon Anderson	INVOICE
INVOICE	The gallbladder is non-distended in size. The wall is smooth without visible thickening. Luminal contents are primarily anechoic. There is no evidence of cystic or common bile duct dilation.
43417	Gastrointestinal
DATE	The stomach wall is normal in thickness (canine < 0.5 cm and feline < 0.4 cm) and layering. The lumen of the stomach is empty with no evidence of obstruction, foreign material or infiltrative disease. Pyloric outflow tract appears patent.
12/13/22	



PATIENT

Derby Stenkamp

The visible small intestines are normal in wall thickness and layering (canine duodenum < 0.5 cm and feline duodenum < 0.4 cm; other < 0.3 cm). Small intestinal motility appears adequate (1-3 contractions per min). The lumen of the small intestine is empty with no evidence of obstruction, foreign material or infiltrative disease.

SPECIES

Feline

The visible colon is normal in wall thickness (< 0.2 cm) and layering. Contents are consistent with normal formed feces and gas.

Pancreas

BREED

DMH

The pancreatic parenchyma is appropriately isoechoic to surrounding tissue. Visible capsule is smooth and normal in contour. There is no visible pancreatic duct dilation. There is no evidence of active peripancreatic inflammation.

SEX

Neutered Male

Free Abdomen

There is no evidence of free peritoneal effusion noted in these images.

There is no apparent lymphadenopathy noted in these images.

AGE

12 Years 1 Month

ULTRASONOGRAPHIC FINDINGS

WEIGHT

7.3 Pounds

- **Hyperechoic hepatomegaly** – This appearance is most consistent with benign hepatic lipidosis. Infiltrative disease such as amyloidosis or round cell neoplasia, such as mast cell tumor or less likely, lymphoma, is also possible.
- There is no ultrasonographically obvious visible cause for this patient's reported polyphagia with weight loss and/or the chronic hypoglycemia.

INTERPRETED BY

Beth Johnson, DVM
DACVIM

INTERPRETATION OF THE FINDINGS & FURTHER RECOMMENDATIONS

Recommendations are to look for maldigestive or malabsorptive condition, including exocrine pancreatic insufficiency. Therefore, a gastrointestinal malabsorption panel (including cobalamin, folate, TLI and PLI) to Texas A&M GI Laboratory is recommended for further evaluation of GI and pancreatic function.

IMAGING PERFORMED BY

Kaitlyn McDaniel

Given the chronic hypoglycemia, if possible, a paired insulin to glucose ratio is recommended at a time when the glucose is <50 if that occurs.

HOSPITAL NAME

Elizabeth AH

Again, while rare and not typically associated with polyphagia, hypoadrenocorticism is another differential for hypoglycemia, and could be further investigated in the form of an ACTH stimulation test.

REFERRING VET

Dr. Leon Anderson

Finally, a fine needle aspirate of the liver could be considered if patient's coagulation status is appropriate. Ultimately, if clinical signs persist and an underlying cause cannot be obtained, biopsies of the gastrointestinal tract, especially if the malabsorption panel results support gastrointestinal disease, may be necessary to definitively diagnose and therefore manage this patient's underlying condition.

In the meantime, recommendations are to offer this patient the amount of calories necessary to maintain weight while trying to obtain a diagnosis.

INVOICE

43417

DATE

12/13/22



PATIENT

Derby Stenkamp

SPECIES

Feline

BREED

DMH

SEX

Neutered Male

AGE

12 Years 1 Month

WEIGHT

7.3 Pounds

INTERPRETED BY

Beth Johnson, DVM
DACVIM

IMAGING PERFORMED BY

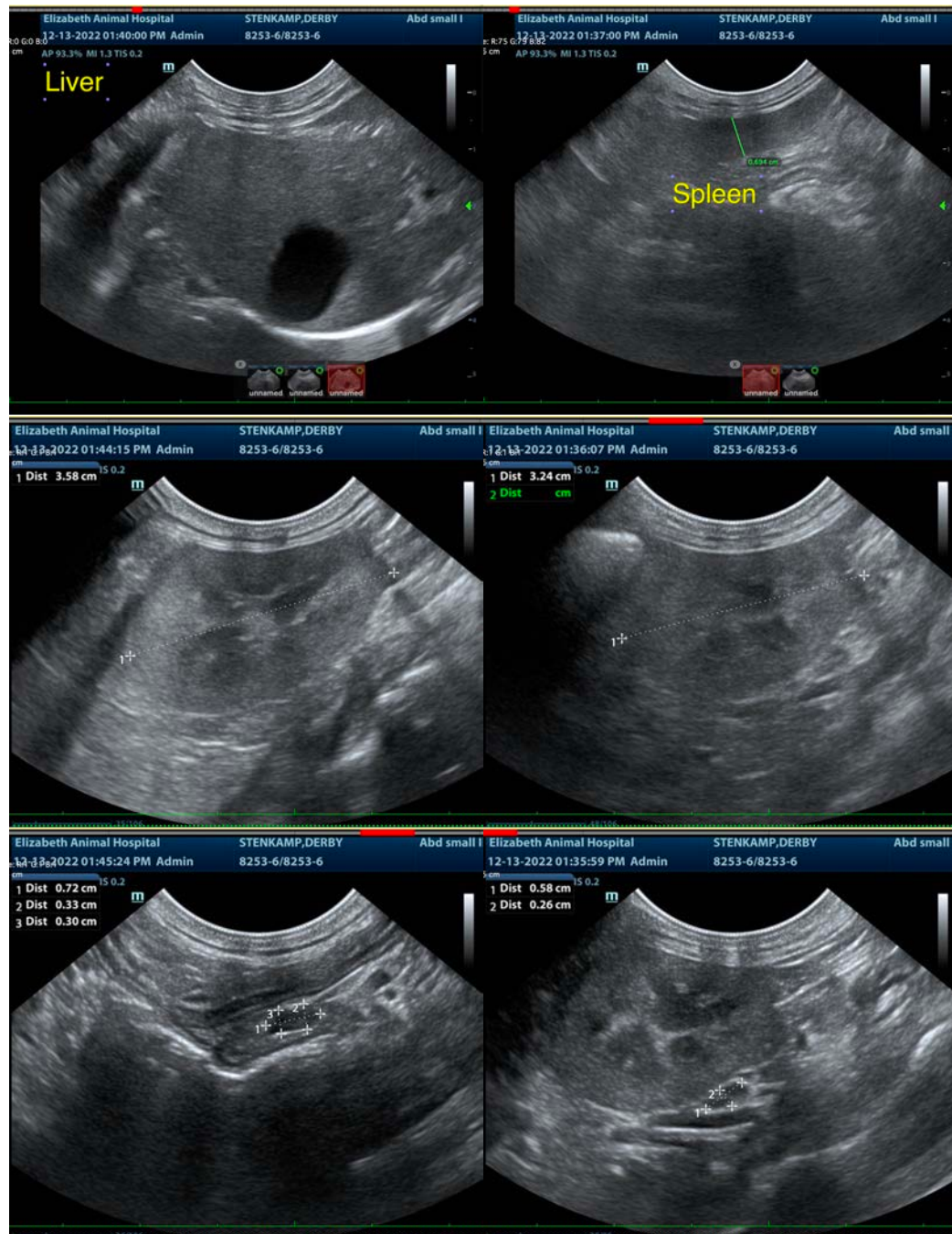
Kaitlyn McDaniel

HOSPITAL NAME

Elizabeth AH

REFERRING VET

Dr. Leon Anderson



The information and recommendations provided are based on the images presented by the referring veterinarian/sonographer. No evaluation can be communicated regarding pathology that was not visible in the image/video clips provided.

INVOICE

43417

Thank you for this referral. If the clinical or image interpretation does not parallel your findings or if I can be of any further assistance please contact me.

DATE

12/13/22

Beth Johnson, DVM, DACVIM
Beth.Johnson@sonopath.com