



**DATE PRESENTING CLINICAL SIGNS**

12/11/25 **Patient History:** Not eating.

**PATIENT Current Medications:** N/A.

Winter Mielczasz **Labwork Results:** Diagnostics not attached, Xray showed possible large spleen. BW submitting- waiting on results.

**Date of Previous IntraPet Ultrasound:** No previous.

**Sedation:** Telazol/Torbugesic.

**SPECIES Stat Report:** Not requested.

Canine **Imaging Performed by:** Stephanie Warga RDCS, RVT .

**ULTRASONOGRAPHIC EXAMINATION OF THE ABDOMEN**

**BREED**

German Shepherd

**Urinary System**

**SEX**

Spayed Female

Urinary bladder is adequately distended. It has a normal uniform wall thickness. Contents include primarily anechoic fluid with a moderate amount of echogenic non-shadowing debris, most consistent with exfoliated cells, mucous and/or small blood clots. Both sterile inflammation as well as urinary tract infection can present with echogenic debris. No masses or cystoliths are observed. The trigone and visible pelvic urethra are normal in thickness with a smooth mucosal surface.

**AGE**

9/27/14

The right kidney is normal is size (7.46 cm), shape and echogenicity. It has smooth peripheral margination. There is a normal 1:3 cortex to medulla ratio with appropriate corticomedullary distinction. There is no evidence of pyelectasia, mineral or infarcts observed.

**WEIGHT**

84 lbs

The left kidney is normal is size (7.67 cm), shape and echogenicity. It has smooth peripheral margination. There is a normal 1:3 cortex to medulla ratio with appropriate corticomedullary distinction. There is no evidence of pyelectasia, mineral or infarcts observed.

**INTERPRETED BY**

Beth Johnson, DVM  
DACVIM

**Adrenal Glands**

**HOSPITAL NAME**

Honeygo Animal  
Hospital

Adrenal glands are plump/swollen in size. Normal shape and contour are maintained without evidence of capsular invasion. Corticomedullary structure is unremarkable. The enlargement is characterized by hyperechoic nodules noted in left cranial, left caudal, and right cranial poles. Nodules do not disrupt normal shape and/or architecture. Visible surrounding vasculature appears normal. Left measures 1.0 cm at the cranial pole and 1.3 cm at the caudal pole. Right measures 1.0 cm at the cranial pole and 0.93 cm at the caudal pole.

**REFERRING VET**

Dr. Weight

**Spleen**

**INVOICE**

72521

Spleen is subjectively normal in size with a normal smooth capsular contour. Parenchyma is appropriately finely textured and homogenous with normal echogenicity relative to surrounding tissue (hyperechoic to liver). Multifocal well-demarcated hyperechoic homogenous nodules are noted. The most sizable, discrete nodule is along the cranial aspect of the spleen, non-capsule disrupting, and measures 2.0 cm x 2.3 cm in size. Splenic vasculature appears normal.

## ***Liver***

The liver is subjectively normal in size with normal smooth curvilinear peripheral contour. Parenchyma is appropriately hypoechoic to the spleen in echogenicity and appropriately mildly coarse and homogenous in echotexture. No focal lesions are observed. Visible vasculature and biliary tree appear normal without distension or congestion.

Gallbladder is moderately distended with anechoic bile as well as suspended and gravity dependent echogenic debris. The wall is smooth without visible thickening. There is no evidence of cystic or CBD dilation. There is no evidence of effusion or inflammation.

## ***Gastrointestinal***

The visible stomach wall is normal in thickness and layering. The lumen of the stomach is empty with no evidence of obstruction, foreign material or infiltrative disease. Pyloric outflow tract appears patent.

The visible small intestines are normal in wall thickness and layering. Small intestinal motility appears adequate (1-3 contractions per min). The lumen of the small intestine is empty with no evidence of obstruction, foreign material or infiltrative disease.

The visible colon is normal in wall thickness (< 0.2 cm) and layering. Contents are consistent with normal formed feces and gas.

## ***Pancreas***

The observed pancreas is prominent (enlarged) in size, hypoechoic to surrounding tissue and irregular in shape with a swollen undulating contour. This change is very mild/subtle and primarily noted just caudal to the stomach. Enhanced hyperechoic ill-defined surrounding fat is noted.

## ***Free Abdomen***

There is no visible free peritoneal effusion noted in these images.

There is no apparent pathologic lymphadenopathy noted in these images.

## **PRIMARY FINDINGS**

- Suspect mild or potentially emerging versus resolving acute pancreatitis based on the subtle changes described.

## **SECONDARY FINDINGS**

- Bilateral adrenomegaly – In a patient diagnosed with hyperadrenocorticism, this finding is most consistent with adrenal hyperplasia secondary to pituitary dependent hyperadrenocorticism. This finding can also be seen with stress and/or normal patient variant. Interpret in combination with clinical signs of hyperadrenocorticism and/or other adrenal disease.
- Bilateral hyperechoic adrenal nodules – Differentials include primary adrenal cortical adenoma or adenocarcinoma, pheochromocytoma, myelolipoma, adrenal hyperplasia secondary to pituitary disease or metastatic disease. Ultrasound alone cannot differentiate between functional and non-

functional nodules and/or between benign and malignant disease. Small nodules without other evidence of abdominal disease (to suggest metastatic disease) and/or clinical signs (to suggest adrenal disease) are most often incidental and should be monitored.

- Hyperechoic splenic nodule – most consistent with benign myelolipomas. Other differentials such as fibrosis or calcification caused by old hematomas or infarcts, chronic inflammation, granulomatous disease or metastatic disease cannot be ruled out, but are considered less likely.
- Mild gallbladder debris - Cholecystic debris is of unknown clinical significance. It can be seen with biliary stasis from fasting or illness. Cholecystic debris is not necessarily related to hepatobiliary disease. Echogenic bile is most commonly an incidental finding in dogs and should be interpreted in combination with clinical signs such as nausea, inappetence, cranial abdominal discomfort and/or laboratory changes such as increased ALP and/or increased Tbili.
- Moderate amount of echogenic urinary bladder debris.

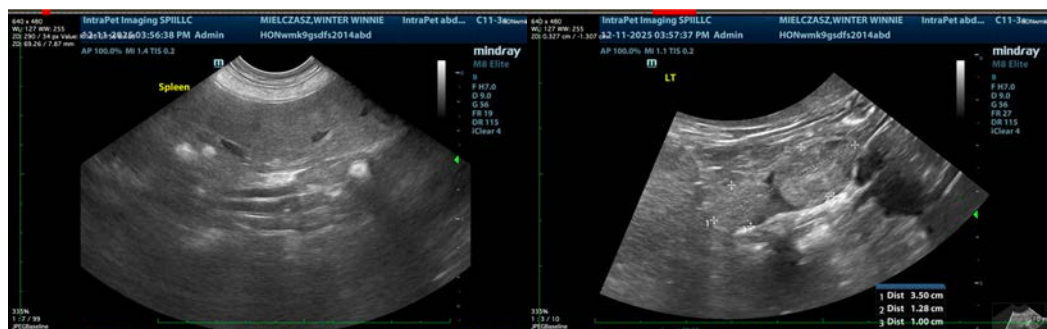### INTERPRETATION OF THE FINDINGS & FURTHER RECOMMENDATIONS

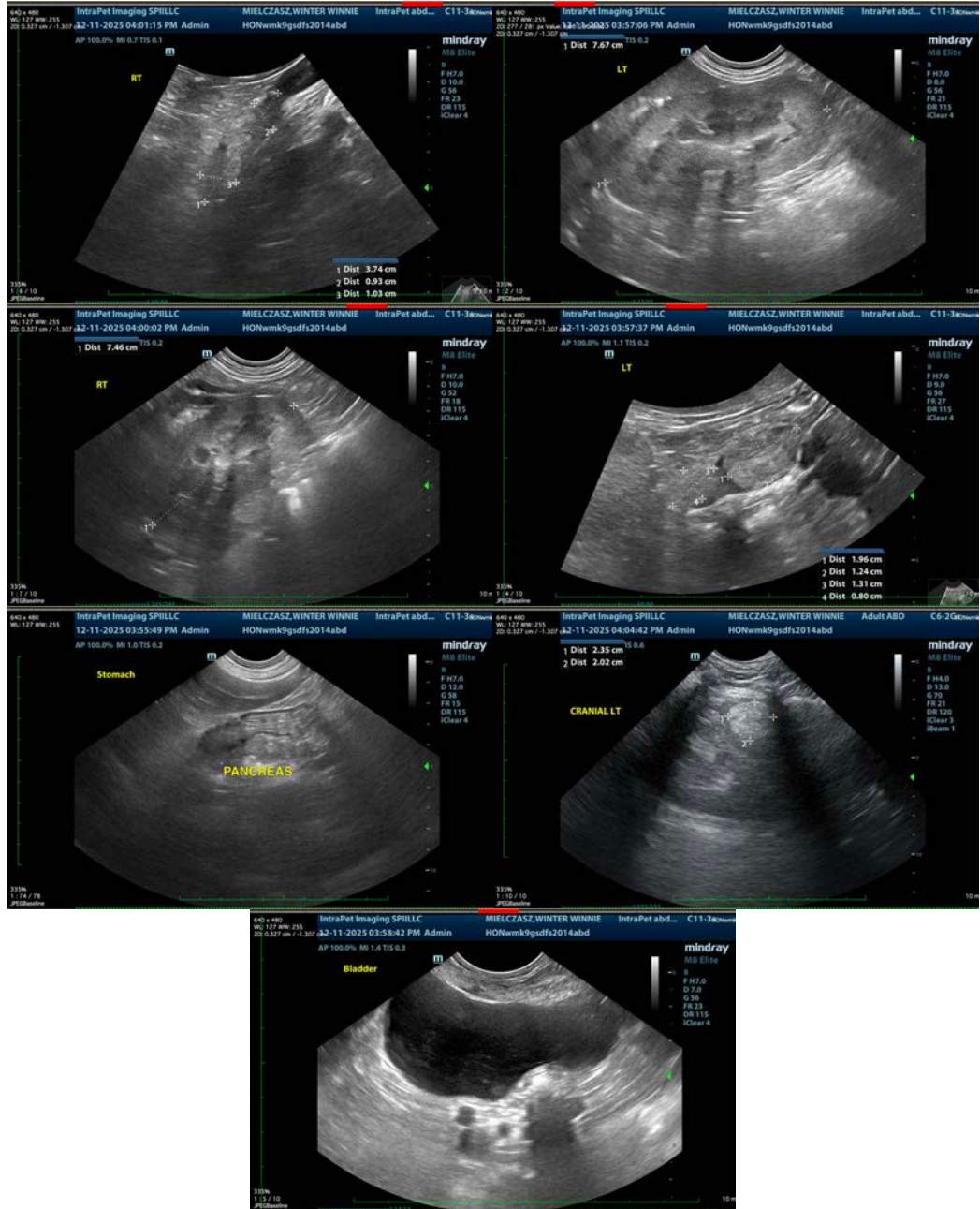
The most significant changes described, given the patient's clinical history, in my opinion, although they are mild/subtle, are the pancreatic changes. Therefore, as is reportedly already pending, a full general metabolic health screen is recommended to include CBC/Chem panel, electrolytes, and urinalysis.

A gastrointestinal malabsorption panel (including cobalamin, folate, TLI and PLI) to Texas A&M GI Laboratory is recommended for further evaluation of GI and pancreatic function.

Three view thoracic radiographs are recommended for further assessment of cardio-pulmonary status as well as to further evaluate for any evidence of metastatic disease, if not recently evaluated.

In the meantime, medical management of pancreatitis with anti-emetics, gastroprotectants, appetite stimulants or nutritional support as needed, pain management, broad spectrum antibiotics, and fluid therapy is recommended. Monitoring of the pancreas with power doppler is recommended to identify possible necrosis as well as other potential sequelae such as abscesses, etc.





**The information and recommendations provided are based on the images presented by the referring veterinarian/sonographer. No evaluation can be communicated regarding pathology that was not visible in the image/video clips provided.**

Thank you for this referral. If the clinical or image interpretation does not parallel your findings or if I can be of any further assistance please contact me.

**Beth Johnson, DVM, DACVIM**  
info@sonopath.com