

PATIENT

Teddy Treille

SPECIES

Canine

BREED

Labradoodle

SEX

Neutered Male

AGE

2

WEIGHT

60 lbs

INTERPRETED BY

Beth Johnson, DVM
DACVIM

IMAGING PERFORMED BY

Pamela Harrigan,
RDCS, Certified Vet
Sonographer

HOSPITAL NAME

Falmouth Animal
Hospital

REFERRING VET

Kendall Stratton, DVM

INVOICE

72464

DATE

12/10/25

PRESENTING CLINICAL SIGNS

10 month history of PU/PD and recent dx low SG at 1.016 on first AM urine as well as mildly elevated creat 1.6. cort/creat ratio was normal. Patient will also submissively urinate at home and at groomers.

LIMITED ULTRASONOGRAPHIC EXAMINATION

Urinary System

The urinary bladder is adequately distended with anechoic contents. No masses, inflammatory changes, echogenic sediment or cystoliths are observed. The urinary bladder, trigone and visible pelvic urethra are normal in thickness with a smooth mucosal surface.

Prostate is normal in size, echotexture and echogenicity for a neutered male.

The right kidney is normal is size (5.49 cm), shape and echogenicity. It has smooth peripheral margination. There is a normal 1:3 cortex to medulla ratio with appropriate corticomedullary distinction. There is no evidence of pyelectasia, mineral or infarcts observed. A hyperechoic band parallel to the corticomedullary border is present.

The left kidney is normal is size (6.56 cm), shape and echogenicity. It has smooth peripheral margination. There is a normal 1:3 cortex to medulla ratio with appropriate corticomedullary distinction. There is no evidence of pyelectasia, mineral or infarcts observed. A hyperechoic band parallel to the corticomedullary border is present.

Adrenal Glands

The right adrenal gland is normal in size (0.60 cm at cranial pole and 0.40 cm at caudal pole), shape and overall architecture, echogenicity and echotexture. Visible surrounding vasculature appears normal.

The left adrenal gland is normal in size (0.35 cm at cranial pole and 0.39 cm at caudal pole), shape and overall architecture, echogenicity and echotexture. Visible surrounding vasculature appears normal.

ULTRASONOGRAPHIC FINDINGS

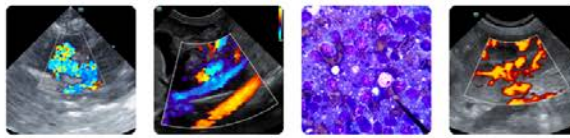
- Mild bilateral medullary rim sign - This finding is of unknown clinical significance and can be a normal variant, often idiopathic. Medullary rim sign can be present with renal disease including lymphoma, hypercalcemic nephropathy, Leptospirosis, tubular disease, other and should be interpreted in combination with other more specific indications of kidney disease such as isosthenuria, proteinuria, azotemia, etc. This is a common incidental finding in patients with diabetes mellitus.

INTERPRETATION OF THE FINDINGS & FURTHER RECOMMENDATIONS

Early or emerging chronic kidney disease can't be ruled out, especially given patient's reported history and laboratory changes. However, the changes noted are very mild and could be normal patient variant, and should therefore be interpreted in combination with full workup, etc.

Differentials for PU/PD are vast and include, but are not limited to:

Primary polyuria caused by chronic kidney disease, pyelonephritis, liver disease, diabetes mellitus, hyperthyroidism, hypercalcemia, hyperadrenocorticism, hypoadrenocorticism, E.coli infections ie) pyometra in females, polycythemia, central diabetes insipidus or primary nephrogenic diabetes insipidus.



PATIENT

Teddy Treille

SPECIES

Canine

BREED

Labradoodle

SEX

Neutered Male

AGE

2

WEIGHT

60 lbs

INTERPRETED BY

Beth Johnson, DVM
DACVIM

IMAGING PERFORMED BY

Pamela Harrigan,
RDCS, Certified Vet
Sonographer

HOSPITAL NAME

Falmouth Animal
Hospital

REFERRING VET

Kendall Stratton, DVM

INVOICE

72464

DATE

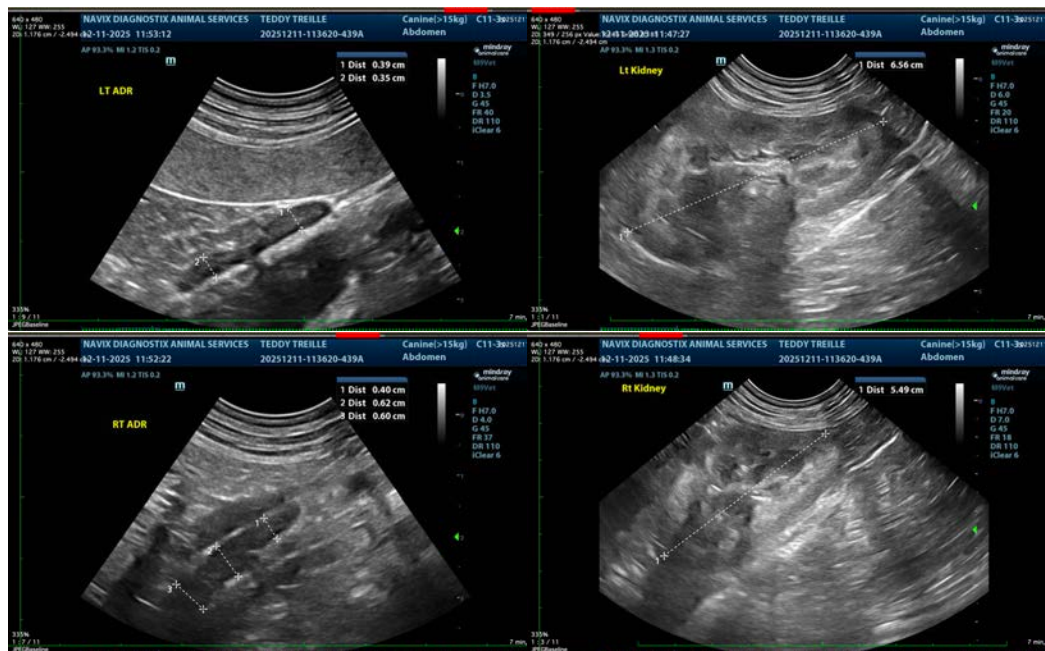
12/10/25

Primary polydipsia caused by psychogenic polydipsia, fever, pain, or central nervous system disease.

Most causes of PU/PD can be diagnosed with a comprehensive history and physical exam, a first AM urine specific gravity to see if urine concentration is possible (as most animals naturally consume less water overnight) followed by a comprehensive CBC, serum chemistry panel, electrolytes, and urinalysis.

If not, next step(s) may include a urine culture, low dose dexamethasone suppression test, T4, bile acids, Leptospirosis testing and/or an empirical course of antibiotics.

If a diagnosis is still not obtained, a more advanced work-up is indicated and consultation with an internist may be warranted.



The information and recommendations provided are based on the images presented by the referring veterinarian/sonographer. No evaluation can be communicated regarding pathology that was not visible in the image/video clips provided.

Thank you for this referral. If the clinical or image interpretation does not parallel your findings or if I can be of any further assistance please contact me.

Beth Johnson, DVM, DACVIM
info@sonopath.com