



PATIENT

Kage Howard

SPECIES

Canine

BREED

Pit Bull x

SEX

Neutered Male

AGE

8 Years

WEIGHT

64 lbs

INTERPRETED BY

Beth Johnson, DVM
DACVIM

IMAGING PERFORMED BY

Julia Bakker, DVM

HOSPITAL NAME

Orange Blossom
Veterinary Imaging

REFERRING VET

Arthur Newman, DVM

INVOICE

72478

DATE

12/10/25

PRESENTING CLINICAL SIGNS

TLI cobalamine/folic acid showed low folate put on folic acid, improved spoke w/ internal medicine, low folate indicated small intestinal issue, needs abd US.

ULTRASONOGRAPHIC EXAMINATION OF THE ABDOMEN

Urinary System

The urinary bladder is adequately distended with anechoic contents. No masses, inflammatory changes, echogenic sediment or cystoliths are observed. The urinary bladder, trigone and visible pelvic urethra are normal in thickness with a smooth mucosal surface.

The prostate is unable to be well visualized in these images.

The right kidney is normal is size (6.12 cm), shape and echogenicity. It has smooth peripheral margination. There is a normal 1:3 cortex to medulla ratio with appropriate corticomedullary distinction. There is no evidence of pyelectasia, mineral or infarcts observed. A hyperechoic band parallel to the corticomedullary border is present.

The left kidney is normal is size (6.39 cm), shape and echogenicity. It has smooth peripheral margination. There is a normal 1:3 cortex to medulla ratio with appropriate corticomedullary distinction. There is no evidence of pyelectasia, mineral or infarcts observed. A hyperechoic band parallel to the corticomedullary border is present.

Adrenal Glands

The right adrenal gland is normal in size (0.50 cm at cranial pole and 0.40 cm at caudal pole), shape and overall architecture, echogenicity and echotexture. Visible surrounding vasculature appears normal.

The left adrenal gland is normal in size (0.50 cm at cranial pole and 0.40 cm at caudal pole), shape and overall architecture, echogenicity and echotexture. Visible surrounding vasculature appears normal.

Spleen

Spleen is subjectively large in size with a normal smooth capsular contour. Parenchyma is appropriately finely textured and homogenous with normal echogenicity relative to surrounding tissue (hyperechoic to liver). In the mid spleen is a very subtle 0.40 cm x 0.60 cm hypo- to anechoic non-capsule disrupting density. Splenic vasculature appears normal. The spleen is folded upon itself, which is a positional non-pathologic variant.

Liver

The liver is subjectively normal in size with normal smooth curvilinear peripheral contour. Parenchyma is appropriately hypoechoic to the spleen in echogenicity and appropriately mildly coarse and homogenous in echotexture. No focal lesions are observed. Visible vasculature and biliary tree appear normal without distension or congestion.

The gallbladder is non-distended in size. The wall is smooth without visible thickening. Luminal contents are primarily anechoic. There is no evidence of cystic or common bile duct dilation.



PATIENT

Kage Howard

SPECIES

Canine

BREED

Pit Bull x

SEX

Neutered Male

AGE

8 Years

WEIGHT

64 lbs

INTERPRETED BY

Beth Johnson, DVM
DACVIM

IMAGING PERFORMED BY

Julia Bakker, DVM

HOSPITAL NAME

Orange Blossom
Veterinary Imaging

REFERRING VET

Arthur Newman, DVM

INVOICE

72478

DATE

12/10/25

Gastrointestinal

The visible stomach wall is normal in thickness and layering. The lumen of the stomach is mildly distended with a small to moderate amount of echogenic non-shadowing luminal contents and gas consistent with normal ingesta. There is no evidence of obstruction, foreign material or infiltrative disease. Pyloric outflow tract appears patent.

The visible small intestines are normal in wall thickness and layering. Hyperechoic mucosal fogging or speckling is noted. Small intestinal motility appears adequate (1-3 contractions per min). The lumen is mildly distended with echogenic non-shadowing luminal contents and gas consistent with normal ingesta/chyme. There is no evidence of obstruction, foreign material or infiltrative disease.

The visible colon is normal in wall thickness (< 0.2 cm) and layering. Contents are consistent with normal formed feces and gas.

Pancreas

The pancreas that is observed appears appropriately isoechoic to surrounding omental fat. Visible capsule is smooth and normal in contour. Visible pancreatic parenchyma is homogenous and unremarkable. There is no visible pancreatic duct dilation. There is no evidence of active peripancreatic inflammation.

Free Abdomen

There is no visible free peritoneal effusion noted in these images.

There is no apparent pathologic lymphadenopathy noted in these images.

ULTRASONOGRAPHIC FINDINGS

- Subtle/mild mucosal speckling – Mucosal speckling is often present with inflammatory bowel disease (IBD). It is not specific for type or severity of disease. Mild speckling change can occur as a normal patient variant in the post-prandial state.
- Splenomegaly– can be associated with congestion caused by sedation (if sedated) but can also be associated with diffuse infiltrative disease. Both benign conditions such as extramedullary hematopoiesis, lymphoid hyperplasia, as well as infiltrative neoplastic diseases such as round cell neoplasia should be considered. The subtle hypoechoic to anechoic nodule likely represents a benign process such as a cyst or hematoma, extramedullary hematopoiesis, etc. with infiltrative neoplasia being possible but considered less likely.
- Bilateral medullary rim sign - This finding is of unknown clinical significance and can be a normal variant, often idiopathic. Medullary rim sign can be present with renal disease including lymphoma, hypercalcemic nephropathy, Leptospirosis, tubular disease, other and should be interpreted in combination with other more specific indications of kidney disease such as isosthenuria, proteinuria, azotemia, etc. This is a common incidental finding in patients with diabetes mellitus.

INTERPRETATION OF THE FINDINGS & FURTHER RECOMMENDATIONS

If not recently evaluated, a general metabolic health screen (CBC, chemistry panel with electrolytes and urinalysis) is recommended.



PATIENT

Kage Howard

SPECIES

Canine

BREED

Pit Bull x

SEX

Neutered Male

AGE

8 Years

WEIGHT

64 lbs

INTERPRETED BY

Beth Johnson, DVM
DACVIM

IMAGING PERFORMED BY

Julia Bakker, DVM

HOSPITAL NAME

Orange Blossom
Veterinary Imaging

REFERRING VET

Arthur Newman, DVM

INVOICE

72478

DATE

12/10/25

Subtle gastrointestinal signs are noted, but further recommendations are in large part dependent on patient's clinical history, and could include:

A routine fecal/giardia exam if not recently evaluated.

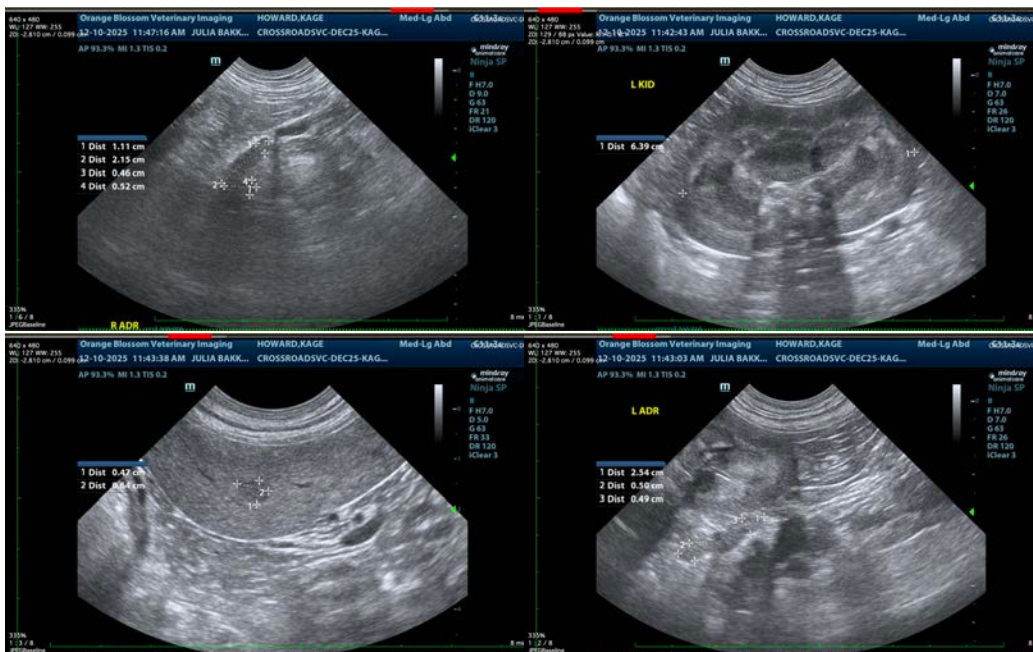
A fecal enteropathogen PCR panel to Texas A&M GI Laboratory could be considered for further evaluation of possible infectious disease. Contact lab for recommendations on how long to discontinue antibiotics (if indicated) prior to obtaining a stool sample for submission.

If gastrointestinal signs are present, a baseline cortisol is recommended. If baseline cortisol is less than 2, a full ACTH stimulation test is recommended to rule out hypoadrenocorticism.

In the meantime, while continuing workup, treatment recommendations are in large part depending on patient's clinical signs, results of above, etc. Having said that, empirical deworming with a 5-day course of Panacur is recommended.

If tolerated, a transition in diet is recommended, based on trial-and-error response.

Some options to consider include a gastrointestinal biome diet vs a hydrolyzed protein diet (sometimes several trials with different brands are necessary) vs a fiber response/colitis diet vs a bland, easy to digest or low-fat diet vs other.





PATIENT

Kage Howard

SPECIES

Canine

BREED

Pit Bull x

SEX

Neutered Male

AGE

8 Years

WEIGHT

64 lbs

INTERPRETED BY

Beth Johnson, DVM
DACVIM

IMAGING PERFORMED BY

Julia Bakker, DVM

HOSPITAL NAME

Orange Blossom
Veterinary Imaging

REFERRING VET

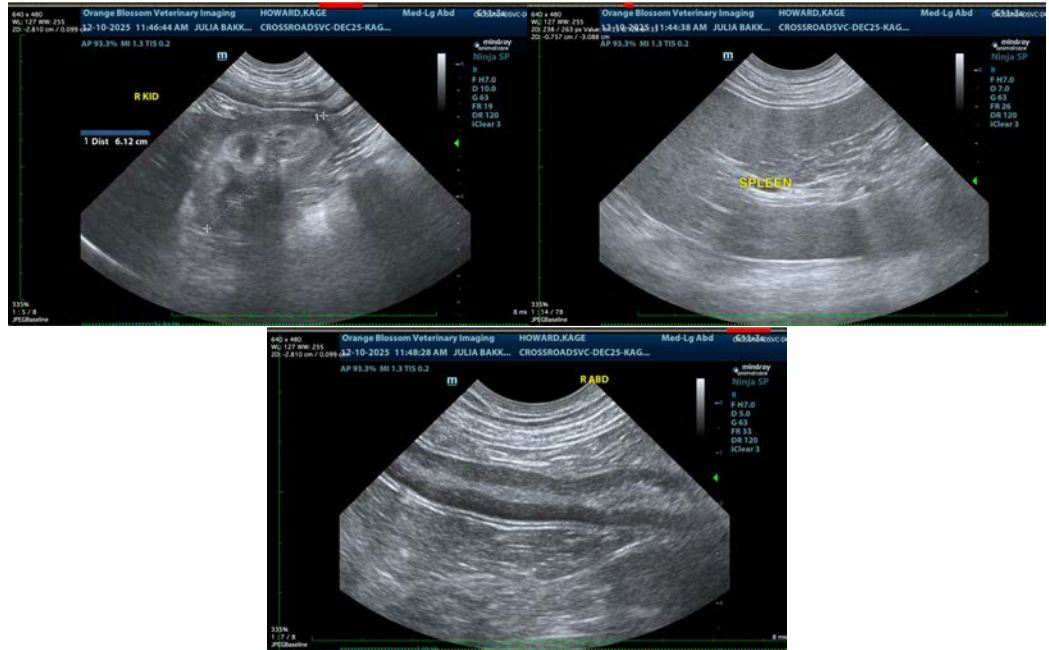
Arthur Newman, DVM

INVOICE

72478

DATE

12/10/25



The information and recommendations provided are based on the images presented by the referring veterinarian/sonographer. No evaluation can be communicated regarding pathology that was not visible in the image/video clips provided.

Thank you for this referral. If the clinical or image interpretation does not parallel your findings or if I can be of any further assistance please contact me.

Beth Johnson, DVM, DACVIM
info@sonopath.com