

DATE PRESENTING CLINICAL SIGNS

12/1/22 Has osteosarcoma on L front. suspect calcinosis cutis on exam. Suspect canine Cushing's disease - u/s to evaluate adrenal size and caudation

PATIENT

Kiwi Flynn
Current Medications: None listed.
Lab Results: calcinosis cutis/also elevated AP
Date of Previous IntraPet Ultrasound: No previous.
Sedation: Not required to complete full diagnostic ultrasound.
Stat Report: Not requested.

SPECIES

Canine

ULTRASONOGRAPHIC EXAMINATION OF THE ABDOMEN

BREED

English Bulldog

Urinary System

The urinary bladder is moderately distended with anechoic contents. No masses, inflammatory changes, echogenic sediment or cystoliths are observed. The urinary bladder, trigone and visible pelvic urethra are normal in thickness with a smooth mucosal surface.

SEX

Intact Female

The right kidney is normal in size (6.62 cm), shape and echogenicity. It has smooth peripheral margination. There is a normal 1:3 cortex to medulla ratio with appropriate corticomedullary distinction. There is no evidence of pyelectasia, mineral or infarcts observed. Non-obstructive linear multifocal hyperechoic diverticular foci with acoustic shadowing are noted.

AGE

1/18/12

The left kidney is normal in size (5.95 cm), shape and echogenicity. It has smooth peripheral margination. There is a normal 1:3 cortex to medulla ratio with appropriate corticomedullary distinction. There is no evidence of pyelectasia, mineral or infarcts observed. Non-obstructive linear multifocal hyperechoic diverticular foci with acoustic shadowing are noted. A cortical cyst is noted in the cranial pole of the left kidney.

WEIGHT

53.3 Pounds

INTERPRETED BY

Beth Johnson, DVM
DACVIM

Adrenal Glands

Adrenal glands are plump/swollen in size. Normal shape and contour are maintained without evidence of capsular invasion. Corticomedullary structure is unremarkable. Visible surrounding vasculature appears normal. The right adrenal gland measures 2.5 cm long x 0.79 cm at the cranial pole and 0.76 cm at the caudal pole. The left adrenal gland is normal in size 2.8 cm long x 0.85 cm at the cranial pole and 0.84 cm at the caudal pole.

IMAGING PERFORMED BY

Andi Parkinson RDMS

Spleen

The spleen is subjectively normal in size with a normal smooth capsular contour. Parenchyma is appropriately finely textured and homogenous with normal echogenicity relative to surrounding tissue (hyperechoic to liver). No focal nodules or masses are observed. Splenic vasculature appears normal.

HOSPITAL NAME

Everhart Vet Hospital

REFERRING VET

Dr. Goodman

Liver

Liver is subjectively enlarged with mildly irregular margins. Parenchyma is heterogenous characterized by multiple poorly defined hypoechoic nodules within otherwise hyperechoic liver parenchyma. An approximately 2.0 cm, slightly irregular mid left hypoechoic liver nodule is noted, as well as a deeper 1.0 cm x 2.0 cm hypoechoic liver nodule. Visible vasculature and biliary tree appear normal without distension or congestion.

INVOICE

43119

Gallbladder is moderately distended with anechoic bile as well as suspended and gravity dependent echogenic debris. The wall is smooth without visible thickening. There is no evidence of cystic or CBD dilation. There is no evidence of effusion or inflammation.

Gastrointestinal

The visible stomach wall is normal in thickness and layering. The lumen of the stomach is mildly distended with very echogenic reverberation artifact from intraluminal gas. There is no evidence of obstruction, foreign material or infiltrative disease; however, complete visualization of far wall is partially inhibited by gas. Pyloric outflow tract appears patent.

The visible small intestines are normal in wall thickness and layering (canine duodenum < 0.5 cm and feline duodenum < 0.4 cm; other < 0.3 cm). Small intestinal motility appears adequate (1-3 contractions per min). The lumen of the small intestine is empty with no evidence of obstruction, foreign material or infiltrative disease.

The visible colon is normal in wall thickness (< 0.2 cm) and layering. Contents are consistent with normal formed feces and gas.

Pancreas

The pancreatic parenchyma is appropriately isoechoic to surrounding tissue. Visible capsule is smooth and normal in contour. There is no visible pancreatic duct dilation. There is no evidence of active peripancreatic inflammation.

Free Abdomen

There is no evidence of free peritoneal effusion noted in these images.

There is no apparent lymphadenopathy noted in these images.

The patient is listed as intact. However, there is no evidence of a uterus or ovaries visible in these images, and uterus and ovaries were reportedly not visualized during the ultrasound exam.

PRIMARY FINDINGS

- **Bilateral adrenomegaly** – consistent with adrenal hyperplasia secondary to pituitary dependent hyperadrenocorticism vs stress or normal variant. Interpret in combination with clinical signs of hyperadrenocorticism.
- **Heterogenous Liver** – These changes are most consistent with benign processes such as nodular hyperplasia, steroid (vacuolar) hepatopathy, extramedullary hematopoiesis or possibly chronic inflammatory disease and less commonly infiltrative round cell or metastatic neoplasia. Given this patient's reported osteosarcoma, the more discrete nodules could represent metastatic lesions but is considered less likely.

SECONDARY FINDINGS

- **Gallbladder debris** - Cholecystic debris is of unknown clinical significance. It can be seen with biliary stasis from fasting or illness. Cholecystic debris is not necessarily related to hepatobiliary disease. Echogenic bile is most commonly an incidental finding in dogs and should be interpreted in combination with clinical signs such as nausea, inappetence, cranial abdominal discomfort and/or laboratory changes such as increased ALP and/or increased Tbili.
- Non-obstructive dystrophic mineralization bilaterally in the kidneys and a cortical cyst in the left.

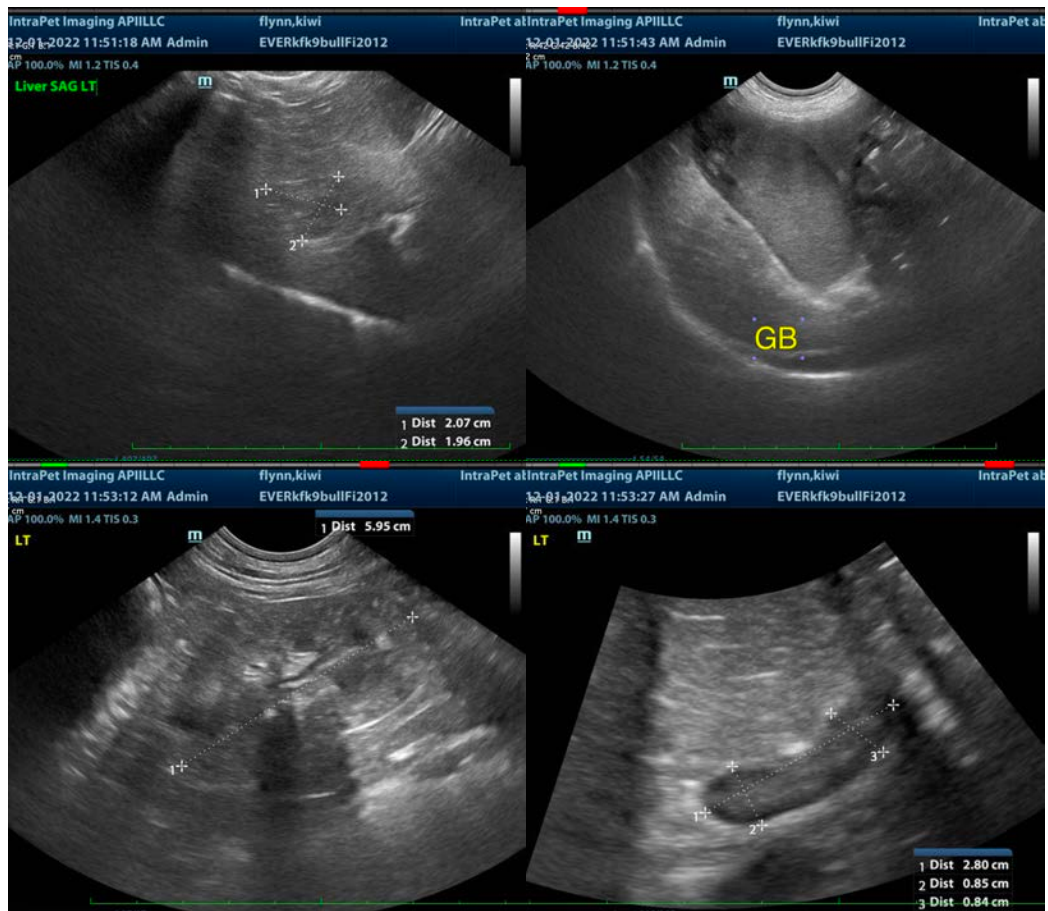
INTERPRETATION OF THE FINDINGS & FURTHER RECOMMENDATIONS

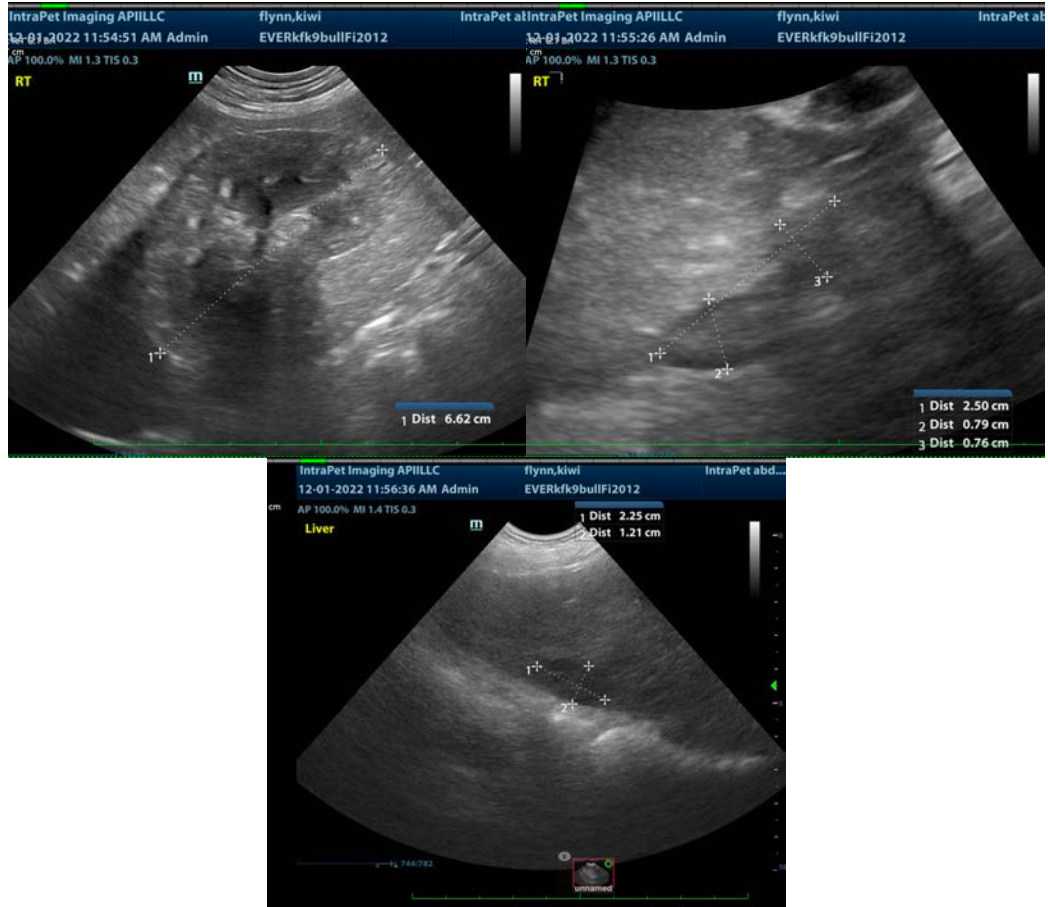
Given this patient's reported calcinosis cutis and adrenal gland changes noted above, testing for hyperadrenocorticism could be considered in the form of a low-dose Dexamethasone suppression test.

Additionally, a blood pressure is recommended if not recently evaluated.

Additionally, a fine needle aspirate of the liver could be considered to more definitively rule out metastatic disease if patient's coagulation status is appropriate.

Three view thoracic radiographs are recommended for further assessment of cardio-pulmonary status as well as to further evaluate for any evidence of metastatic disease, if not recently evaluated.





The information and recommendations provided are based on the images presented by the referring veterinarian/sonographer. No evaluation can be communicated regarding pathology that was not visible in the image/video clips provided.

Thank you for this referral. If the clinical or image interpretation does not parallel your findings or if I can be of any further assistance please contact me.

Beth Johnson, DVM, DACVIM
Beth.Johnson@sonopath.com