



**PATIENT**

Muggle Santia

**PRESENTING CLINICAL SIGNS**

Possible mass effect on survey radiographs, newly diagnosed diabetic/DKA. BG 694 on admit. Full bloods pending.

**SPECIES**

Canine

Abnormal PE/Chem/CBC/UA Results: U/A: 2+ ketone, 100mg/gluc, USG 1.040. HCT 28%, PCV/TP 8.

**BREED**

Mixed

**ULTRASONOGRAPHIC EXAMINATION OF THE ABDOMEN**

**Urinary System**

The urinary bladder is moderately distended with anechoic contents. No masses, inflammatory changes, echogenic sediment or cystoliths are observed. The urinary bladder, trigone and visible pelvic urethra are normal in thickness with a smooth mucosal surface.

**SEX**

Neutered Male

The prostate is normal in size and shape for this neutered male dog. The parenchyma is homogenous and the external margins are smooth. The prostatic urethra appears normal with no evidence of irregularity, invasion, mass effect or calculi.

**AGE**

8 Years

The right kidney is normal in size (6.67 cm), shape and echogenicity. It has smooth peripheral margination. There is a normal 1:3 cortex to medulla ratio with appropriate corticomedullary distinction. There is no evidence of pyelectasia, mineral or infarcts observed. A hyperechoic band parallel to the corticomedullary border is present.

**WEIGHT**

71 Pounds

The left kidney is normal in size (7.62 cm), shape and echogenicity. It has smooth peripheral margination. There is a normal 1:3 cortex to medulla ratio with appropriate corticomedullary distinction. There is no evidence of pyelectasia, mineral or infarcts observed. A hyperechoic band parallel to the corticomedullary border is present.

**INTERPRETED BY**

Beth Johnson, DVM  
DACVIM

**Adrenal Glands**

The right adrenal gland is normal in size (2.15 cm long x 0.96 cm at the cranial pole and 0.67 cm at the caudal pole), shape and contour. Corticomedullary structure is unremarkable. Visible surrounding vasculature appears normal.

**IMAGING PERFORMED BY**

Kelly Vazquez

The left adrenal gland is normal in size (2.17 cm long x 0.55 cm at the cranial pole and 0.38 cm at the caudal pole), shape and contour. Corticomedullary structure is unremarkable. Visible surrounding vasculature appears normal.

**HOSPITAL NAME**

Westwood Regional

**Spleen**

The spleen is subjectively normal in size with a normal smooth capsular contour. Parenchyma is appropriately finely textured and homogenous with normal echogenicity relative to surrounding tissue (hyperechoic to liver). No focal nodules or masses are observed. Splenic vasculature appears normal.

**REFERRING VET**

Dr. Aronow

**Liver**

Liver is subjectively enlarged (swollen contour) without disruption of architecture. It has a normal homogenous echotexture. Parenchyma is diffusely hyperechoic characterized by less prominent than normal portal vein walls and increased echogenicity relative to the spleen and falciform fat. No focal lesions are observed. Visible vasculature and biliary tree appear normal without distension or congestion.

**INVOICE**

42622

**DATE**

11/8/22

The gallbladder is non-distended in size. The wall is smooth without visible thickening. Luminal contents are primarily anechoic. There is no evidence of cystic or common bile duct dilation.



**PATIENT**

Muggle Santia

**SPECIES**

Canine

**BREED**

Mixed

**SEX**

Neutered Male

**AGE**

8 Years

**WEIGHT**

71 Pounds

**INTERPRETED BY**

Beth Johnson, DVM  
DACVIM

**IMAGING PERFORMED BY**

Kelly Vazquez

**HOSPITAL NAME**

Westwood Regional

**REFERRING VET**

Dr. Aronow

**INVOICE**

42622

**DATE**

11/8/22

**Gastrointestinal**

The visible stomach wall is normal in thickness and layering. The lumen of the stomach is mildly distended with echogenic non-shadowing luminal contents and gas consistent with normal ingesta. There is no evidence of obstruction, foreign material or infiltrative disease. Pyloric outflow tract appears patent.

The visible small intestines are normal in wall thickness and layering. Small intestinal motility appears adequate (1-3 contractions per min). The lumen of the small intestine is mildly distended with echogenic non-shadowing luminal contents and gas consistent with normal ingesta. There is no evidence of obstruction, foreign material or infiltrative disease.

The visible colon is normal in wall thickness (< 0.2 cm) and layering. Contents are consistent with normal formed feces and gas.

**Pancreas**

The pancreatic parenchyma is appropriately isoechoic to surrounding tissue. Visible capsule is smooth and normal in contour. There is no visible pancreatic duct dilation. There is no evidence of active peripancreatic inflammation.

**Free Abdomen**

There is no evidence of free peritoneal effusion noted in these images.

There is no apparent lymphadenopathy noted in these images.

**ULTRASONOGRAPHIC FINDINGS**

- **Hyperechoic hepatomegaly** - This appearance is non-specific and most consistent with a benign steroid (endocrine) or vacuolar hepatopathy or reactive or idiopathic hepatopathy. Inflammatory and/or infiltrative disease (such as round cell neoplasia) are also possible, but considered less likely.
- **Bilateral medullary rim sign** - This finding is of unknown clinical significance and can be a normal variant, often idiopathic. Medullary rim sign can be present with renal disease including FIP, lymphoma, hypercalcemic nephropathy, Leptospirosis, tubular disease, other and should be interpreted in combination with other more specific indications of kidney disease such as isosthenuria, proteinuria, azotemia, etc. This is a common incidental finding in patients with diabetes mellitus.

**INTERPRETATION OF THE FINDINGS & FURTHER RECOMMENDATIONS**

There is no visible evidence in these images of the reported suspect abdominal mass.

Recommendations include treating this patient's reported DKA, and when the patient is stable and eating well, transition to a longer-acting, at home insulin.



**PATIENT**

Muggle Santia

**SPECIES**

Canine

**BREED**

Mixed

**SEX**

Neutered Male

**AGE**

8 Years

**WEIGHT**

71 Pounds

**INTERPRETED BY**

Beth Johnson, DVM  
DACVIM

**IMAGING PERFORMED BY**

Kelly Vazquez

**HOSPITAL NAME**

Westwood Regional

**REFERRING VET**

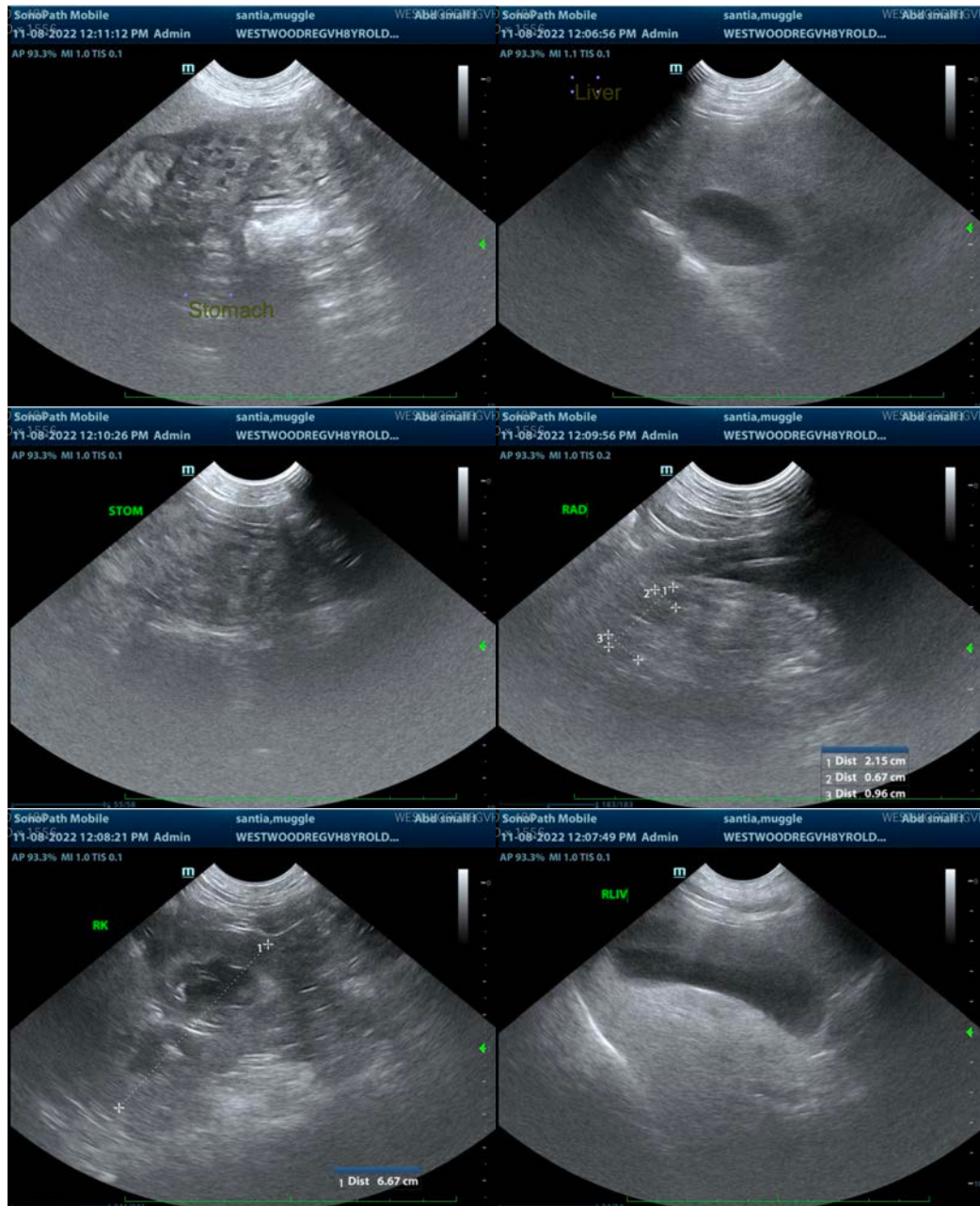
Dr. Aronow

**INVOICE**

42622

**DATE**

11/8/22





**PATIENT**

Muggle Santia

**SPECIES**

Canine

**BREED**

Mixed

**SEX**

Neutered Male

**AGE**

8 Years

**WEIGHT**

71 Pounds

**INTERPRETED BY**

Beth Johnson, DVM  
DACVIM

**IMAGING PERFORMED BY**

Kelly Vazquez

**HOSPITAL NAME**

Westwood Regional

**REFERRING VET**

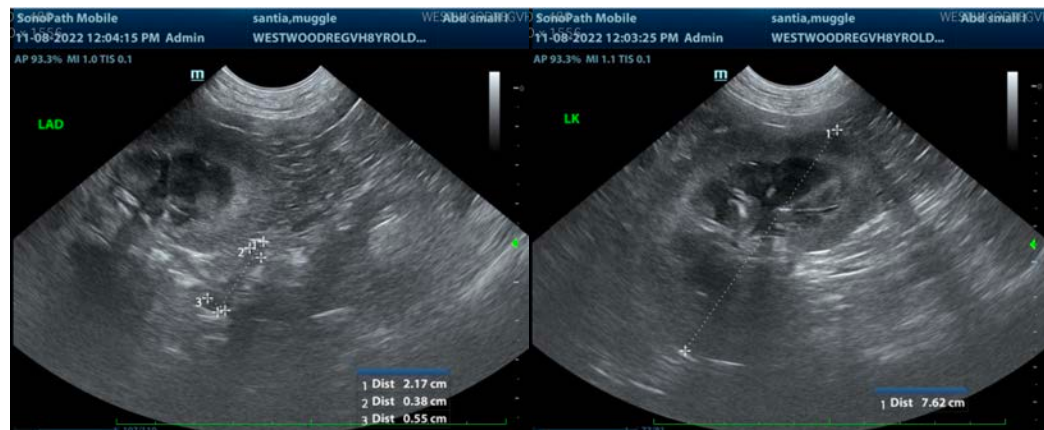
Dr. Aronow

**INVOICE**

42622

**DATE**

11/8/22



The information and recommendations provided are based on the images presented by the referring veterinarian/sonographer. No evaluation can be communicated regarding pathology that was not visible in the image/video clips provided.

Thank you for this referral. If the clinical or image interpretation does not parallel your findings or if I can be of any further assistance please contact me.

**Beth Johnson, DVM, DACVIM**  
Beth.Johnson@sonopath.com