

**DATE**

11/7/22

PRESENTING CLINICAL SIGNS

History: Pt presented on 11/5 for vomiting/diarrhea, lethargy. Treated at the ER for similar episode on 10/14/22, initial response to supportive care - cerenia, probiotic. No fb seen on rads, labs low chloride/low potassium. Re-presented on 10/26 for recurrent episode of vomiting/diarrhea. Initially did well on meds but had a relapse about 4 days after stopping metronidazole/cerenia. Presenting PE - MM very tacky, depressed appetite, GI signs.

PATIENT

Toby Dilonardo

SPECIES

Canine

BREED

Westie

Current Medications: cerenia restarted on 11/5 1 mg/kg sid, metronidazole restarted on 11/5 15 mg/kg bid
 Lab Results: Cl 108, rest nsf

Date of Previous IntraPet Ultrasound: No previous.

Sedation: Not required to complete full diagnostic ultrasound.

Stat Report: Not requested.

Imaging Performed By: Rachel Brillhart, RDMS.

SEX

Neutered Male

ULTRASONOGRAPHIC EXAMINATION OF THE ABDOMEN**AGE**

6/13/13

Urinary System

Urinary bladder is adequately distended with anechoic contents. No masses, inflammatory changes, echogenic sediment or cystoliths are observed. The urinary bladder, trigone and visible pelvic urethra are normal in thickness with a smooth mucosal surface.

Prostate is normal in size, echotexture and echogenicity for a neutered male. Several small mineral foci within the prostatic parenchyma were noted.

WEIGHT

12.65 Pounds

Left kidney is normal is size (4.12 cm), shape and echogenicity. It has smooth peripheral margination. There is a normal 1:3 cortex to medulla ratio with appropriate corticomedullary distinction. There is no evidence of pyelectasia or infarcts observed. Non-obstructive areas of mineralization/nephroliths are noted.

INTERPRETED BYBeth Johnson, DVM
DACVIM

Right kidney is normal is size (3.75 cm), shape and echogenicity. It has smooth peripheral margination. There is a normal 1:3 cortex to medulla ratio with appropriate corticomedullary distinction. There is no evidence of pyelectasia or infarcts observed. Non-obstructive areas of mineralization/nephroliths are noted.

HOSPITAL NAME

Everhart VH

Adrenal Glands

Left adrenal gland is normal in size (1.47 cm long x 0.78 cm at cranial pole and 0.55 cm at caudal pole), shape and overall architecture, echogenicity and echotexture. Visible surrounding vasculature appears normal.

REFERRING VET

Dr. Menefee

Right adrenal gland is normal in size (1.82 cm long x 0.52 cm at cranial pole and 0.46 cm at caudal pole), shape and overall architecture, echogenicity and echotexture. Visible surrounding vasculature appears normal.

INVOICE

17897

Spleen

Spleen is generally normal in size and shape with a smooth capsular contour. Parenchyma is diffusely nodular in appearance characterized by small discrete hypoechoic nodules. Splenic vasculature appears normal.

Liver

Liver is subjectively enlarged with mildly irregular margins. Parenchyma is heterogenous characterized by multiple poorly defined hypoechoic nodules within otherwise hyperechoic liver parenchyma. Visible vasculature and biliary tree appear normal without distension or congestion.

Gallbladder is moderately distended with anechoic bile as well as suspended and gravity dependent echogenic debris. The wall is smooth without visible thickening. There is no evidence of cystic or CBD dilation. There is no evidence of effusion or inflammation.

Gastrointestinal

The visible stomach wall is normal in thickness and layering. The lumen of the stomach is mildly distended with very echogenic reverberation artifact from intraluminal gas. There is no evidence of obstruction, foreign material or infiltrative disease; however, complete visualization of far wall is partially inhibited by gas. Pyloric outflow tract appears patent.

The visible small intestines are normal in wall thickness and layering. Hyperechoic mucosal fogging or speckling is noted. Small intestinal motility appears adequate (1-3 contractions per min). The lumen of the small intestine is empty with no evidence of obstruction, foreign material or infiltrative disease.

The visible colon is normal in wall thickness and layering. Contents are consistent with normal formed feces and gas.

Pancreas

Pancreas is prominent (enlarged) in size and mildly irregular in shape with a slightly undulating contour. Parenchyma is coarse in echotexture and heterogenous to hypoechoic in echogenicity.

Free Abdomen

There is no evidence of peritoneal effusion.

Prominent rounded colonic lymph nodes are noted.

ULTRASONOGRAPHIC FINDINGS

Primary Findings

- Mucosal speckling – Mucosal speckling is often present with inflammatory bowel disease (IBD). It is not specific for type or severity of disease. Mild speckling change can occur as a normal patient variant in the post-prandial state.
- Hypoechoic round colonic lymph nodes are noted. Differentials for which include both reactive lymphadenopathy, as well as infiltrative neoplasia and cannot be differentiated without tissue sampling.
- Chronic active pancreatitis (resolving acute pancreatitis cannot be ruled out).
- Heterogenous Liver – These changes are most consistent with benign processes such as nodular hyperplasia, steroid (vacuolar) hepatopathy, extramedullary hematopoiesis or possibly chronic inflammatory disease and less commonly infiltrative round cell or metastatic neoplasia.
- Gallbladder debris - Cholecystic debris is of unknown clinical significance. It can be seen with biliary stasis from fasting or illness. Cholecystic debris is not necessarily related to hepatobiliary disease. Echogenic bile is most commonly an incidental finding in dogs and should be interpreted in

combination with clinical signs such as nausea, inappetence, cranial abdominal discomfort and/or laboratory changes such as increased ALP and/or increased Tbili.

Secondary Findings

- Nonobstructive nephrolithiasis bilaterally in the kidneys
- Mineral foci within the prostate, likely normal aging variant, however, chronic resolved or even mild active prostatitis cannot be ruled out.
- Splenic micronodular hyperplasia – This nodular change is often associated with benign aging nodular hyperplasia. Infiltrative neoplasia, however, including both early hemangiosarcoma as well as round cell neoplasia cannot be ruled out.

INTERPRETATION OF THE FINDINGS & FURTHER RECOMMENDATIONS

Given this patients reported gastrointestinal signs, recommendations include:

A gastrointestinal malabsorption panel (including cobalamin, folate, TLI and PLI) to Texas A&M GI Laboratory is recommended for further evaluation of GI and pancreatic function.

A baseline cortisol is recommended. If baseline cortisol is less than 2, a full ACTH stimulation test is recommended to rule out hypoadrenocorticism.

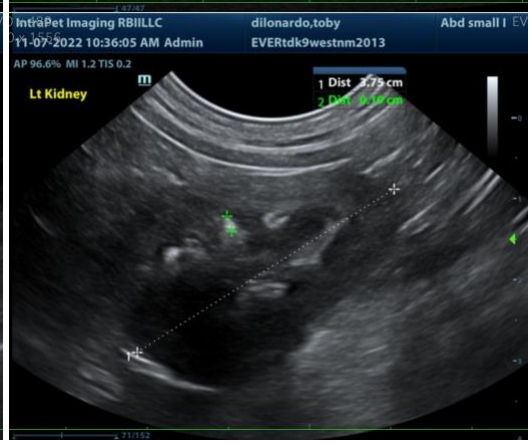
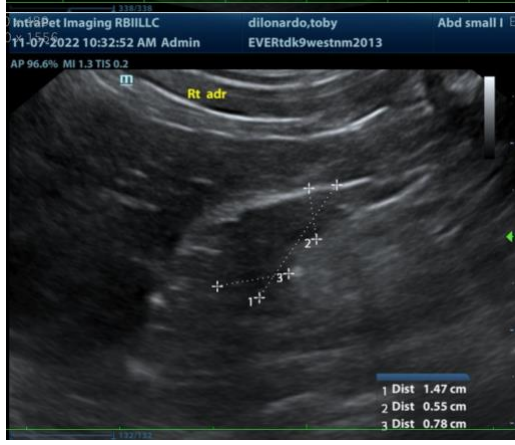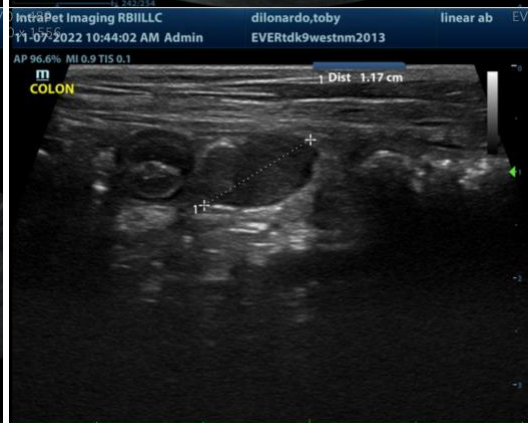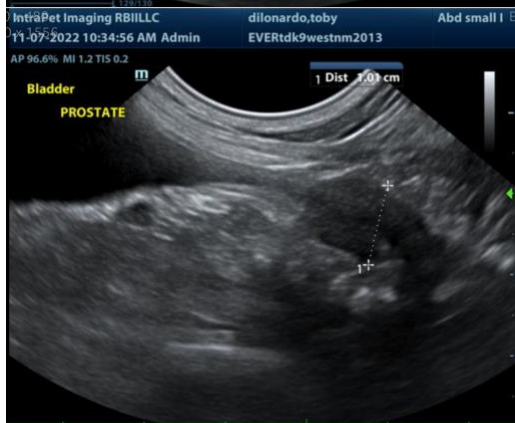
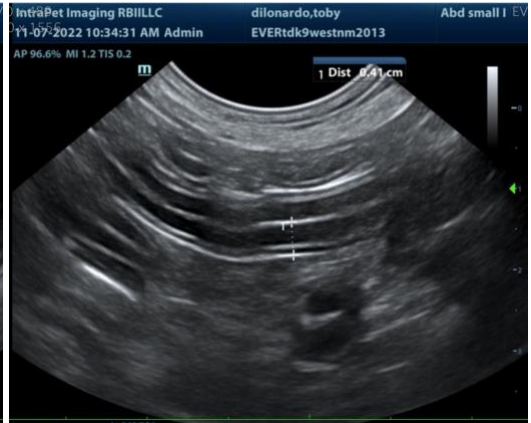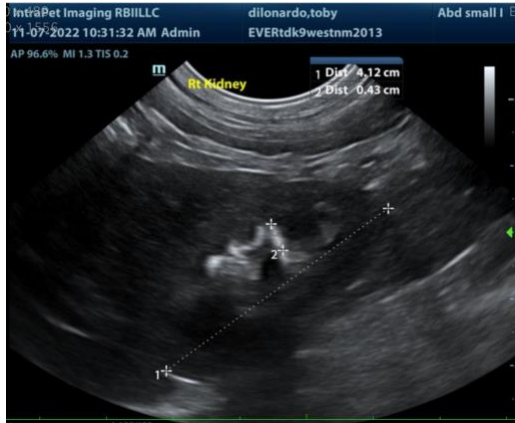Given predominately the colonic lymph node changes, a fecal exam is recommended, if not recently evaluated, as is a fecal enteropathogen PCR panel to Texas A&M GI Laboratory could be considered for further evaluation of possible infectious disease.

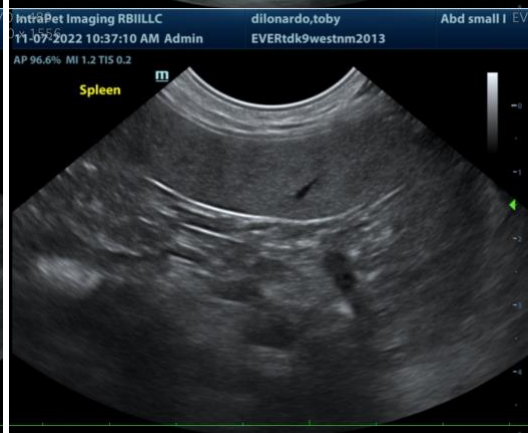
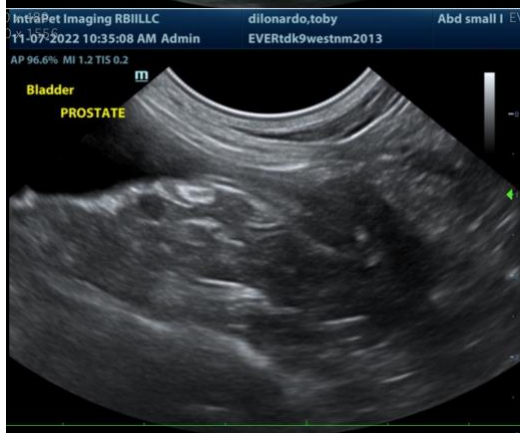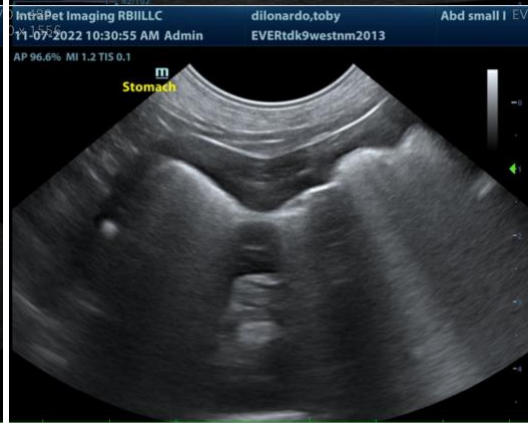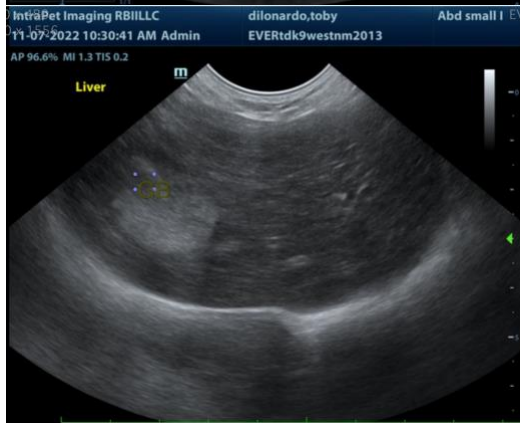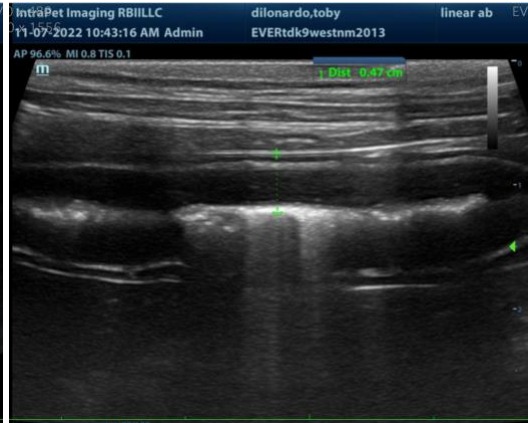
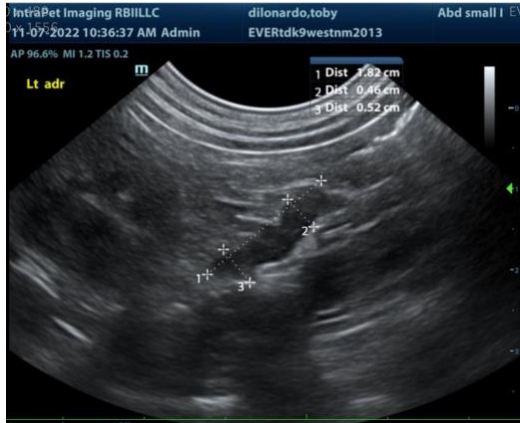If possible to safely reach and if patient coagulation status is appropriate, a fine needle aspirate of the enlarged colonic lymph nodes could be considered.

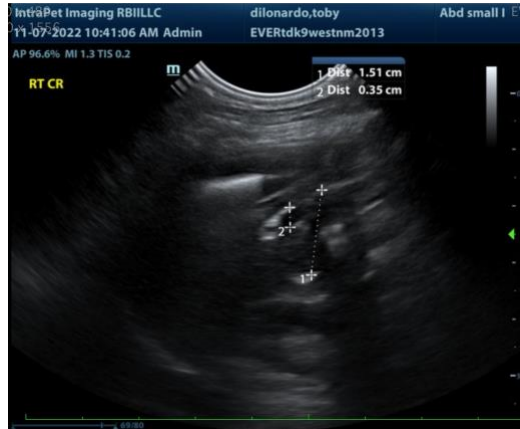In the meantime, empirical deworming with a 5-day course of Panacur is recommended, as is a probiotic such as Provable or Visbiome and transition to a diet based on trial and error response is recommended, beginning potentially with a hydrolyzed protein diet, considering multiple brands if one brand doesn't help alleviate clinical signs and/or proceeding to a fiber responsive colitis diet if a hydrolyzed protein diet doesn't work, etc.

If long term antibiotics are necessary to help control the diarrhea, transition from Metronidazole to Tylosin is recommended to reduce side effects of therapy.

Ultimately, if clinical signs persist, and a diagnosis is not obtained, upper and lower GI endoscopy/colonoscopy may be necessary for further evaluation and biopsies.







The information and recommendations provided are based on the images presented by the referring veterinarian. No evaluation can be communicated regarding pathology that was not visible in the image/video clips provided.

Thank you for this referral. If the clinical or image interpretation does not parallel your findings or if I can be of any further assistance please contact me.

Beth Johnson, DVM DACVIM
Beth.Johnson@SonoPath.com