

**DATE**

11/7/22

**PRESENTING CLINICAL SIGNS**

History: Problem with anesthesia as puppy during spay procedure->found portosystemic shunt, which was repaired. PE symptoms thought to be anxiety related but may be petit-mal seizure related - teeth chattering, pacing, panting - always per owner

**PATIENT**

Chloe Bowen

Current Medications: gabapentin 100 mg - 1 once daily for anxiety

**SPECIES**

Canine

Lab Results: 10/21/22: Alb 5.2 (3.9), AST 205 (55), T bili 0.5 (0.3), conjugated bili 0.4 (0.1), 4+ hemolysis and lipemia, u/a usg 1.036, trace protein, 1+ bilirubin. LABS - repeated fasted/add diags 11/2/22: chemistry wnl, bile acid assay - pre 45.5 (14.9), 2 hour post

**BREED**

Yorkie Mix

60 (29). LABS 11/3/22: PT/PTT, cPL, fecal - pending

Date of Previous IntraPet Ultrasound: No previous.

Sedation: Not required to complete full diagnostic ultrasound.

Stat Report: Not requested.

Imaging Performed By: Stephanie Warga RDCS, RVT.

**SEX**

Spayed Female

**ULTRASONOGRAPHIC EXAMINATION OF THE ABDOMEN****AGE**

9/19/18

**Urinary System**

Urinary bladder is adequately distended with anechoic contents. No masses, inflammatory changes, echogenic sediment or cystoliths are observed. The urinary bladder, trigone and visible pelvic urethra are normal in thickness with a smooth mucosal surface.

**WEIGHT**

15.5 Pounds

Left kidney is normal is size (3.92 cm), shape and echogenicity. It has smooth peripheral margination. There is a normal 1:3 cortex to medulla ratio with appropriate corticomedullary distinction. There is no evidence of pyelectasia, mineral or infarcts observed.

**INTERPRETED BY**

Beth Johnson, DVM  
DACVIM

Right kidney is normal is size (4.38 cm), shape and echogenicity. It has smooth peripheral margination. There is a normal 1:3 cortex to medulla ratio with appropriate corticomedullary distinction. There is no evidence of pyelectasia, mineral or infarcts observed.

**HOSPITAL NAME**

Noah's Ark Veterinary  
And BR

**Adrenal Glands**

Left adrenal gland is normal in size (1.88 cm long x 0.4 cm at cranial pole and 0.44 cm at caudal pole), shape and overall architecture, echogenicity and echotexture. Visible surrounding vasculature appears normal.

Right adrenal gland is normal in size (1.83 cm long x 0.68 cm at cranial pole and 0.47 cm at caudal pole), shape and overall architecture, echogenicity and echotexture. Visible surrounding vasculature appears normal.

**REFERRING VET**

Dr. Holstein

**Spleen**

Spleen is subjectively normal in size with a normal smooth capsular contour. Parenchyma is appropriately finely textured and homogenous with normal echogenicity relative to surrounding tissue (hyperechoic to liver). No focal nodules or masses are observed. Splenic vasculature appears normal.

**INVOICE**

17905

**Liver**

Liver is subjectively normal in size with normal smooth curvilinear peripheral contour. Parenchyma is appropriately hypoechoic to the spleen in echogenicity and appropriately mildly coarse and homogenous in echotexture. No focal lesions are observed. Visible vasculature and biliary tree appear normal without distension or congestion.

Gallbladder is non-distended in size. The wall is smooth without visible thickening. Luminal contents are primarily anechoic. There is no evidence of cystic or common bile duct dilation.

### ***Gastrointestinal***

The visible stomach wall is normal in thickness and layering. The lumen of the stomach is mildly distended with very echogenic reverberation artifact from intraluminal gas. There is no evidence of obstruction, foreign material or infiltrative disease; however, complete visualization of far wall is partially inhibited by gas. Pyloric outflow tract appears patent.

The visible small intestines are normal in wall thickness and layering. Small intestinal motility appears adequate (1-3 contractions per min). The lumen of the small intestine is empty with no evidence of obstruction, foreign material or infiltrative disease.

The visible colon is normal in wall thickness and layering. Contents are consistent with normal formed feces and gas.

### ***Pancreas***

The observed pancreas appears appropriately isoechoic to surrounding omental fat. Visible capsule is smooth and normal in contour. Visible pancreatic parenchyma is homogenous and unremarkable. There is no visible pancreatic duct dilation. There is no evidence of active peripancreatic inflammation.

### ***Free Abdomen***

There is no evidence of peritoneal effusion. There is no apparent lymphadenopathy.

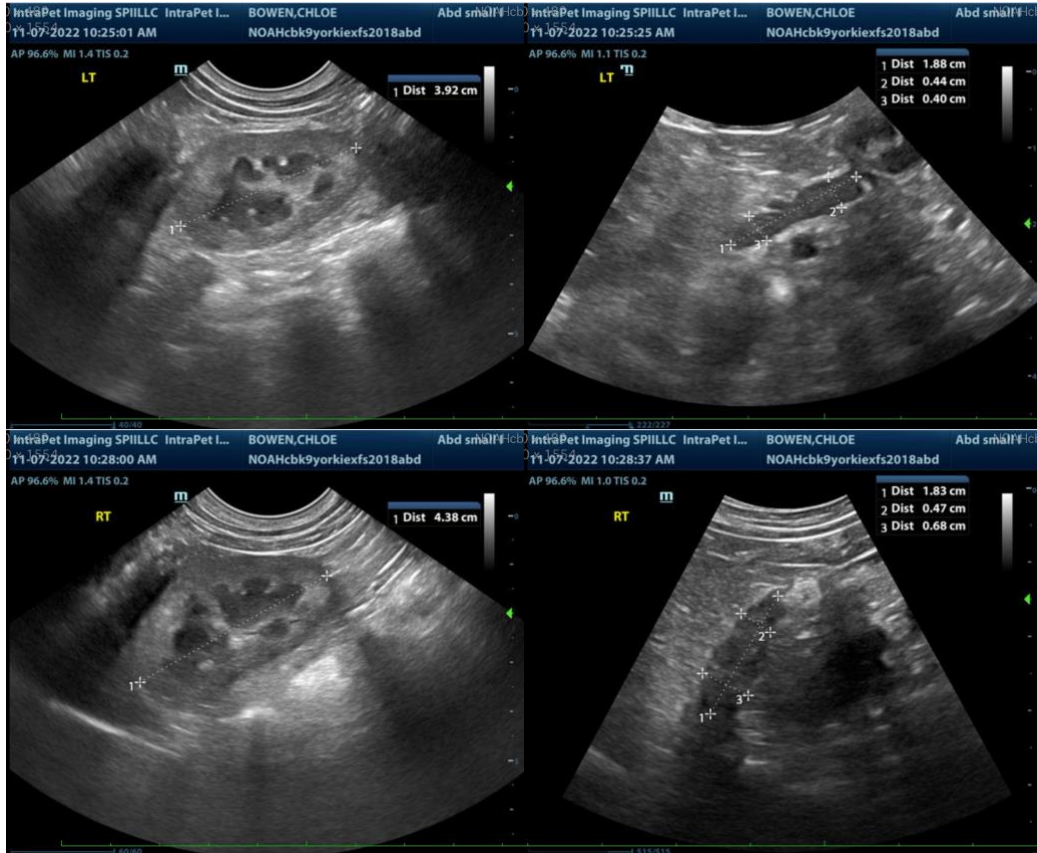
## **ULTRASONOGRAPHIC FINDINGS**

- This is a relatively normal/unremarkable abdomen

## **INTERPRETATION OF THE FINDINGS & FURTHER RECOMMENDATIONS**

The mildly increased bile acids could suggest persistent portosystemic shunting following surgery or could be suggestive of multiple acquired shunts following surgery. Recommendations include a contrast abdominal CT scan for further evaluation. Additionally, consultation with a neurologist could be considered to help determine whether the clinical signs in question are in fact seizures or not and if there are believed to be neurologic in origin, empirical medical management of hepatic encephalopathy in the form of a liver diet, if tolerated, antibiotics, potentially lactulose and an antiepileptic, such as Keppra could all be considered.

If the clinical signs are not neurologic in origin, then medical management for hepatic encephalopathy is likely not necessary. If it can't be determined whether or not the seizures are not, empirical therapy could be tried and only continued and only continued if it results in improvement of the clinical signs.



The information and recommendations provided are based on the images presented by the referring veterinarian. No evaluation can be communicated regarding pathology that was not visible in the image/video clips provided.

Thank you for this referral. If the clinical or image interpretation does not parallel your findings or if I can be of any further assistance please contact me.

**Beth Johnson, DVM DACVIM**  
Beth.Johnson@SonoPath.com