



PATIENT

Milo Ghany

PRESENTING CLINICAL SIGNS

R/O foreign body ingestion. Vomiting blood.

SPECIES

Canine

ULTRASONOGRAPHIC EXAMINATION OF THE ABDOMEN

Urinary System

The urinary bladder is adequately distended with anechoic contents. No masses, inflammatory changes, echogenic sediment or cystoliths are observed. The urinary bladder, trigone and visible pelvic urethra are normal in thickness with a smooth mucosal surface.

BREED

Goldendoodle

Prostate is normal in size, echotexture, and echogenicity for a neutered male.

SEX

Neutered Male

The right kidney is normal is size (4.01 cm), shape and echogenicity. It has smooth peripheral margination. There is a normal 1:3 cortex to medulla ratio with appropriate corticomedullary distinction. There is no evidence of pyelectasia, mineral or infarcts observed. A subtle hyperechoic band parallel to the corticomedullary border is present.

AGE

1 year and 7 months

The left kidney is normal is size (4.63 cm), shape and echogenicity. It has smooth peripheral margination. There is a normal 1:3 cortex to medulla ratio with appropriate corticomedullary distinction. There is no evidence of pyelectasia, mineral or infarcts observed. A subtle hyperechoic band parallel to the corticomedullary border is present.

WEIGHT

33.5 lbs

Adrenal Glands

INTERPRETED BY

Beth Johnson, DVM
DACVIM

The right adrenal gland is normal in size (0.9 cm at cranial pole and 0.52 cm at caudal pole), shape and overall architecture, echogenicity and echotexture. Visible surrounding vasculature appears normal.

The left adrenal gland is normal in size (0.63 cm at cranial pole and 0.54 cm at caudal pole), shape and overall architecture, echogenicity and echotexture. Visible surrounding vasculature appears normal.

IMAGING PERFORMED BY

Kerri Becker

Spleen

The spleen is subjectively normal in size (1.7 cm thick at the hilus) with a normal smooth capsular contour. Parenchyma is appropriately finely textured and homogenous with normal echogenicity relative to surrounding tissue (hyperechoic to liver). No focal nodules or masses are observed. Splenic vasculature appears normal.

HOSPITAL NAME

Newbridge Vets

Liver

The liver is subjectively normal in size with normal smooth curvilinear peripheral contour. Parenchyma is appropriately hypoechoic to the spleen in echogenicity and appropriately mildly coarse and homogenous in echotexture. No focal lesions are observed. Visible vasculature and biliary tree appear normal without distension or congestion.

REFERRING VET

Dr. Glennon

INVOICE

10690

The gallbladder is non-distended in size. The wall is smooth without visible thickening. Luminal contents are primarily anechoic. There is no evidence of cystic or common bile duct dilation.

DATE

11/5/2025

Gastrointestinal

The visible stomach wall is normal in thickness and layering. The lumen of the stomach is empty with no evidence of obstruction, foreign material or infiltrative disease. Pyloric outflow tract appears patent.



PATIENT

Milo Ghany

SPECIES

Canine

BREED

Goldendoodle

SEX

Neutered Male

AGE

1 year and 7 months

WEIGHT

33.5 lbs

INTERPRETED BY

Beth Johnson, DVM
 DACVIM

IMAGING PERFORMED BY

Kerri Becker

HOSPITAL NAME

Newbridge Vets

REFERRING VET

Dr. Glennon

INVOICE

10690

DATE

11/5/2025

The visible small intestines are normal in wall thickness and layering. Small intestinal motility appears adequate (1-3 contractions per min). The lumen of the small intestine is mildly distended with very echogenic reverberation artifact from intraluminal gas. There is no evidence of obstruction, foreign material, or infiltrative disease; however, visualization is partially inhibited by gas. In some views the intraluminal gas has a bright echogenic appearance with some acoustic shadow that is most consistent with gas, however, non-obstructive small shadowing foreign object or foreign objects, while though less likely, can't be definitively ruled out.

The visible colon is normal in wall thickness (< 0.2 cm) and layering. Contents are consistent with normal formed feces and gas.

Pancreas

The pancreas that is observed appears appropriately isoechoic to surrounding omental fat. Visible capsule is smooth and normal in contour. Visible pancreatic parenchyma is homogenous and unremarkable. There is no visible pancreatic duct dilation. There is no evidence of active peripancreatic inflammation.

Free Abdomen

There is no visible free peritoneal effusion noted in these images.

There is no apparent pathologic lymphadenopathy noted in these images.

ULTRASONOGRAPHIC FINDINGS

- As mentioned above the small bowel contains gas that in several areas has some acoustic shadowing, however, there is no obstructive pattern, plication, or other indication of foreign material present in these images at this time. While the shadowing is most consistent with gas, while thought less likely, small non-obstructive foreign object or foreign objects can't be definitively ruled out.
- Subtle bilateral medullary rim sign - This finding is of unknown clinical significance and can be a normal variant, often idiopathic. Medullary rim sign can be present with renal disease including lymphoma, hypercalcemic nephropathy, Leptospirosis, tubular disease, other and should be interpreted in combination with other more specific indications of kidney disease such as isosthenuria, proteinuria, azotemia, etc. This is a common incidental finding in patients with diabetes mellitus.

INTERPRETATION OF THE FINDINGS & FURTHER RECOMMENDATIONS

If not recently evaluated, a general metabolic health screen (CBC, chemistry panel with electrolytes and urinalysis) is recommended.

A routine fecal/giardia exam is recommended if not recently evaluated.

A gastrointestinal malabsorption panel (including cobalamin, folate, TLI and PLI) to Texas A&M GI Laboratory is recommended for further evaluation of GI and pancreatic function.

A baseline cortisol is recommended. If baseline cortisol is less than 2, a full ACTH stimulation test is recommended to rule out hypoadrenocorticism +/- a fecal enteropathogen PCR panel to Texas A&M GI Laboratory could be considered for further evaluation of possible infectious disease. Contact lab for



PATIENT

Milo Ghany

SPECIES

Canine

BREED

Goldendoodle

SEX

Neutered Male

AGE

1 year and 7 months

WEIGHT

33.5 lbs

INTERPRETED BY

Beth Johnson, DVM
 DACVIM

IMAGING PERFORMED BY

Kerri Becker

HOSPITAL NAME

Newbridge Vets

REFERRING VET

Dr. Glennon

INVOICE

10690

DATE

11/5/2025

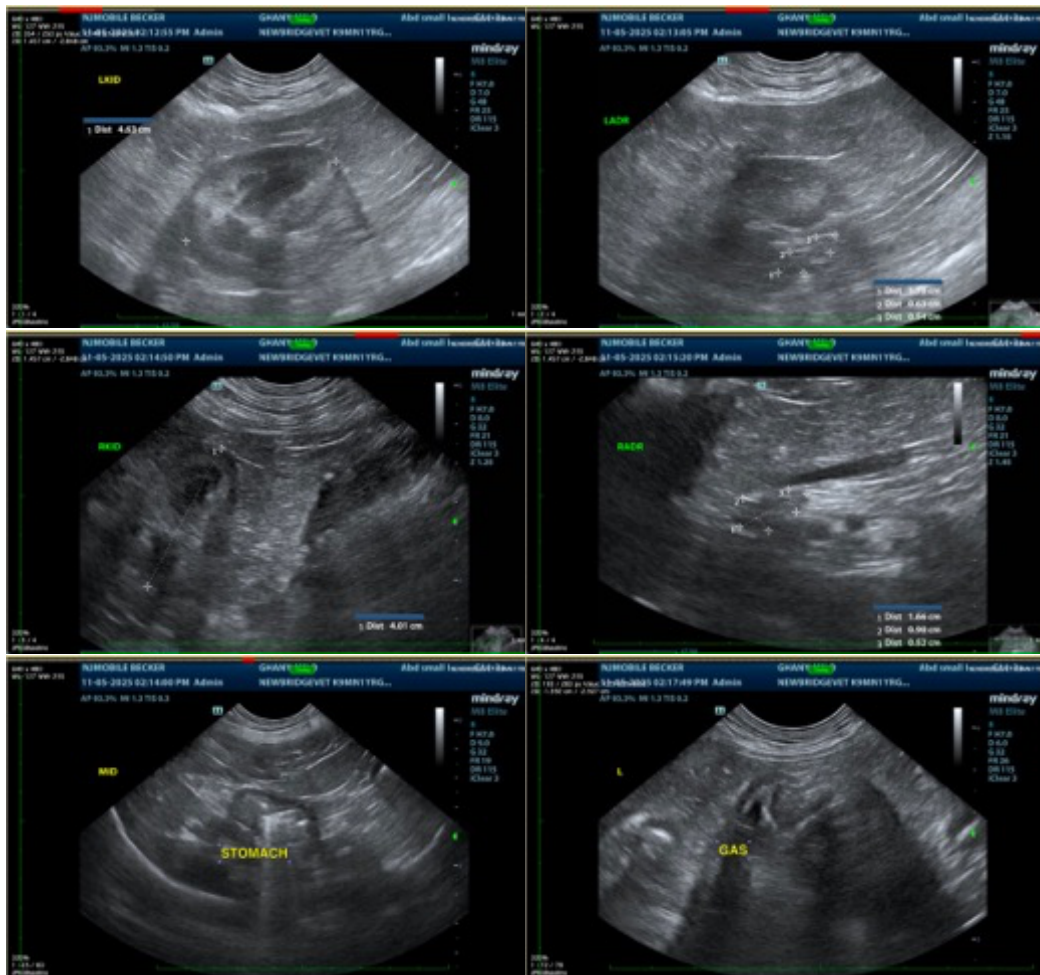
recommendations on how long to discontinue antibiotics (if indicated) prior to obtaining a stool sample for submission.

In the meantime, supportive/symptomatic medical management of clinical signs is recommended, including anti-emetics, gastroprotectants (+/- sucralfate, especially with any history of hematemesis), an appetite stimulant and fluid therapy if indicated, etc.

Additionally, empirical deworming with a 5-day course of Panacur is recommended as is a full course of empirical Helicobacter triple therapy.

Finally, if tolerated, a transition in diet could be considered, based on trial-and-error response with some options to consider including a gastrointestinal biome diet vs a hydrolyzed protein diet (sometimes several trials with different brands are necessary) vs an easy to digest, bland or low-fat diet vs other.

IF clinical signs persist, and a diagnosis is not obtained, re-check/follow up imaging and/or additional imaging such as contrast radiography versus other could be considered.





PATIENT

Milo Ghany

SPECIES

Canine

BREED

Goldendoodle

SEX

Neutered Male

AGE

1 year and 7 months

WEIGHT

33.5 lbs

INTERPRETED BY

Beth Johnson, DVM
DACVIM

IMAGING PERFORMED BY

Kerri Becker

HOSPITAL NAME

Newbridge Vets

REFERRING VET

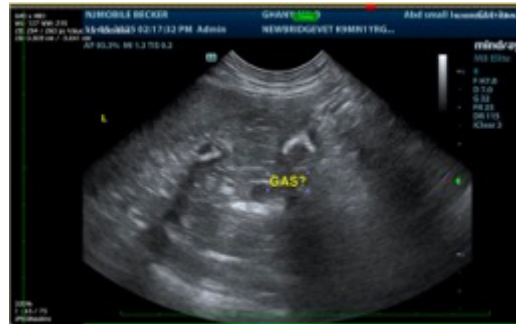Dr. Glennon

INVOICE

10690

DATE

11/5/2025



The information and recommendations provided are based on the images presented by the referring veterinarian/sonographer. No evaluation can be communicated regarding pathology that was not visible in the image/video clips provided.

Thank you for this referral. If the clinical or image interpretation does not parallel your findings or if I can be of any further assistance please contact me.

Beth Johnson, DVM, DACVIM
info@sonopath.com