



PATIENT

Kaia Maker

SPECIES

Feline

BREED

Domestic Shorthair

SEX

Spayed Female

AGE

8 years 6 months

WEIGHT

6.72

INTERPRETED BY

Beth Johnson, DVM
 DACVIM

IMAGING PERFORMED BY

Dr. Ken Leal

HOSPITAL NAME

Newton Veterinary
 Hospital

REFERRING VET

Dr. Collin Timony

INVOICE

10687

DATE

11/5/2025

PRESENTING CLINICAL SIGNS

Constipation, weight loss. 11/3/25: vomiting large amounts of stool felt Today: still vomiting, no feces felt, not eating losing weight Medications: la tumors 2 ml tid.

Abnormal PE/Chem/CBC/UA Results: Ca = 11.7 AST= 71

ULTRASONOGRAPHIC EXAMINATION OF THE ABDOMEN

Urinary System

The urinary bladder is adequately distended with anechoic contents. No masses, inflammatory changes, echogenic sediment or cystoliths are observed. The urinary bladder, trigone and visible pelvic urethra are normal in thickness with a smooth mucosal surface.

The right kidney is normal is size (3.34 cm), shape and echogenicity. It has smooth peripheral margination. There is a normal 1:3 cortex to medulla ratio with appropriate corticomedullary distinction. There is no evidence of pyelectasia, mineral or infarcts observed.

The left kidney is normal is size (3.27 cm), shape and echogenicity. It has smooth peripheral margination. There is a normal 1:3 cortex to medulla ratio with appropriate corticomedullary distinction. There is no evidence of pyelectasia, mineral or infarcts observed.

Adrenal Glands

The right adrenal gland is normal in size (0.52 cm), shape and overall architecture, echogenicity and echotexture. Visible surrounding vasculature appears normal.

The left adrenal gland is normal in size (0.41 cm), shape and overall architecture, echogenicity and echotexture. Visible surrounding vasculature appears normal.

Spleen

The spleen is subjectively normal in size with a normal smooth capsular contour. Parenchyma is appropriately finely textured and homogenous with normal echogenicity relative to surrounding tissue (hyperechoic to liver). No focal nodules or masses are observed. Splenic vasculature appears normal.

Liver

The liver is subjectively normal in size with normal smooth curvilinear peripheral contour. Parenchyma is appropriately hypoechoic to the spleen in echogenicity and appropriately mildly coarse and homogenous in echotexture. No focal lesions are observed. Visible vasculature and biliary tree appear normal without distension or congestion.

The gallbladder is non-distended in size. The wall is smooth without visible thickening. Luminal contents are primarily anechoic. There is no evidence of cystic or common bile duct dilation.

Gastrointestinal

The visible stomach wall is normal in thickness and layering. The lumen of the stomach is mildly distended with echogenic non-shadowing luminal contents and gas consistent with normal ingesta. There is no evidence of obstruction or foreign material noted. Pyloric outflow tract appears patent.



PATIENT

Kaia Maker

SPECIES

Feline

BREED

Domestic Shorthair

SEX

Spayed Female

AGE

8 years 6 months

WEIGHT

6.72

INTERPRETED BY

Beth Johnson, DVM
DACVIM

**IMAGING
PERFORMED BY**

Dr. Ken Leal

HOSPITAL NAME

Newton Veterinary
Hospital

REFERRING VET

Dr. Collin Timony

INVOICE

10687

DATE

11/5/2025

The visible small intestine demonstrates areas of mild to moderately thick muscularis layer relative to mucosa (disruption of the normal 1:3 muscularis:mucosa ratio). Small intestinal submucosa is slightly irregular, thick and hyperechoic, without evident loss of layering appreciated. The lumen of the small intestine is mildly distended with echogenic non-shadowing luminal contents and gas consistent with normal ingesta. There is no evidence of obstruction or foreign material noted. This change is most prominent in the ileum.

The visible colon is normal in wall thickness (< 0.2 cm) and layering. Contents are consistent with normal formed feces and gas.

Pancreas

The pancreas that is observed appears appropriately isoechoic to surrounding omental fat. Visible capsule is smooth and normal in contour. Visible pancreatic parenchyma is homogenous and unremarkable. There is no visible pancreatic duct dilation. There is no evidence of active peripancreatic inflammation.

Free Abdomen

There is no visible free peritoneal effusion noted in these images.

There is no apparent pathologic lymphadenopathy noted in these images.

ULTRASONOGRAPHIC FINDINGS

- Mild to moderate Inflammatory bowel disease (IBD) pattern – Thick muscularis has been reported with infiltrative bowel disease including both benign inflammatory disease as well as infiltrative neoplasia such as lymphoma. No loss of layering, etc. is noted to make lymphoma more probable, but lymphoma cannot be definitively ruled out without tissue sampling. This change is most prominent at the level of the ileum.

INTERPRETATION OF THE FINDINGS & FURTHER RECOMMENDATIONS

If patient remains clinically and/or radiographically constipated, ongoing constipation may be the primary contributing factory to patient's reported vomiting, decreased appetite, and weight loss, and more aggressive management may be indicated. Similarly, if patient is hypercalcemic, hypercalcemia could be contributing to constipation and further work up and treatment may be warranted, beginning with a malignancy panel (PTH, PTHrP, iCa) to Michigan State College of Veterinary Medicine is recommended for further investigation of the reported hypercalcemia.

Having said that, there are some subtle, mild changes indicating that concurrent small bowel disease could also be contributing. Therefore additionally, a gastrointestinal malabsorption panel (including cobalamin, folate, TLI and PLI) to Texas A&M GI Laboratory is recommended for further evaluation of GI and pancreatic function.

Beyond the above recommendations, further diagnostic and treatment recommendations are largely dependent on results of above.



PATIENT

Kaia Maker

SPECIES

Feline

BREED

Domestic Shorthair

SEX

Spayed Female

AGE

8 years 6 months

WEIGHT

6.72

INTERPRETED BY

Beth Johnson, DVM
 DACVIM

IMAGING PERFORMED BY

Dr. Ken Leal

HOSPITAL NAME

Newton Veterinary
 Hospital

REFERRING VET

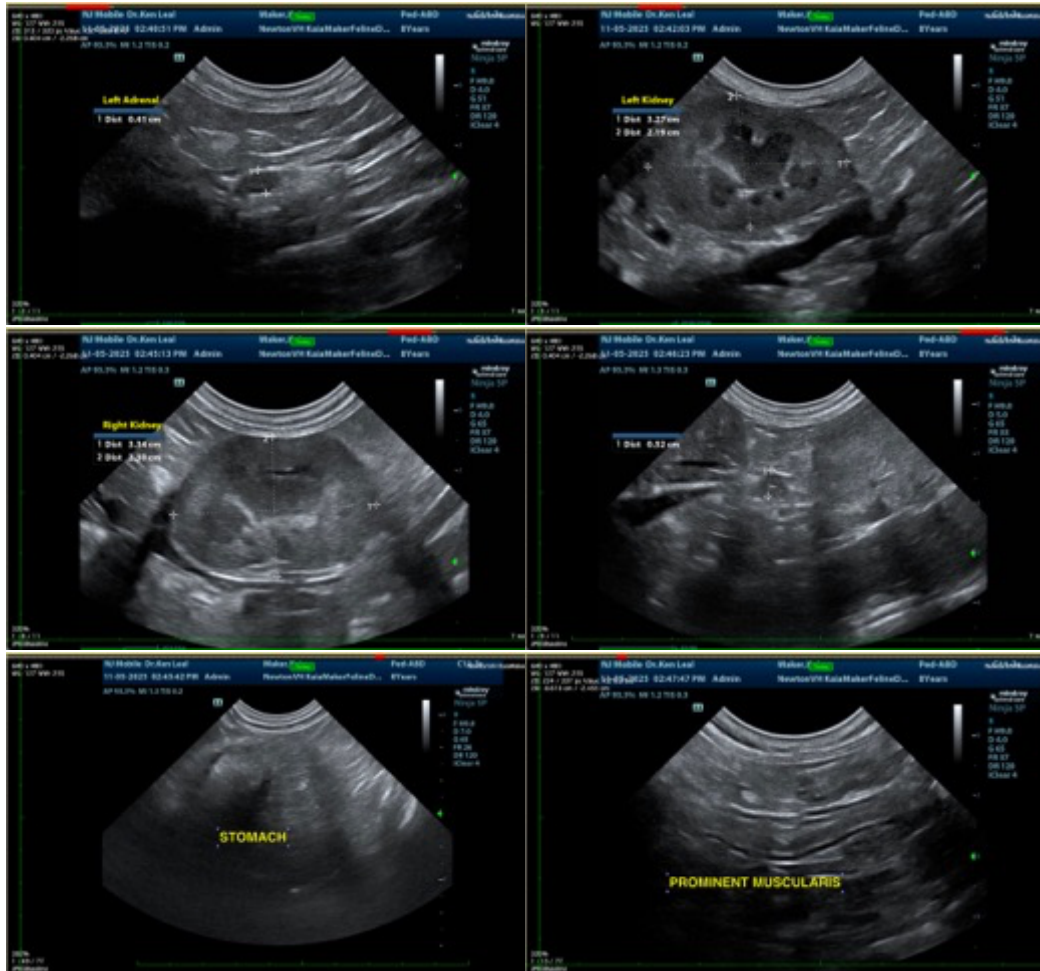
Dr. Collin Timony

INVOICE

10687

DATE

11/5/2025



The information and recommendations provided are based on the images presented by the referring veterinarian/sonographer. No evaluation can be communicated regarding pathology that was not visible in the image/video clips provided.

Thank you for this referral. If the clinical or image interpretation does not parallel your findings or if I can be of any further assistance please contact me.

Beth Johnson, DVM, DACVIM
 info@sonopath.com