



PATIENT

Bodrow Boogie
Shelnut

SPECIES

Canine

BREED

Beagle

SEX

Neutered Male

AGE

9 Years

WEIGHT

43.9 Pounds

INTERPRETED BY

Beth Johnson, DVM
DACVIM

IMAGING PERFORMED BY

Harold Mike Beard

HOSPITAL NAME

Animal Care VC

REFERRING VET

Dr. Patrick Spivey

INVOICE

35396

DATE

11/4/25

PRESENTING CLINICAL SIGNS

History: Diabetic. Acute episode of vomiting. Increase in liver enzymes. RDVM treats with IV fluids, Cerenia, Baytril and Metronidazole.

Abnormal PE/Chem/CBC/UA Results: Cranial abdominal pain. CBC, Chem, UA pending.

ULTRASONOGRAPHIC EXAMINATION OF THE ABDOMEN

Urinary System

Urinary bladder is adequately distended with anechoic contents. No masses, inflammatory changes, echogenic sediment or cystoliths are observed. The urinary bladder, trigone and visible pelvic urethra are normal in thickness with a smooth mucosal surface.

Prostate is normal in size, echotexture and echogenicity for a neutered male.

Left kidney is normal in size (6.5 cm), shape and echogenicity. It has smooth peripheral margination. There is a normal 1:3 cortex to medulla ratio with appropriate corticomedullary distinction. There is no evidence of pyelectasia, mineral or infarcts observed. A hyperechoic band parallel to the corticomedullary border is present.

Right kidney is normal in size (6.3 cm), shape and echogenicity. It has smooth peripheral margination. There is a normal 1:3 cortex to medulla ratio with appropriate corticomedullary distinction. There is no evidence of pyelectasia, mineral or infarcts observed. A hyperechoic band parallel to the corticomedullary border is present.

Adrenal Glands

The adrenal glands are unable to be visualized in these images.

Spleen

Spleen is subjectively normal in size with a normal smooth capsular contour. Parenchyma is appropriately finely textured and homogenous with normal echogenicity relative to surrounding tissue (hyperechoic to liver). No focal nodules or masses are observed. Multifocal mineral foci are noted. Splenic vasculature appears normal.

Liver

Liver is subjectively enlarged (swollen contour) without disruption of architecture. It has a normal homogenous echotexture. Parenchyma is diffusely hyperechoic characterized by less prominent than normal portal vein walls and increased echogenicity relative to the spleen and falciform fat. No focal lesions are observed. Visible vasculature and biliary tree appear normal without distension or congestion.

Gallbladder is mildly overdistended with a moderate amount of non-dependent, mildly aggregated/inspissated sludge. Hypo to anechoic cystic areas are noted between the gallbladder sludge and luminal wall. The wall is otherwise smooth without visible thickening. There is no evidence of cystic or CBD dilation. There is no evidence of effusion.

Gastrointestinal



PATIENT

Bodrow Boogie
Shelnut

SPECIES

Canine

BREED

Beagle

SEX

Neutered Male

AGE

9 Years

WEIGHT

43.9 Pounds

INTERPRETED BY

Beth Johnson, DVM
DACVIM

IMAGING PERFORMED BY

Harold Mike Beard

HOSPITAL NAME

Animal Care VC

REFERRING VET

Dr. Patrick Spivey

INVOICE

35396

DATE

11/4/25

The visible stomach wall is normal in thickness and layering. The lumen of the stomach is empty with no evidence of obstruction, foreign material or infiltrative disease. Pyloric outflow tract appears patent.

The visible small intestines are normal in wall thickness and layering. Small intestinal motility appears adequate (1-3 contractions per min). The lumen of the small intestine is empty with no evidence of obstruction, foreign material or infiltrative disease.

The visible colon is normal in wall thickness (< 0.2 cm) and layering. Contents are consistent with normal formed feces and gas.

Pancreas

The observed pancreas is prominent (enlarged) in size, hypoechoic to surrounding tissue and irregular in shape with a swollen undulating contour. Enhanced hyperechoic ill-defined surrounding fat is noted. This change is subtle/mild and primarily determined by some enhanced hyperechoic mesenteric fat just caudal to the stomach.

Free Abdomen

There is no visible free peritoneal effusion noted in these images.

There is no apparent pathologic lymphadenopathy noted in these images.

ULTRASONOGRAPHIC FINDINGS

- Suspect mild to moderate or potentially emerging acute pancreatitis
- Emerging gallbladder mucocele- Cholecystic debris is of unknown clinical significance. It can be seen with biliary stasis from fasting or illness. Cholecystic debris is not necessarily related to hepatobiliary disease. The non-dependent nature of this sludge combined with the cystic areas are suggestive, however, of possible emerging cystic mucosal hyperplasia or early gallbladder mucocele.
- Hyperechoic hepatomegaly- This appearance is non-specific and most consistent with a benign steroid (endocrine) or vacuolar hepatopathy or reactive or idiopathic hepatopathy. Inflammatory and/or infiltrative disease (such as round cell neoplasia) are also possible, but considered less likely.
- Bilaterally medullary rim sign- This finding is of unknown clinical significance and can be a normal variant, often idiopathic. Medullary rim sign can be present with renal disease including lymphoma, hypercalcemic nephropathy, Leptospirosis, tubular disease, other and should be interpreted in combination with other more specific indications of kidney disease such as isosthenuria, proteinuria, azotemia, etc. This is a common incidental finding in patients with diabetes mellitus.
- Spleen mineralization- This is a benign change but can be associated with endocrinopathies, especially hyperadrenocorticism.

INTERPRETATION OF THE FINDINGS & FURTHER RECOMMENDATIONS



PATIENT

Bodrow Boogie
Shelnut

SPECIES

Canine

BREED

Beagle

SEX

Neutered Male

AGE

9 Years

WEIGHT

43.9 Pounds

INTERPRETED BY

Beth Johnson, DVM
DACVIM

IMAGING PERFORMED BY

Harold Mike Beard

HOSPITAL NAME

Animal Care VC

REFERRING VET

Dr. Patrick Spivey

INVOICE

35396

DATE

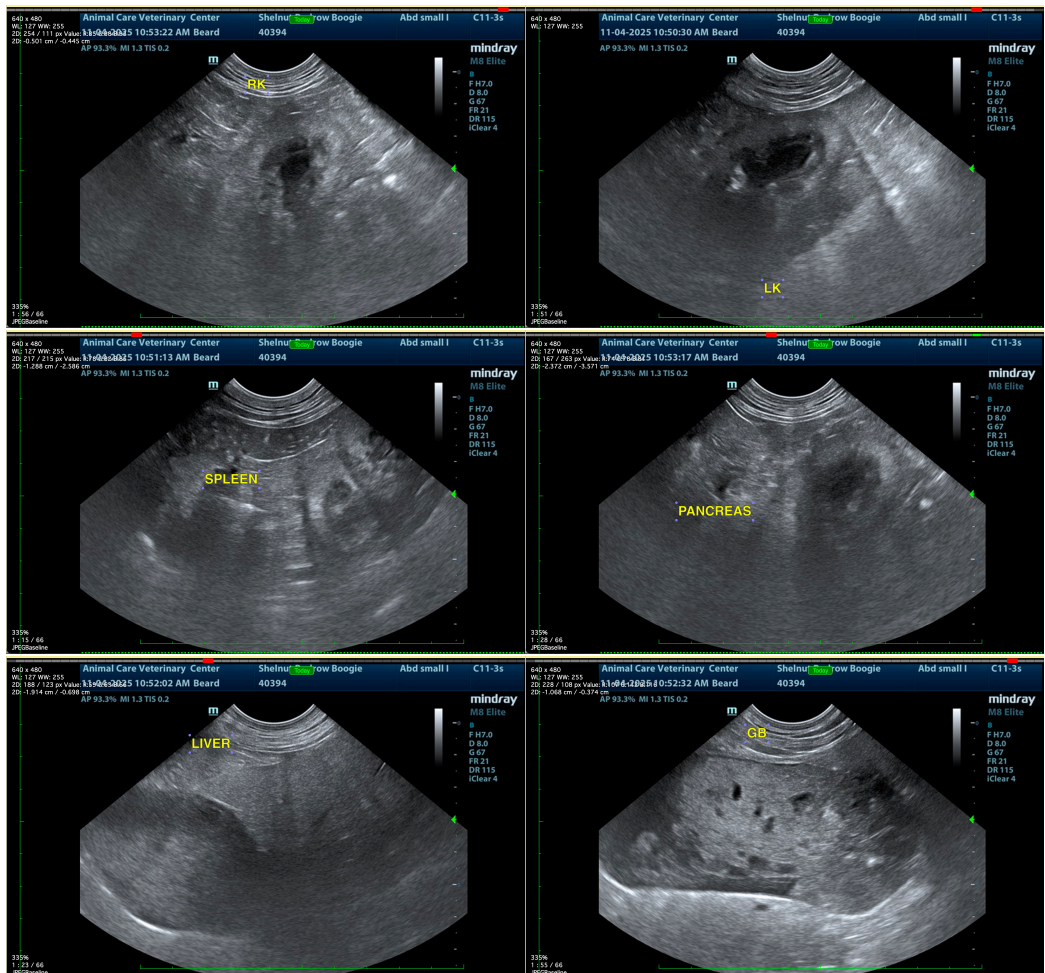
11/4/25

As is reportedly already pending, a full general metabolic health screen is recommended in the form of CBC, chemistry panel, electrolytes, and urinalysis, and if indicated based on urinalysis results, urine culture is recommended. If protein is present in an otherwise quiet sediment, protein quantification with a urine protein to creatinine ration is recommended.

A gastrointestinal malabsorption panel (including cobalamin, folate, TLI and PLI) to Texas A&M GI Laboratory is recommended for further evaluation of GI and pancreatic function.

In the meantime, medical management of pancreatitis with anti-emetics, gastroprotectants, appetite stimulants or nutritional support as needed, pain management, broad spectrum antibiotics, and fluid therapy is recommended. Monitoring of the pancreas with power doppler is recommended to identify possible necrosis as well as other potential sequelae such as abscesses, etc.

Further treatment, etc., of the emerging gallbladder mucocele is largely dependent on patient's labwork changes, ongoing clinical signs or lack thereof, following resolution of the suspected pancreatitis, any possible other concurrent endocrinopathies, etc.





PATIENT

Bodrow Boogie
Shelnut

SPECIES

Canine

BREED

Beagle

SEX

Neutered Male

AGE

9 Years

WEIGHT

43.9 Pounds

INTERPRETED BY

Beth Johnson, DVM
DACVIM

IMAGING PERFORMED BY

Harold Mike Beard

HOSPITAL NAME

Animal Care VC

REFERRING VET

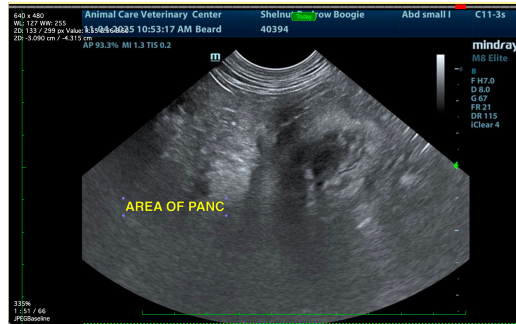
Dr. Patrick Spivey

INVOICE

35396

DATE

11/4/25



The information and recommendations provided are based on the images presented by the referring veterinarian/sonographer. No evaluation can be communicated regarding pathology that was not visible in the image/video clips provided.

Thank you for this referral. If the clinical or image interpretation does not parallel your findings or if I can be of any further assistance please contact me.

Beth Johnson, DVM DACVIM

info@sonopath.com