

**DATE PRESENTING CLINICAL SIGNS**

11/4/22

10/31/2022 Went to RDVM "Came in with temp of 104. HCT 12%. 4dx negative. Called o and discussed concerns and referral to ER for blood transfusion due to time of day. Explained 12% is definitely at level of blood transfusion and hospitalization to get values up. Discussed unknown cause at this point for anemia but suggestive of IMHA due to temp etc. o declines referral at this point and would prefer to try conservative management. Advised o that while this is doable I am worried about prognosis and death without transfusion. Gave 0.4mg/kg dose of Dex SP IV and started on Norm R IV fluids at 1.5 maintenance dispensed Pred PO 20mg q12h sent scripts to wedgewood for aziathioprine and clopridgel advised o to use melatonin scheduled recheck for Wed" At recheck PCV was 8% Non-regenerative anemia referral for transfusion and continued care

PATIENT

Xena McKinney

SPECIES

Canine

BREED

Mixed

SEX

Spayed Female

AGE

11/16/16

WEIGHT

25 Pounds

INTERPRETED BYBeth Johnson, DVM
DACVIM**IMAGING PERFORMED BY**

Rachel Brilhart RDMS

HOSPITAL NAMEAnimal Emergency
Hospital**REFERRING VET**

Dr. Ruby

INVOICE

42548

Current Medications: Omeprazole, Prednisone, Cerenia, Azathioprine, Melatonin.
Lab Results: PCV 8 @ presentation; up to 21 after 2 transfusions
Date of Previous IntraPet Ultrasound: No previous.
Sedation: Not required to complete full diagnostic ultrasound.
Stat Report: STAT requested.

ULTRASONOGRAPHIC EXAMINATION OF THE ABDOMEN**Urinary System**

The urinary bladder is moderately distended with anechoic contents. No masses, inflammatory changes, echogenic sediment or cystoliths are observed. The urinary bladder, trigone and visible pelvic urethra are normal in thickness with a smooth mucosal surface.

The right kidney is normal in size (5.67 cm), shape and echogenicity. It has smooth peripheral margination. There is a normal 1:3 cortex to medulla ratio with appropriate corticomedullary distinction. There is no evidence of pyelectasia, mineral or infarcts observed.

The left kidney is normal in size (5.1 cm), shape and echogenicity. It has smooth peripheral margination. There is a normal 1:3 cortex to medulla ratio with appropriate corticomedullary distinction. There is no evidence of pyelectasia, mineral or infarcts observed.

Adrenal Glands

The right adrenal gland is normal in size (1.91 cm long x 0.58 cm at the cranial pole and 0.56 cm at the caudal pole), shape and contour. Corticomedullary structure is unremarkable. Visible surrounding vasculature appears normal.

The left adrenal gland is normal in size (1.74 cm long x 0.53 cm at the cranial pole and 0.56 cm at the caudal pole), shape and contour. Corticomedullary structure is unremarkable. Visible surrounding vasculature appears normal.

Spleen

Spleen is subjectively large in size with normal smooth margins. Parenchyma is normal in echogenicity with a coarse/heterogenous echotexture. No focal nodules or masses are observed. Splenic vasculature appears normal.

Liver

Liver is subjectively enlarged (swollen contour). Mild parenchymal remodeling with diffusely mildly coarse architecture and increased portal markings is present. No focal nodules or masses are observed. Visible vasculature and biliary tree appear normal without distension or congestion.

Gallbladder is moderately distended with anechoic bile as well as suspended and gravity dependent echogenic debris. The wall is smooth without visible thickening. There is no evidence of cystic or CBD dilation. There is no evidence of effusion or inflammation. A “halo sign” or double gallbladder wall is noted around the gallbladder.

Gastrointestinal

The visible stomach wall is normal in thickness and layering. The lumen of the stomach is mildly distended with very echogenic reverberation artifact from intraluminal gas. There is no evidence of obstruction, foreign material or infiltrative disease; however, complete visualization of far wall is partially inhibited by gas. Pyloric outflow tract appears patent.

The visible small intestines are normal in wall thickness and layering (canine duodenum < 0.5 cm and feline duodenum < 0.4 cm; other < 0.3 cm). Small intestinal motility appears adequate (1-3 contractions per min). The lumen of the small intestine is empty with no evidence of obstruction, foreign material or infiltrative disease.

The visible colon is normal in wall thickness (< 0.2 cm) and layering. Contents are consistent with normal formed feces and gas.

Pancreas

The pancreatic parenchyma is appropriately isoechoic to surrounding tissue. Visible capsule is smooth and normal in contour. There is no visible pancreatic duct dilation. There is no evidence of active peripancreatic inflammation.

Free Abdomen

A scant amount of anechoic free fluid is noted.

A prominent, hypoechoic portal lymph node is noted, measuring 3.0 cm long x 1.36 cm wide.

PRIMARY FINDINGS

- **Coarse splenomegaly** – can be associated with congestion caused by sedation (if sedated) but can also be associated with diffuse infiltrative disease. Both benign conditions such as extramedullary hematopoiesis, lymphoid hyperplasia, as well as infiltrative neoplastic diseases such as round cell neoplasia should be considered.
- **Hypoechoic hepatomegaly** – This appearance is consistent with an acute hepatopathy or acute cholangiohepatitis. Infiltrative neoplasia (round cell neoplasia) should also be considered.
- Reactive portal lymph node

SECONDARY FINDINGS

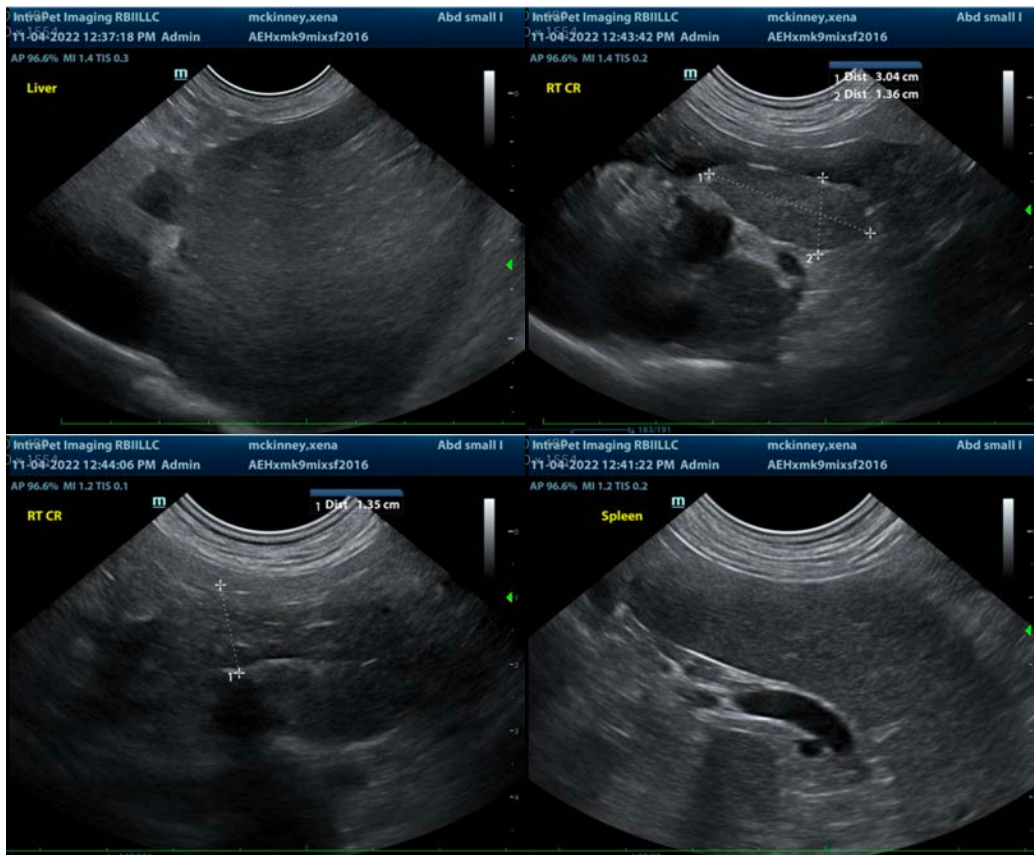
- **Gallbladder debris** - Cholecystic debris is of unknown clinical significance. It can be seen with biliary stasis from fasting or illness. Cholecystic debris is not necessarily related to hepatobiliary disease. Echogenic bile is most commonly an incidental finding in dogs and should be interpreted in combination with clinical signs such as nausea, inappetence, cranial abdominal discomfort and/or laboratory changes such as increased ALP and/or increased Tbili.
- **Double gallbladder wall or halo sign** – This is a relatively non-specific finding and can be seen with immune mediated disease, as is suspected in this patient.
- Chronic active pancreatitis

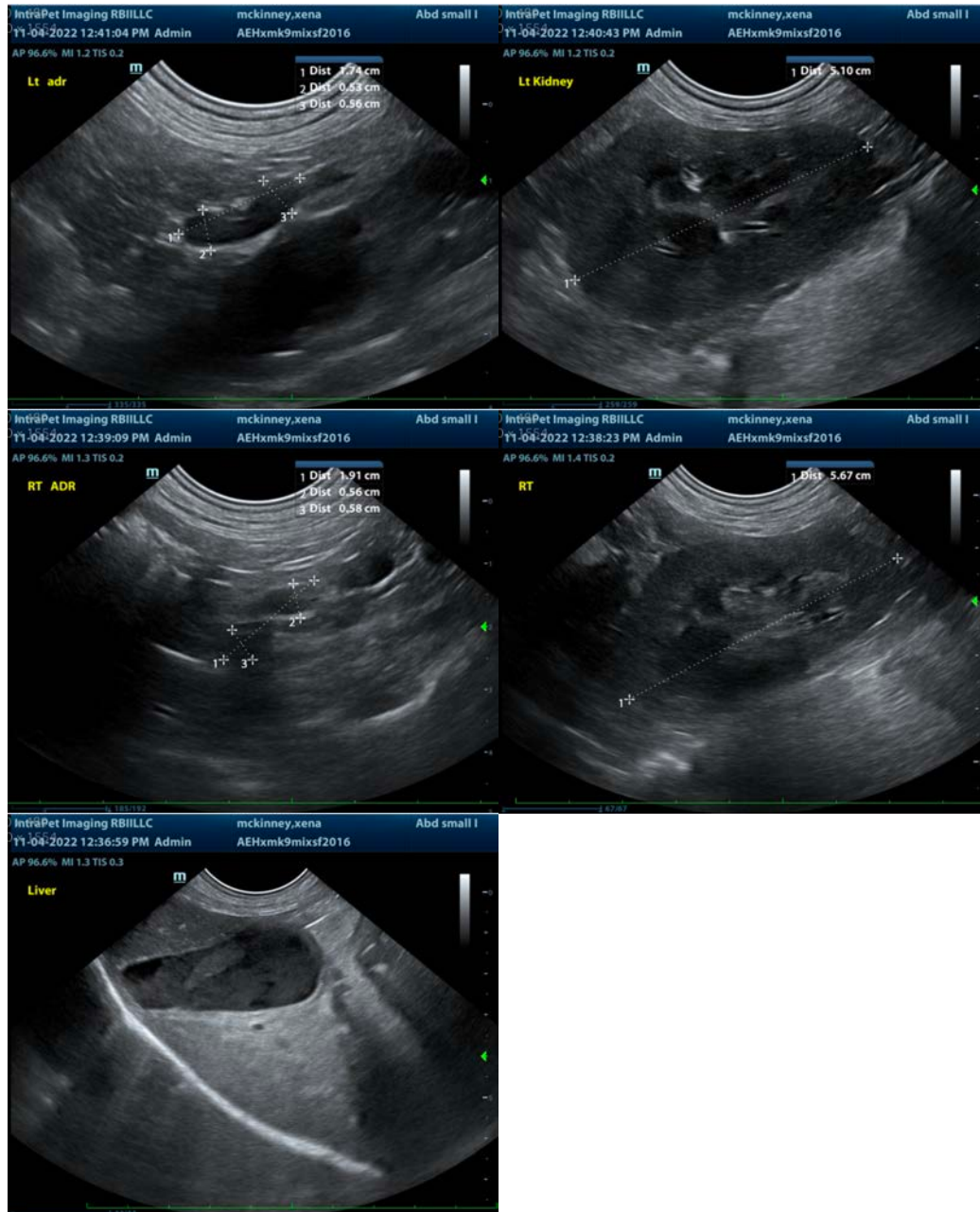
INTERPRETATION OF THE FINDINGS & FURTHER RECOMMENDATIONS

Given this patient's anemia and reported clinical jaundice, hemolysis is a likely scenario with an autoimmune component being probable. The reported non-regenerative state could be early hemolysis that just hasn't had time to regenerate yet or could be indicative of primary bone marrow pathology. While the ultrasound changes in general trend toward the benign, the hepatic and portal lymph node changes are slightly atypical with primary immune mediated hemolytic anemia. Therefore, if the patient is stable and coagulation status is appropriate, part of the workup could include a fine needle aspirate of the liver and the enlarged portal lymph node if possible. Otherwise, recommendations include a pathology review of the CBC, potentially a bone marrow cytology if the anemia remains non-regenerative, and a comprehensive infectious disease workup, potentially including Leptospirosis, given the liver changes.

In the meantime, continued therapy of the presumed autoimmune hemolytic anemia is recommended in addition to blood transfusions as needed for patient support.

If fine needle aspirates are not elected at this time, alternatively, recheck imaging could be performed after therapy, pending patient response.





The information and recommendations provided are based on the images presented by the referring veterinarian/sonographer. No evaluation can be communicated regarding pathology that was not visible in the image/video clips provided.

Thank you for this referral. If the clinical or image interpretation does not parallel your findings or if I can be of any further assistance please contact me.

Beth Johnson, DVM, DACVIM
Beth.Johnson@sonopath.com