



PATIENT

Amelie Cooper

SPECIES

Feline

BREED

DSH

SEX

Spayed Female

AGE

9 years

WEIGHT

8.1 lbs

INTERPRETED BY

Beth Johnson, DVM
DACVIM

IMAGING PERFORMED BY

Dr. Jessica Boudreaux-
Milligan

HOSPITAL NAME

Dockside Veterinary
Imaging

REFERRING VET

Dr. Dawn Morgan-
Winter

INVOICE

10676

DATE

11/03/2025

PRESENTING CLINICAL SIGNS

Gradual weight loss, normal labs to date. Recently frequently vomiting.

Abnormal PE/Chem/CBC/UA Results: Please see attached labs.

ULTRASONOGRAPHIC EXAMINATION OF THE ABDOMEN

Urinary System

Urinary bladder is adequately distended. It has a normal uniform wall thickness. Contents include primarily anechoic fluid with a large amount of echogenic non-shadowing debris, most consistent with exfoliated cells, crystals, mucous and/or small blood clots likely combined with incidental suspended lipid. Both sterile inflammation as well as urinary tract infection can present with echogenic debris. No masses or definitive cystoliths are observed. The trigone and visible pelvic urethra are normal in thickness with a smooth mucosal surface.

The right kidney is normal in size (3.53 cm), shape and echogenicity. It has smooth peripheral margination. There is a normal 1:3 cortex to medulla ratio with appropriate corticomedullary distinction. There is no evidence of pyelectasia, mineral or infarcts observed.

The left kidney is normal in size (3.41 cm), shape and echogenicity. It has smooth peripheral margination. There is a normal 1:3 cortex to medulla ratio with appropriate corticomedullary distinction. There is no evidence of pyelectasia, mineral or infarcts observed.

Adrenal Glands

The right adrenal gland is normal in size (0.33 cm), shape and overall architecture, echogenicity and echotexture. Visible surrounding vasculature appears normal.

The left adrenal gland is normal in size (0.29 cm), shape and overall architecture, echogenicity and echotexture. Visible surrounding vasculature appears normal.

Spleen

The spleen is subjectively normal in size with a normal smooth capsular contour. Parenchyma is appropriately finely textured and homogenous with normal echogenicity relative to surrounding tissue (hyperechoic to liver). No focal nodules or masses are observed. Splenic vasculature appears normal.

Liver

Liver is subjectively enlarged (swollen contour) with a diffusely mildly coarse architecture and subtly increased portal markings. Mildly mixed echogenic changes are noted diffusely. No focal lesions are observed. Visible vasculature and biliary tree appear normal without distension or congestion.

The gallbladder is non-distended in size. The wall is smooth without visible thickening. Luminal contents are primarily anechoic. There is no evidence of cystic or common bile duct dilation.

Gastrointestinal

The visible stomach wall is normal in thickness and layering. The lumen of the stomach is empty with no evidence of obstruction, foreign material or infiltrative disease. Pyloric outflow tract appears patent.



PATIENT

Amelie Cooper

SPECIES

Feline

BREED

DSH

SEX

Spayed Female

AGE

9 years

WEIGHT

8.1 lbs

INTERPRETED BY

Beth Johnson, DVM
DACVIM

IMAGING PERFORMED BY

Dr. Jessica Boudreaux-
Milligan

HOSPITAL NAME

Dockside Veterinary
Imaging

REFERRING VET

Dr. Dawn Morgan-
Winter

INVOICE

10676

DATE

11/03/2025

The visible small intestine demonstrates areas of moderately thick muscularis layer relative to mucosa (disruption of the normal 1:3 muscularis:mucosa ratio). Small intestinal submucosa is slightly irregular, thick and hyperechoic, without evident loss of layering appreciated. The lumen of the small intestine is empty with no evidence of obstruction or foreign material.

The visible colon is normal in wall thickness (< 0.2 cm) and layering. Contents are consistent with normal formed feces and gas.

Pancreas

The pancreas that is observed appears appropriately isoechoic to surrounding omental fat. Visible capsule is smooth and normal in contour. Visible pancreatic parenchyma is homogenous and unremarkable. There is no visible pancreatic duct dilation. There is no evidence of active peripancreatic inflammation.

Free Abdomen

There is no visible free peritoneal effusion noted in these images.

There is no apparent pathologic lymphadenopathy noted in these images.

ULTRASONOGRAPHIC FINDINGS

- Moderate inflammatory bowel disease (IBD) pattern – Thick muscularis has been reported with infiltrative bowel disease including both benign inflammatory disease as well as infiltrative neoplasia such as lymphoma. No loss of layering, etc. is noted to make lymphoma more probable, but lymphoma cannot be definitively ruled out without tissue sampling.
- A large amount of echogenic urinary bladder debris.
- The liver changes are non-specific with normal patient variant unable to be ruled out but a microscopic hepatopathy such as bacterial or lymphoplasmacytic hepatitis, hepatic lipidosis, or even infiltrative neoplasia such as round cell neoplasia can't be ruled out without tissue sampling.

INTERPRETATION OF THE FINDINGS & FURTHER RECOMMENDATIONS

If not recently evaluated, a general metabolic health screen (CBC, chemistry panel with electrolytes and urinalysis) is recommended.

If not recently evaluated, a T4 +/- Free T4 is recommended.

A gastrointestinal malabsorption panel (including cobalamin, folate, TLI and PLI) to Texas A&M GI Laboratory is recommended for further evaluation of GI and pancreatic function.

Fine needle aspirates of the liver could be considered if patient's coagulation status is appropriate, but ultimately, if a cytologic diagnosis is unable to be obtained, biopsies of the GI tract, being sure to include ileum, if possible, may be necessary for a definitive diagnosis and therefore to further guide medical management.

Other than supportive/symptomatic medical management of clinical signs, further treatment recommendations are largely dependent on results of the above.



PATIENT

Amelie Cooper

SPECIES

Feline

BREED

DSH

SEX

Spayed Female

AGE

9 years

WEIGHT

8.1 lbs

INTERPRETED BY

Beth Johnson, DVM
DACVIM

IMAGING PERFORMED BY

Dr. Jessica Boudreaux-Milligan

HOSPITAL NAME

Dockside Veterinary Imaging

REFERRING VET

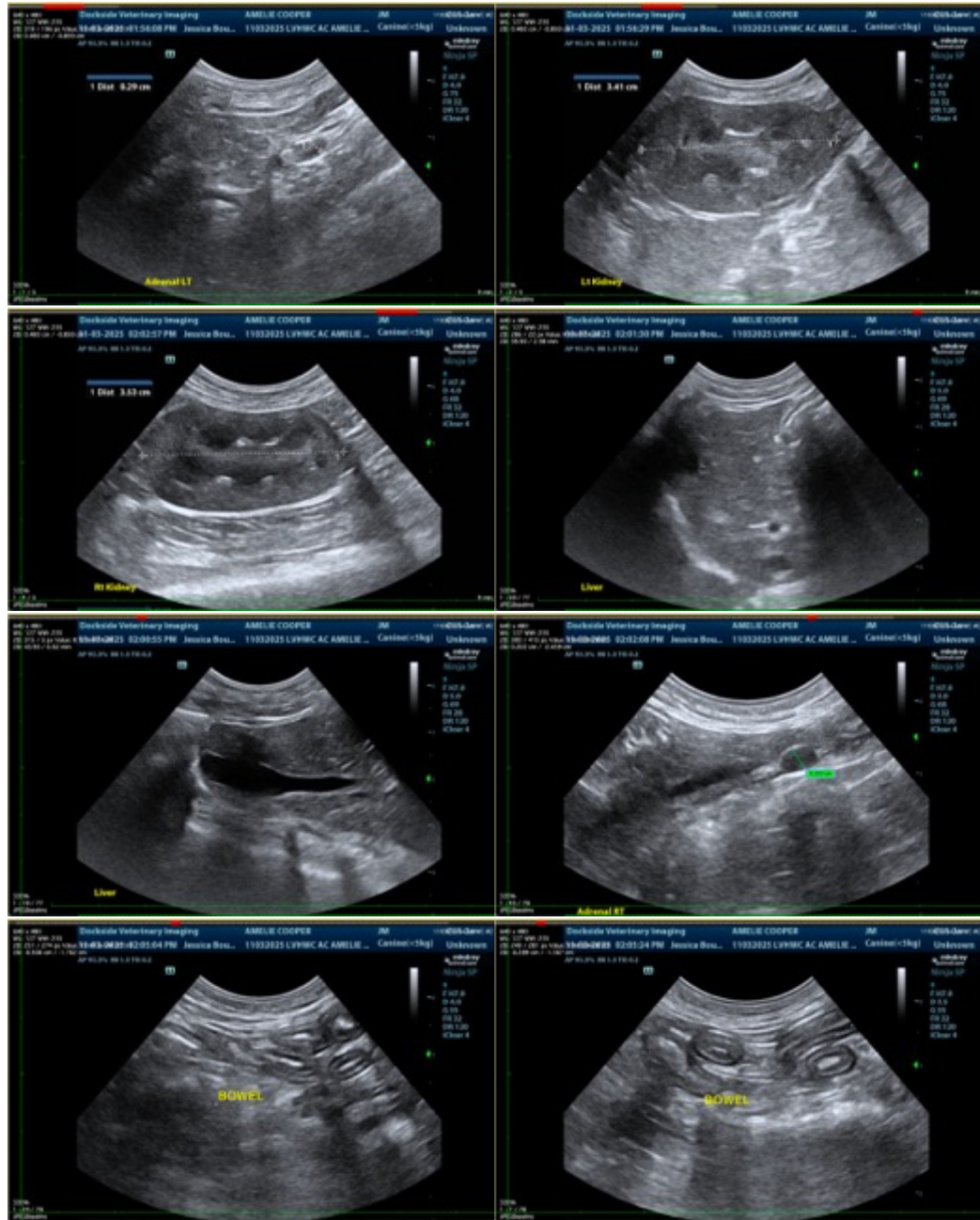
Dr. Dawn Morgan-Winter

INVOICE

10676

DATE

11/03/2025



The information and recommendations provided are based on the images presented by the referring veterinarian/sonographer. No evaluation can be communicated regarding pathology that was not visible in the image/video clips provided.

Thank you for this referral. If the clinical or image interpretation does not parallel your findings or if I can be of any further assistance please contact me.

Beth Johnson, DVM, DACVIM



PATIENT

info@sonopath.com

Amelie Cooper

SPECIES

Feline

BREED

DSH

SEX

Spayed Female

AGE

9 years

WEIGHT

8.1 lbs

INTERPRETED BY

Beth Johnson, DVM
DACVIM

IMAGING PERFORMED BY

Dr. Jessica Boudreaux-
Milligan

HOSPITAL NAME

Dockside Veterinary
Imaging

REFERRING VET

Dr. Dawn Morgan-
Winter

INVOICE

10676

DATE

11/03/2025