

**PATIENT**

BB Morenzetti

**SPECIES**

Canine

**BREED**

Brussels Griffon

**SEX**

Neutered Male

**AGE**

10 Years

**WEIGHT**

8.5 Pounds

**INTERPRETED BY**Beth Johnson, DVM  
DACVIM**IMAGING PERFORMED BY**

Amy Mayhew, LVT

**HOSPITAL NAME**

SVS Imaging MI

**REFERRING VET**Union Lake Vet  
Hospital**INVOICE**

42536

**DATE**

11/3/22

**PRESENTING CLINICAL SIGNS**

HX elevated ALP and HX pancreatitis, Currently Diarrhea (but improving) and increased water intake, Wt loss Most work-up so far has been with another vet- Banfield.

Abnormal PE/Chem/CBC/UA Results: Banfields records show ALP ~600. Our Spec cPLI from Idexx is 91(wnl). Owner declined rechecking chem/cbc- just done at Banfield. UA- random sample- SG 1.009 pH 7.0 No other sig findings. Banfield also has rad that they say are wnl.

**ULTRASONOGRAPHIC EXAMINATION OF THE ABDOMEN****Urinary System**

The urinary bladder is moderately distended with anechoic contents. No masses, inflammatory changes, echogenic sediment or cystoliths are observed. The urinary bladder, trigone and visible pelvic urethra are normal in thickness with a smooth mucosal surface.

Prostate is normal in size, echotexture and echogenicity for a neutered male.

The right kidney is normal in size (3.55 cm), shape and echogenicity. It has smooth peripheral margination. There is a normal 1:3 cortex to medulla ratio with appropriate corticomedullary distinction. There is no evidence of pyelectasia or infarcts observed. Tiny, non-obstructive areas of mineralization/nephroliths are noted.

The left kidney is normal in size (3.37 cm), shape and echogenicity. It has smooth peripheral margination. There is a normal 1:3 cortex to medulla ratio with appropriate corticomedullary distinction. There is no evidence of pyelectasia or infarcts observed. Tiny non-obstructive areas of mineralization/nephroliths are noted.

**Adrenal Glands**

The right adrenal gland is normal in size (0.37 cm at the cranial pole and 0.36 cm at the caudal pole), shape and contour. Corticomedullary structure is unremarkable. Visible surrounding vasculature appears normal.

The left adrenal gland is normal in size (0.35 cm at the cranial pole and 0.40 cm at the caudal pole), shape and contour. Corticomedullary structure is unremarkable. Visible surrounding vasculature appears normal.

**Spleen**

The spleen is subjectively normal in size with a normal smooth capsular contour. Parenchyma is appropriately finely textured and homogenous with normal echogenicity relative to surrounding tissue (hyperechoic to liver). No focal nodules or masses are observed. Splenic vasculature appears normal.

**Liver**

The liver is subjectively normal in size with normal smooth curvilinear peripheral contour. Parenchyma is appropriately hypochoic to the spleen in echogenicity and appropriately mildly coarse and homogenous in echotexture. No focal lesions are observed. Visible vasculature and biliary tree appear normal without distension or congestion.

Gallbladder is moderately distended with anechoic bile as well as suspended and gravity dependent echogenic debris. The wall is smooth without visible thickening. There is no evidence of cystic or CBD dilation. There is no evidence of effusion or inflammation.

**PATIENT**

BB Morenzetti

**SPECIES**

Canine

**BREED**

Brussels Griffon

**SEX**

Neutered Male

**AGE**

10 Years

**WEIGHT**

8.5 Pounds

**INTERPRETED BY**Beth Johnson, DVM  
DACVIM**IMAGING PERFORMED BY**

Amy Mayhew, LVT

**HOSPITAL NAME**

SVS Imaging MI

**REFERRING VET**Union Lake Vet  
Hospital**INVOICE**

42536

**DATE**

11/3/22

***Gastrointestinal***

The visible stomach wall is normal in thickness and layering. The lumen of the stomach is mildly distended with very echogenic reverberation artifact from intraluminal gas. There is no evidence of obstruction, foreign material or infiltrative disease; however, complete visualization of far wall is partially inhibited by gas. Pyloric outflow tract appears patent.

The visible small intestines are normal in wall thickness and layering. Hyperechoic mucosal fogging or speckling is noted. Small intestinal motility appears adequate (1-3 contractions per min). The lumen is empty with no evidence of obstruction or foreign material.

The visible colon is normal in wall thickness (< 0.2 cm) and layering. Contents are consistent with normal formed feces and gas.

***Pancreas***

The pancreatic parenchyma is appropriately isoechoic to surrounding tissue. Visible capsule is smooth and normal in contour. There is no visible pancreatic duct dilation. There is no evidence of active peripancreatic inflammation.

***Free Abdomen***

There is no evidence of free peritoneal effusion noted in these images.

A right iso- to slightly hypoechoic medial iliac lymph node is normal in shape, measuring 0.31 cm is visible.

**PRIMARY FINDINGS**

- **Mucosal speckling** – Mucosal speckling is often present with inflammatory bowel disease (IBD). It is not specific for type or severity of disease. Mild speckling change can occur as a normal patient variant in the post-prandial state.

**SECONDARY FINDINGS**

- **Gallbladder debris** - Cholecystic debris is of unknown clinical significance. It can be seen with biliary stasis from fasting or illness. Cholecystic debris is not necessarily related to hepatobiliary disease. Echogenic bile is most commonly an incidental finding in dogs and should be interpreted in combination with clinical signs such as nausea, inappetence, cranial abdominal discomfort and/or laboratory changes such as increased ALP and/or increased Tbili.
- Tiny non-obstructive nephroliths noted bilaterally

**INTERPRETATION OF THE FINDINGS & FURTHER RECOMMENDATIONS**

Given this patient's reported increased ALP and polyuria/polydipsia, hyperadrenocorticism certainly is a differential despite normal appearing adrenal glands. However, hyperadrenocorticism does not typically result in gastrointestinal signs and/or weight loss and should not be pursued in the face of concurrent illness due to the risk of false positives. Therefore, recommendations are to begin with a gastrointestinal workup, especially given the mucosal speckling, and, as is reportedly already planned, a gastrointestinal malabsorption panel (including cobalamin, folate, TLI and PLI) to Texas A&M GI Laboratory is recommended for further evaluation of GI and pancreatic function.

Additionally, a fecal exam +/- a fecal enteropathogen PCR panel to Texas A&M GI Laboratory could be considered for further evaluation of possible infectious disease, given the diarrhea.

In the meantime, empirical deworming with a 5-day course of Panacur, a probiotic such as Visbiome or Provable, and potentially a transition in diet based on trial-and-error response, beginning with a

**IMAGING PERFORMED BY**

SVS Mobile Imaging MI 734-637-7711  
svsimagingmi@gmail.com



EDUCATIONAL TELECONSULTATION SERVICES™  
1-800-838-4268 info@sonopath.com SonoPath.com

**PATIENT**

BB Morenzetti

**SPECIES**

Canine

**BREED**

Brussels Griffon

**SEX**

Neutered Male

**AGE**

10 Years

**WEIGHT**

8.5 Pounds

**INTERPRETED BY**

Beth Johnson, DVM  
DACVIM

**IMAGING PERFORMED BY**

Amy Mayhew, LVT

**HOSPITAL NAME**

SVS Imaging MI

**REFERRING VET**

Union Lake Vet  
Hospital

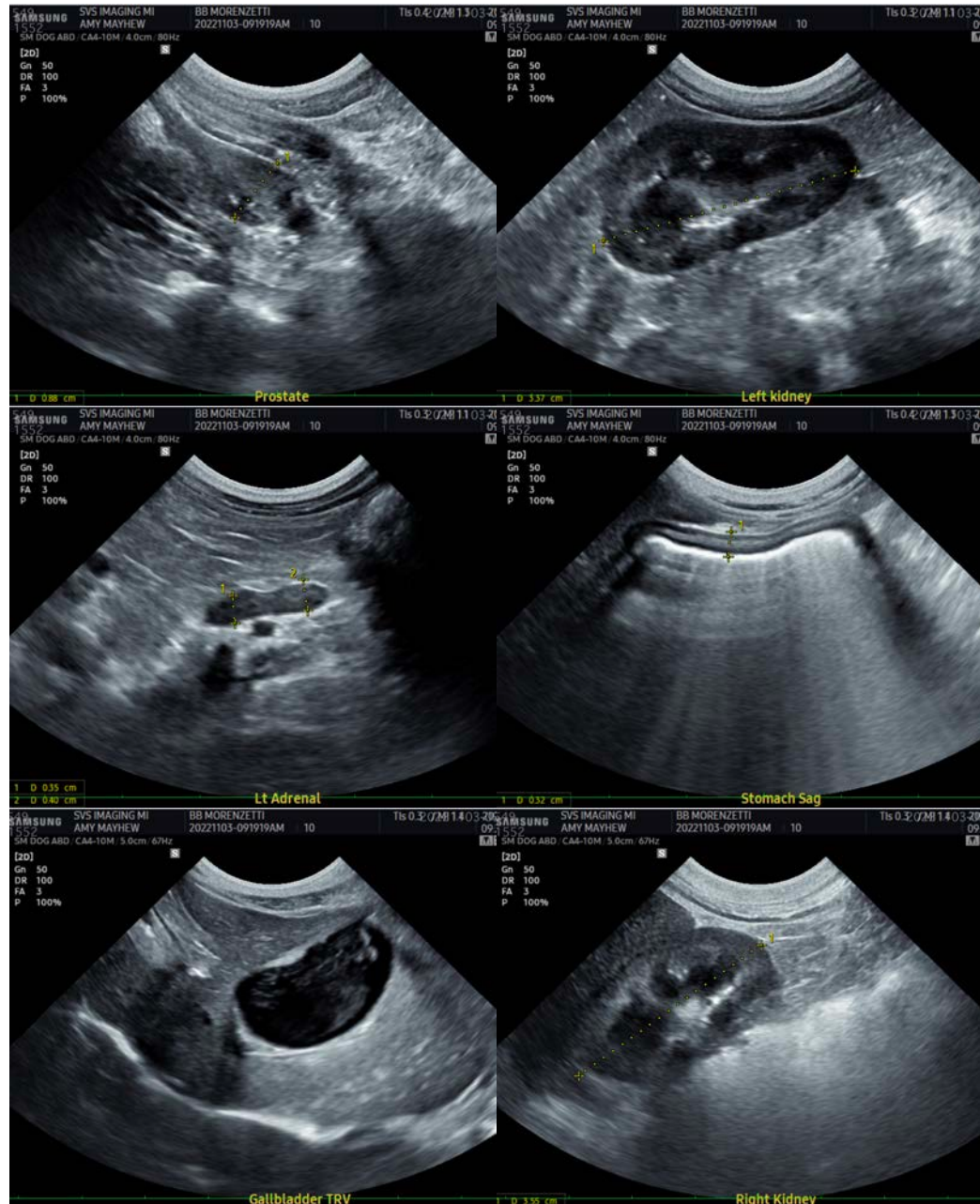
**INVOICE**

42536

**DATE**

11/3/22

hydrolyzed protein diet or potentially a low-fat diet could be considered with monitoring for improvement.



**IMAGING PERFORMED BY**

SVS Mobile Imaging MI 734-637-7711  
svsimagingmi@gmail.com



**PATIENT**

BB Morenzetti

**SPECIES**

Canine

**BREED**

Brussels Griffon

**SEX**

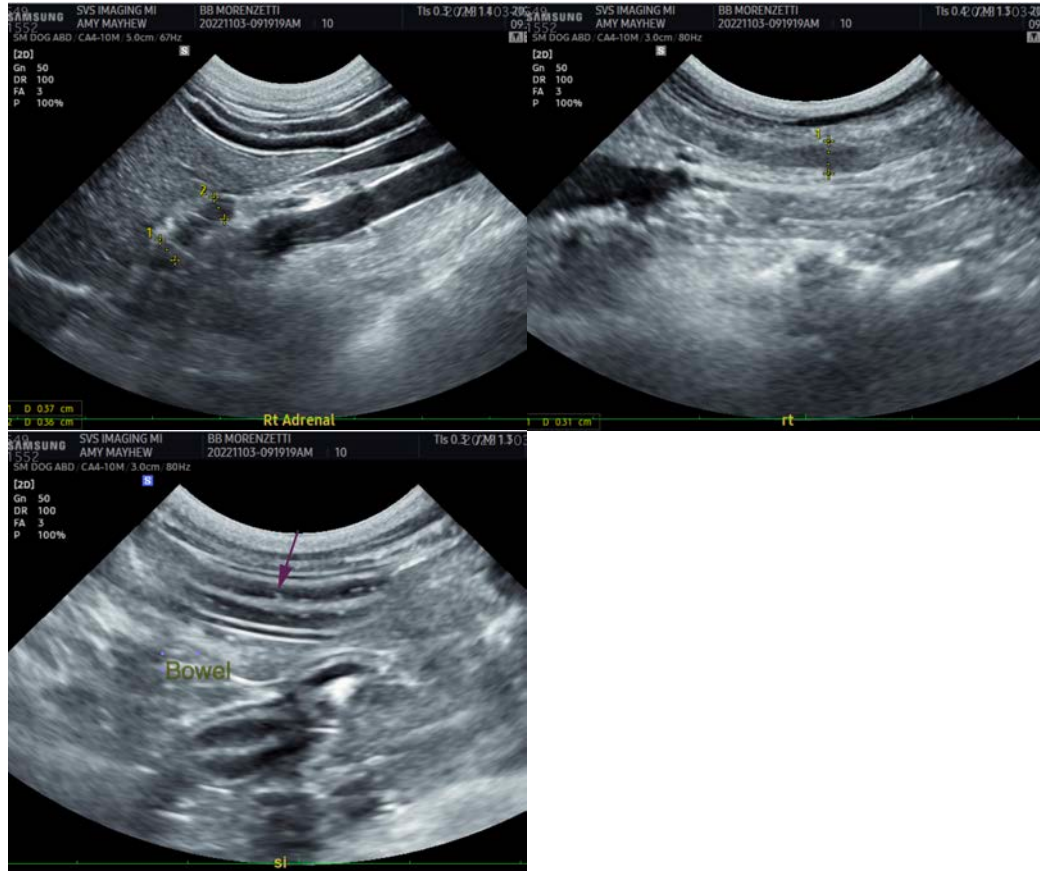
Neutered Male

**AGE**

10 Years

**WEIGHT**

8.5 Pounds



**INTERPRETED BY**

Beth Johnson, DVM  
DACVIM

**IMAGING PERFORMED BY**

Amy Mayhew, LVT

**HOSPITAL NAME**

SVS Imaging MI

**REFERRING VET**

Union Lake Vet  
Hospital

**INVOICE**

42536

**DATE**

11/3/22

The information and recommendations provided are based on the images presented by the referring veterinarian/sonographer. No evaluation can be communicated regarding pathology that was not visible in the image/video clips provided.

Thank you for this referral. If the clinical or image interpretation does not parallel your findings or if I can be of any further assistance please contact me.

**Beth Johnson, DVM, DACVIM**  
Beth.Johnson@sonopath.com