

**DATE PRESENTING CLINICAL SIGNS**

11/29/22

Weight loss BCS 1.5/5. 9/18/21 - 79lbs, 6/18/22 - 74.8lbs, 11/2/22 - 64.1lbs; concern p being under fed when o tried to get p to lose weight. increased calorie intake w/ no weight gain - started diarrhea.

**PATIENT**

Bentley Semanie

Current Medications: dermalone apply to AS BID for 10 days started 11/2/22  
 Lab Results: CBC/Chem = normal. u/a = increased protein - free catch sample  
 Date of Previous IntraPet Ultrasound: No previous.

**SPECIES**

Canine

Sedation: IV Butorphanol 3mg 0.3mL IV and Midazolam 3mg 0.6mL.

Stat Report: Not requested.

**BREED**

Boxer

**ULTRASONOGRAPHIC EXAMINATION OF THE ABDOMEN****Urinary System**

The urinary bladder is moderately distended with anechoic contents. No masses, inflammatory changes, echogenic sediment or cystoliths are observed. The urinary bladder, trigone and visible pelvic urethra are normal in thickness with a smooth mucosal surface.

**SEX**

Neutered Male

**AGE**

6/13/15

The area of the prostate is examined without evident pathology.

**WEIGHT**

63.6 Pounds

The right kidney is normal in size (5.89 cm), shape and echogenicity. It has smooth peripheral margination. There is a normal 1:3 cortex to medulla ratio with appropriate corticomedullary distinction. There is no evidence of pyelectasia, mineral or infarcts observed.

**INTERPRETED BY**Beth Johnson, DVM  
DACVIM

The left kidney is normal in size (7.04 cm), shape and echogenicity. It has smooth peripheral margination. There is a normal 1:3 cortex to medulla ratio with appropriate corticomedullary distinction. There is no evidence of pyelectasia, mineral or infarcts observed.

**IMAGING PERFORMED BY**

Rachel Brillhart RDMS

**Adrenal Glands**

The right adrenal gland is normal in size (2.1 cm long x 0.78 cm at the cranial pole and 0.79 cm at the caudal pole), shape and contour. Corticomedullary structure is unremarkable. Visible surrounding vasculature appears normal.

**HOSPITAL NAME**

Bel Air Vet

The left adrenal gland is normal in size (2.78 cm long x 0.62 cm at the cranial pole and 0.65 cm at the caudal pole), shape and contour. Corticomedullary structure is unremarkable. Visible surrounding vasculature appears normal.

**REFERRING VET**

Dr. Schmidt

**Spleen**

Spleen is generally normal in size and shape with a smooth capsular contour. Parenchyma is diffusely nodular in appearance characterized by small discrete hypoechoic nodules. Splenic vasculature appears normal.

**INVOICE**

43024

**Liver**

The liver is subjectively normal in size with normal smooth curvilinear peripheral contour. Parenchyma is appropriately hypoechoic to the spleen in echogenicity and appropriately mildly coarse and homogenous in echotexture. No focal lesions are observed. Visible vasculature and biliary tree appear normal without distension or congestion.

The gallbladder is non-distended in size. The wall is smooth without visible thickening. Luminal contents are primarily anechoic. There is no evidence of cystic or common bile duct dilation.

### ***Gastrointestinal***

The visible stomach wall is normal in thickness and layering. The lumen of the stomach is mildly distended with echogenic non-shadowing luminal contents and gas consistent with normal ingesta. There is no evidence of obstruction, foreign material or infiltrative disease. Pyloric outflow tract appears patent.

The visible small intestines are normal in wall thickness and layering. Small intestinal motility appears adequate (1-3 contractions per min). The lumen of the small intestine is mildly distended with echogenic non-shadowing luminal contents and gas consistent with normal ingesta. There is no evidence of obstruction, foreign material or infiltrative disease.

The visible colon is normal in wall thickness (< 0.2 cm) and layering. Contents are consistent with normal formed feces and gas.

### ***Pancreas***

The pancreatic parenchyma is appropriately isoechoic to surrounding tissue. Visible capsule is smooth and normal in contour. There is no visible pancreatic duct dilation. There is no evidence of active peripancreatic inflammation.

### ***Free Abdomen***

There is no evidence of free peritoneal effusion noted in these images.

Sublumbar lymphadenopathy is noted, example of node measures 2.3 cm long x 0.70 cm thick with a slightly hypoechoic appearance.

Hypoechoic mesenteric lymphadenopathy is also present, example of a node measures 2.84 cm long x 0.68 cm thick.

## **ULTRASONOGRAPHIC FINDINGS**

- **Reactive mesenteric and sublumbar lymph nodes** – infiltrative neoplastic disease cannot be ruled out but is considered less likely.
- **Splenic micronodular hyperplasia pattern** – This nodular change is often associated with benign aging nodular hyperplasia. Infiltrative neoplasia, however, including both early hemangiosarcoma as well as round cell neoplasia cannot be ruled out.

## **INTERPRETATION OF THE FINDINGS & FURTHER RECOMMENDATIONS**

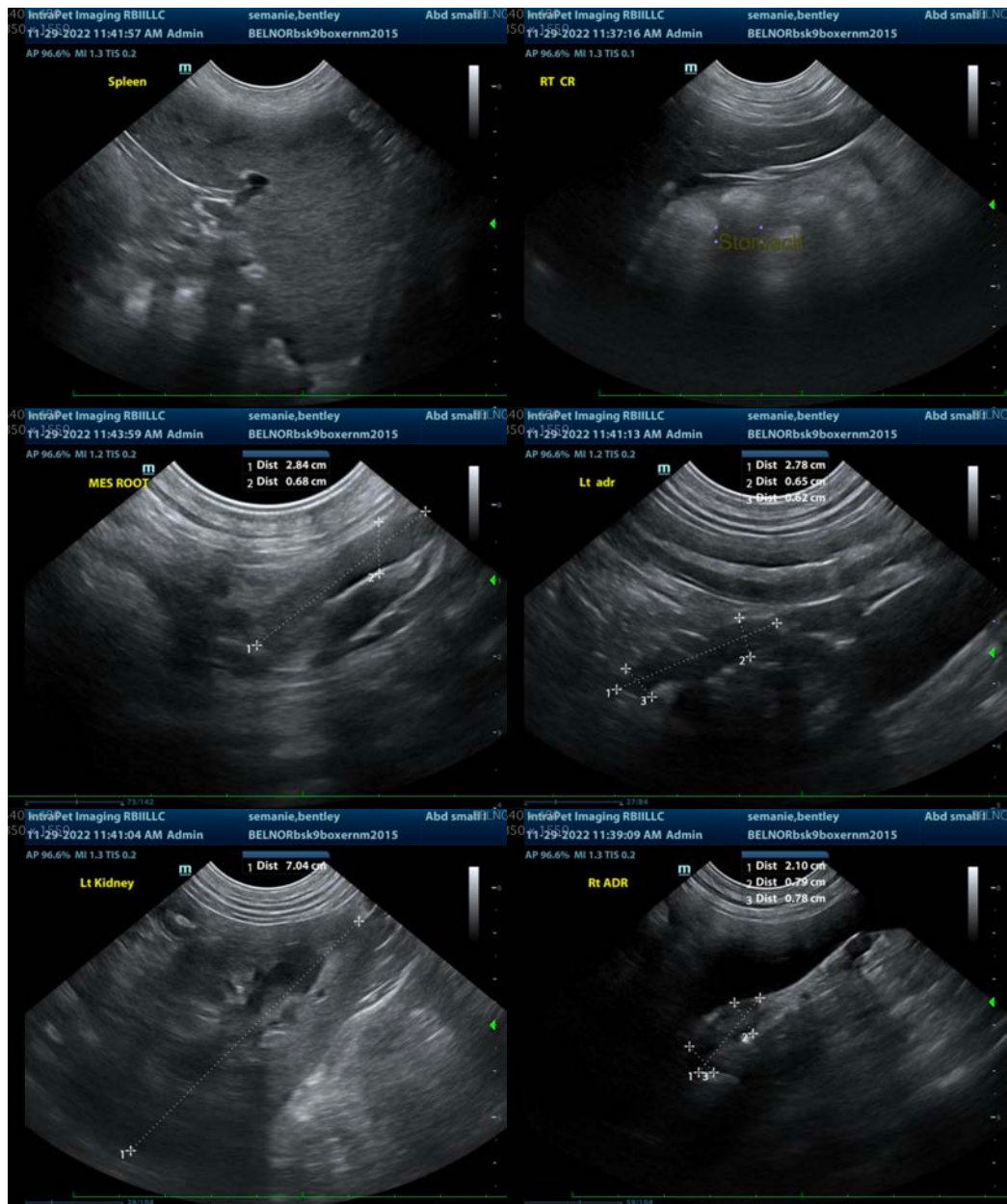
Given the sublumbar lymphadenopathy, if not already evaluated, a thorough rectal and perianal exam is recommended.

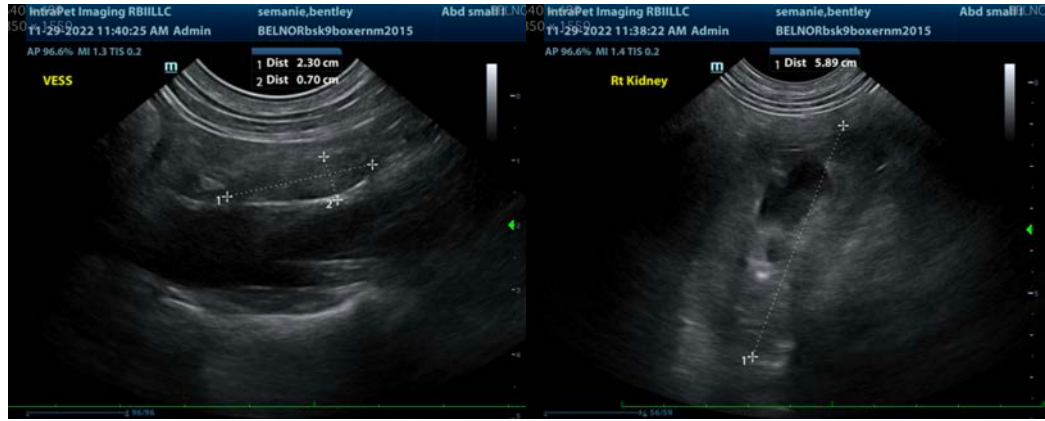
Given the reported proteinuria, urine protein to creatinine ratio is recommended to further quantify proteinuria to help determine whether or not proteinuria is a contributing factor to this patient's weight loss and requires treatment or not.

Given that this patient's weight loss began with an intentional caloric restriction with the goal of weight loss, reevaluating diet history thoroughly to ensure adequate caloric intake is recommended, and if patient is consuming adequate calories with continued weight loss or lack of weight gain, a gastrointestinal malabsorption panel (including cobalamin, folate, TLI and PLI) to Texas A&M GI Laboratory is recommended for further evaluation of GI and pancreatic function.

In the meantime, in addition to assessing caloric intake, empirical deworming with a 5-day course of Panacur is recommended.

While the lymph node and splenic changes trend toward benign, pending results of the previously recommended diagnostics, etc., if an underlying cause is not found and weight loss persists, fine needle aspirate of the enlarged lymph nodes as well as the spleen could be considered if patient's coagulation status is appropriate.





The information and recommendations provided are based on the images presented by the referring veterinarian/sonographer. No evaluation can be communicated regarding pathology that was not visible in the image/video clips provided.

Thank you for this referral. If the clinical or image interpretation does not parallel your findings or if I can be of any further assistance please contact me.

**Beth Johnson, DVM, DACVIM**  
Beth.Johnson@sonopath.com