

**DATE**

11/28/22

PRESENTING CLINICAL SIGNS

History: Long hx of hypercalcemia of unknown diagnosis. One month ago blood in urine. No straining and UA normal except for hematuria. Put on 7 day course of abx and went away. Came back several days ago. Still no pu/pd or stranguria.

PATIENT

Sweetie O'Meara

Current Medications: None listed.

Date of Previous IntraPet Ultrasound: No previous.

SPECIES

Canine

Sedation: Not required to complete full diagnostic ultrasound.

Stat Report: Not requested.

Imaging Performed By: Andi Parkinson, BS, RDMS.

BREEDAmerican
Staffordshire Terrier**ULTRASONOGRAPHIC EXAMINATION OF THE ABDOMEN****SEX**

Spayed Female

Urinary System

Urinary bladder is adequately distended. It has a normal uniform wall thickness. Contents include primarily anechoic fluid with occasional echogenic non-shadowing debris, including mineral debris/sand, most consistent with exfoliated cells, mucous and/or small blood clots. Small cystoliths cannot be ruled out. Both sterile inflammation as well as urinary tract infection can also present with echogenic debris. No masses or cystoliths are observed. The trigone and visible pelvic urethra are normal in thickness with a smooth mucosal surface.

AGE

4/26/09

Left kidney is normal in size (7.21 cm), shape and echogenicity. It has smooth peripheral margination. There is a normal 1:3 cortex to medulla ratio with appropriate corticomedullary distinction. There is no evidence of pyelectasia, or infarcts observed. Non-obstructive areas of mineralization/nephroliths are noted.

WEIGHT

40.4 Pounds

Right kidney is normal in size (5.23 cm), shape and echogenicity. It has smooth peripheral margination. There is a normal 1:3 cortex to medulla ratio with appropriate corticomedullary distinction. There is no evidence of pyelectasia, or infarcts observed. Non-obstructive areas of mineralization/nephroliths are noted.

INTERPRETED BYBeth Johnson, DVM
DACVIM**Adrenal Glands**

Left adrenal gland is normal in size (2.64 cm long x 0.92 cm at cranial pole and 0.7 cm at caudal pole), shape and overall architecture, echogenicity and echotexture. Visible surrounding vasculature appears normal.

HOSPITAL NAME

Healing Paws

Right adrenal gland is normal in size (2.77 cm long x 0.67 cm wide at the caudal pole), shape and overall architecture, echogenicity and echotexture. Visible surrounding vasculature appears normal.

REFERRING VET

Dr. Levitsky

Spleen

This patients spleen was previously removed.

INVOICE

18861

Liver

Liver is subjectively normal in size with normal smooth curvilinear peripheral contour. Parenchyma is appropriately hypoechoic to the spleen in echogenicity and appropriately mildly coarse and homogenous in echotexture. In the right caudal liver, there is a 5.7 cm x 9.0 cm heterogenous, primarily hypoechoic mass. A second smaller hypoechoic nodule/mass is present in the deeper right liver, measuring 3.0 cm x 2.7 cm in size.

Visible vasculature and biliary tree appear normal without distension or congestion.

Gallbladder is non-distended in size. The wall is smooth without visible thickening. Luminal contents are primarily anechoic. There is no evidence of cystic or common bile duct dilation.

Gastrointestinal

The visible stomach wall is normal in thickness and layering. The lumen of the stomach is empty with no evidence of obstruction, foreign material or infiltrative disease. Pyloric outflow tract appears patent. The visible small intestines are normal in wall thickness and layering. Small intestinal motility appears adequate (1-3 contractions per min). The lumen of the small intestine is empty with no evidence of obstruction, foreign material or infiltrative disease.

The visible colon is normal in wall thickness and layering. Contents are consistent with normal formed feces and gas.

Pancreas

The observed pancreas appears appropriately isoechoic to surrounding omental fat. Visible capsule is smooth and normal in contour. Visible pancreatic parenchyma is homogenous and unremarkable. There is no visible pancreatic duct dilation. There is no evidence of active peripancreatic inflammation.

Free Abdomen

There is no evidence of peritoneal effusion. There is no apparent lymphadenopathy.

ULTRASONOGRAPHIC FINDINGS

Primary Findings

- Two hypoechoic liver nodules/masses in the right liver, top differential for which is infiltrative neoplasia such as round cell neoplasia or potentially metastatic disease given this patients history. Benign lesions are considered possible but less likely.
- Urinary bladder debris, including mineral debris. Small cystoliths cannot be definitively ruled out.
- Nonobstructive nephrolithiasis bilaterally in the kidneys

Secondary Findings

- The spleen has been previously removed.

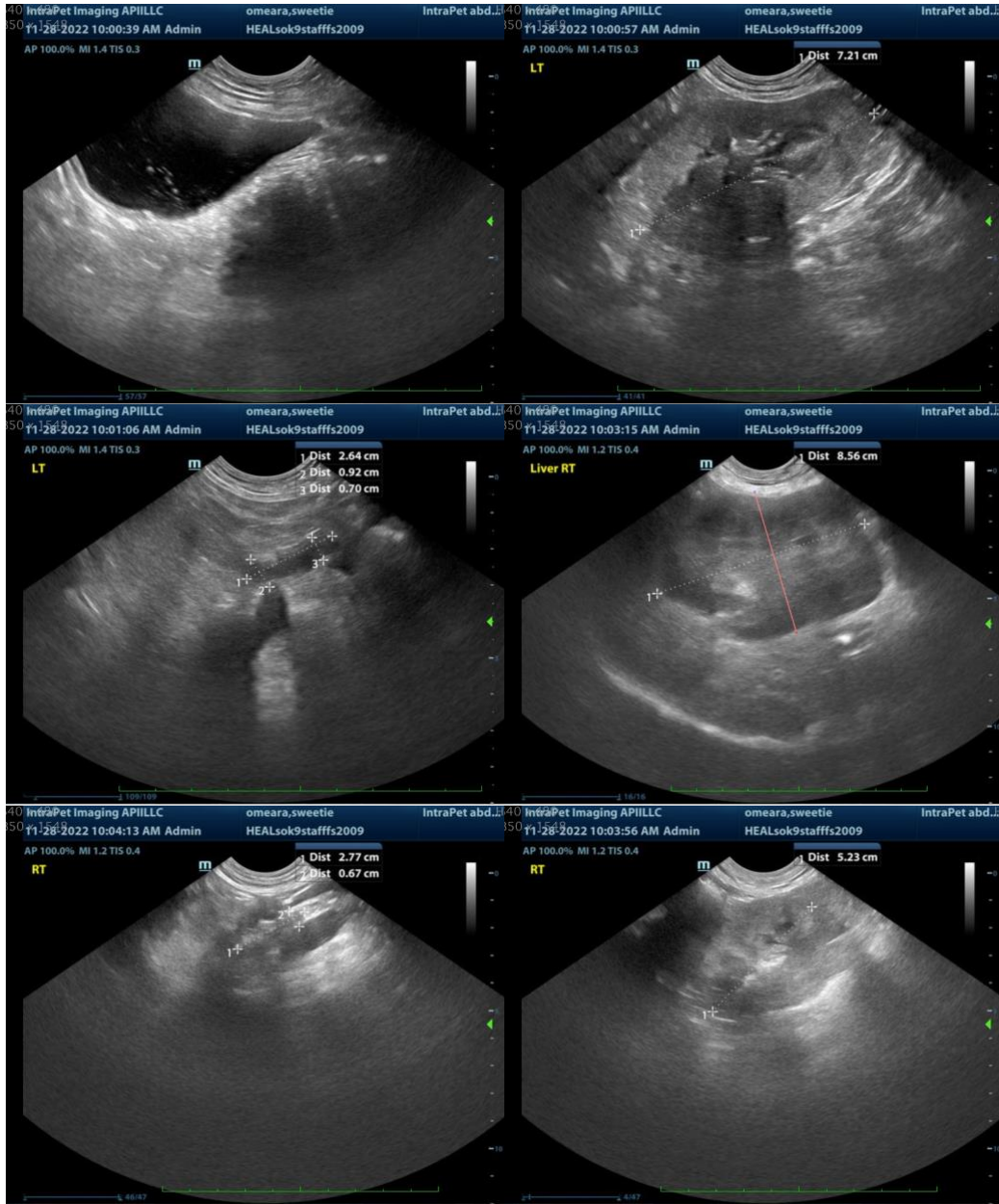
INTERPRETATION OF THE FINDINGS & FURTHER RECOMMENDATIONS

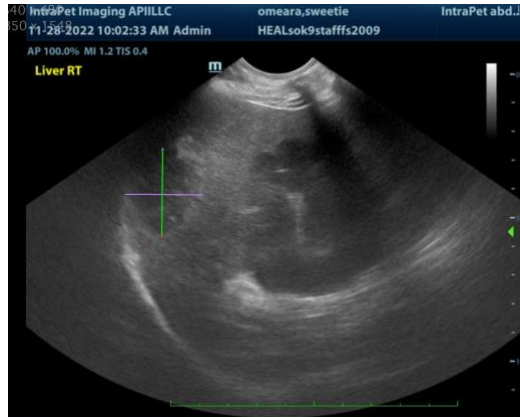Three view thoracic radiographs are recommended for further assessment of cardio-pulmonary status as well as to further evaluate for any evidence of metastatic disease, if not recently evaluated.

Further evaluation of this patients hypercalcemia is recommended, if not recently evaluated, in the form of a malignancy panel to include PTH, PTHrP and ionized calcium.

A fine needle aspirate of the liver masses is recommended if patients coagulation status is appropriate.

In the meantime, given the presenting complaint of lower urinary signs, combined with the reported improvement following a short course of antibiotics, follow up urinalysis and urine culture are recommended if it's been at least a week since finishing antibiotics, to determine if there is a recurrence of a possible urinary tract infection.





The information and recommendations provided are based on the images presented by the referring veterinarian. No evaluation can be communicated regarding pathology that was not visible in the image/video clips provided.

Thank you for this referral. If the clinical or image interpretation does not parallel your findings or if I can be of any further assistance please contact me.

Beth Johnson, DVM DACVIM
Beth.Johnson@SonoPath.com