

**DATE**

11/28/22

PRESENTING CLINICAL SIGNS

History: Patient had an elevated ALT and ALKP on bloodwork drawn on 11/14. Struvite crystals present on UA from 10/11 as well.

PATIENT

Ellie Evans

Current Medications: Clavamox 375mg 1 tablet PO BID x 14 days started on 10/11.

Lab Results: See attached.

Date of Previous IntraPet Ultrasound: No previous.

Sedation: Torbigesic.

Stat Report: Not requested.

Imaging Performed By: Stephanie Warga RDCS, RVT.

SPECIES

Canine

BREED

Golden Retriever Mix

ULTRASONOGRAPHIC EXAMINATION OF THE ABDOMEN**SEX**

Spayed Female

Urinary System

Urinary bladder is adequately distended. It has a normal uniform wall thickness. Contents include primarily anechoic fluid with occasional echogenic non-shadowing debris, most consistent with exfoliated cells, mucous and/or small blood clots. Both sterile inflammation as well as urinary tract infection can also present with echogenic debris. No masses or cystoliths are observed. The trigone is normal in thickness with a smooth mucosal surface. The proximal urethra is mildly distended with intraluminal mineral debris as well. The mineral contains a slightly irregular appearance making a mineralized urethral mass unable to be definitively ruled out.

AGE

10/30/07

Kidneys are overall normal in size and shape with smooth peripheral margination. A normal 1:3 cortex to medulla ratio is maintained. The medulla and cortices are uniform in texture with some mild increased cortical echogenicity and mild loss of corticomedullary distinction, expected in this age patient. There is no evidence of pyelectasia, mineral or infarcts observed. The left kidney measures 6.0 cm. The right kidney measures 5.66 cm.

WEIGHT

54 Pounds

Adrenal Glands

Left adrenal gland is normal in size (2.86 cm long x 0.64 cm at cranial pole and 1.1 cm at caudal pole), shape and overall architecture, echogenicity and echotexture. Visible surrounding vasculature appears normal. A hyperechoic nodule is noted in the caudal pole. Nodule does not disrupt normal shape and/or architecture.

INTERPRETED BYBeth Johnson, DVM
DACVIM

Right adrenal gland is normal in size (2.49 cm long x 0.99 cm at cranial pole and 0.64 cm at caudal pole), shape and overall architecture, echogenicity and echotexture. Visible surrounding vasculature appears normal.

HOSPITAL NAME

Lake Shore PH

Spleen

Spleen is subjectively large in size with subtly scalloped or undulating capsular contour. Parenchyma is normal in echogenicity with a mildly coarse/heterogenous echotexture. No focal nodules or masses are observed. Splenic vasculature appears normal.

REFERRING VET

Dr. Anderson

INVOICE

18857

Liver

Liver is subjectively normal in size with normal smooth curvilinear peripheral contour. Parenchyma is appropriately hypoechoic to the spleen in echogenicity and appropriately mildly coarse and homogenous in echotexture. A 6.5 cm x 6.7 cm heterogenous, primarily hyperechoic focal mass is noted in the left caudal liver. Visible vasculature and biliary tree appear normal without distension or congestion.

Gallbladder is non-distended in size. The wall is smooth without visible thickening. Luminal contents are primarily anechoic. There is no evidence of cystic or common bile duct dilation.

Gastrointestinal

The visible stomach wall is normal in thickness and layering. The lumen of the stomach is empty with no evidence of obstruction, foreign material or infiltrative disease. Pyloric outflow tract appears patent.

The visible small intestines are normal in wall thickness and layering. Small intestinal motility appears adequate (1-3 contractions per min). The lumen of the small intestine is empty with no evidence of obstruction, foreign material or infiltrative disease.

The visible colon is normal in wall thickness and layering. Contents are consistent with normal formed feces and gas.

Pancreas

The observed pancreas appears appropriately isoechoic to surrounding omental fat. Visible capsule is smooth and normal in contour. Visible pancreatic parenchyma is homogenous and unremarkable. There is no visible pancreatic duct dilation. There is no evidence of active peripancreatic inflammation.

Free Abdomen

There is no evidence of peritoneal effusion. There is no apparent lymphadenopathy. In the mid abdomen there is a 1.5 cm x 2.0 cm hypoechoic mass that appears to be associated with bowel, primary suspicion is large bowel near the ileocecolic junction.

ULTRASONOGRAPHIC FINDINGS

Primary Findings

- Mid abdominal mass suspected to be bowel in origin, with the top suspicion being colon, near the ileocecolic junction, differentials for which include infiltrative neoplasia such as adenocarcinoma versus possibly round cell neoplasia versus other.
- Heterogenous liver mass, differentials for which include infiltrative neoplasia such as a primary hepatocellular carcinoma versus sarcoma or round cell neoplasia or even metastatic disease. A benign hepatoma/adenoma, etc. is possible and cannot be differentiated without tissue sampling.
- Urinary bladder debris, including mineral debris within the lumen of the urethra, however, given the appearance of the mineral, a mineralized urethral mass such as carcinoma cannot be definitively ruled out.
- Scalloped spleen – can be associated with benign or malignant infiltrative disease. Common causes include a reactive spleen secondary to immune stimulus or early infiltrative round cell neoplasia such as lymphoma or mast cell tumor.

Secondary Findings

- Hyperechoic adrenal nodule in the caudal pole of the left adrenal gland – Differentials include primary adrenal cortical adenoma or adenocarcinoma, pheochromocytoma, myelolipoma, adrenal hyperplasia secondary to pituitary disease or metastatic disease. Ultrasound alone cannot differentiate between functional and non-functional nodules and/or between benign and malignant disease. Small nodules without other evidence of abdominal disease (to suggest metastatic disease) and/or clinical signs (to suggest adrenal disease) are most often incidental and should be monitored.

- Age-related kidney changes

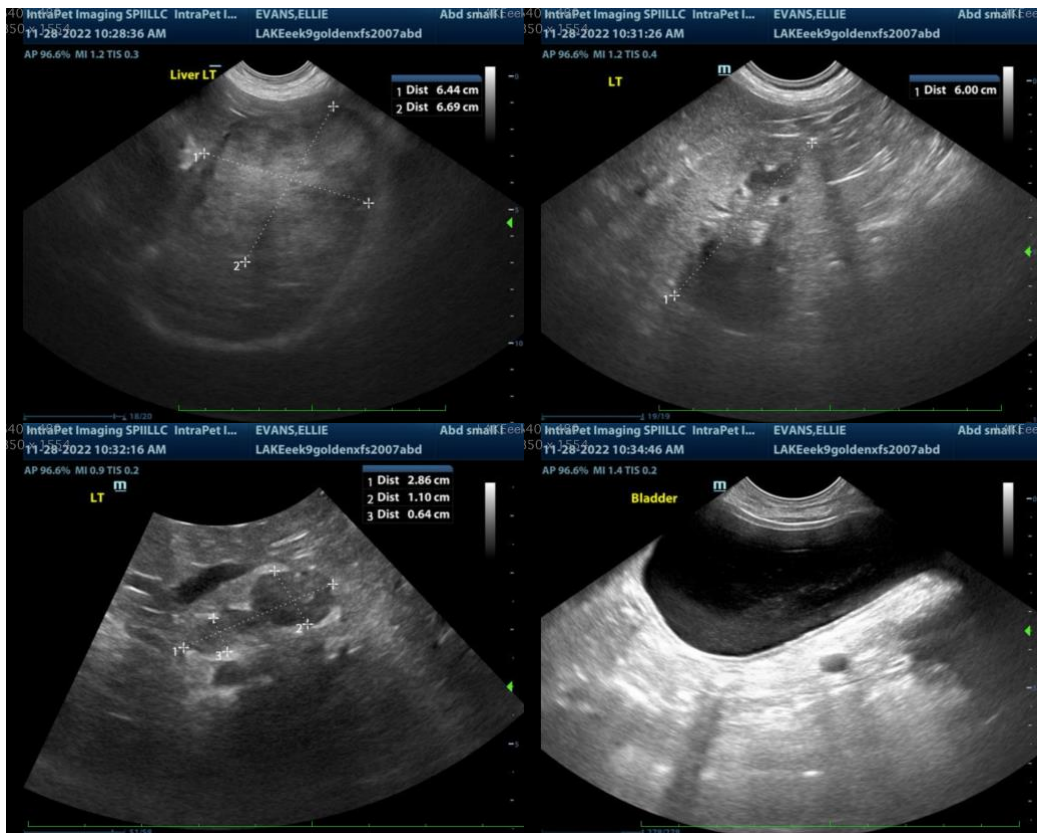
INTERPRETATION OF THE FINDINGS & FURTHER RECOMMENDATIONS

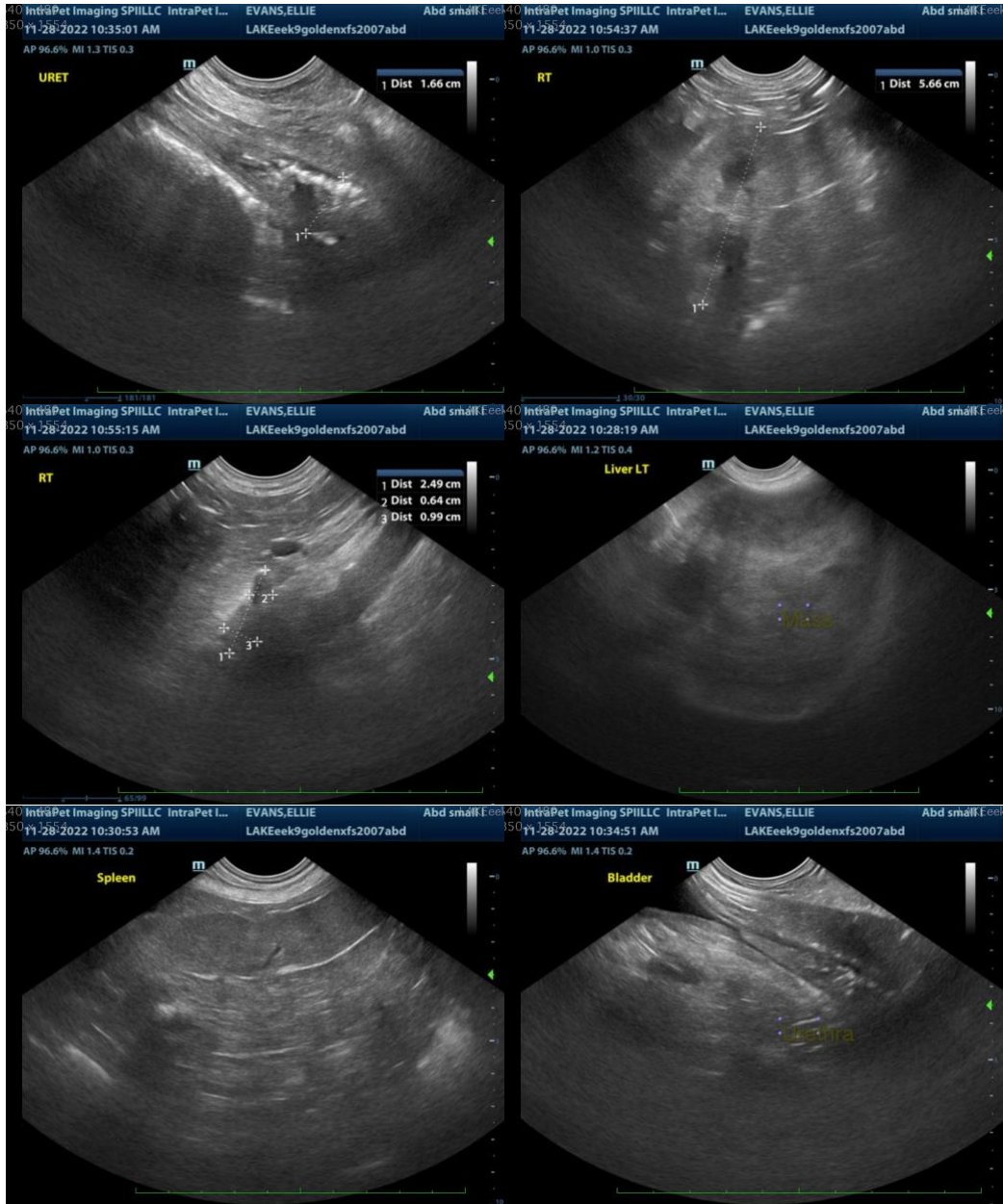
Three view thoracic radiographs are recommended for further assessment of cardio-pulmonary status as well as to further evaluate for any evidence of metastatic disease, if not recently evaluated.

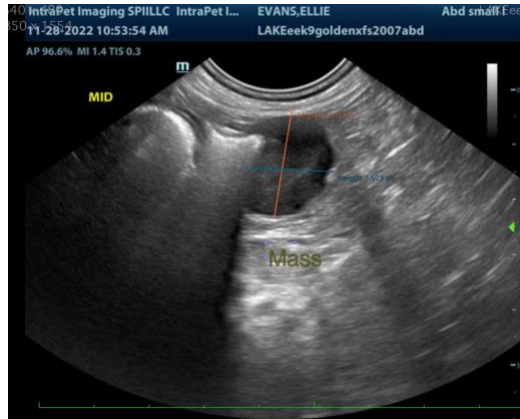Urinalysis and urine culture, if indicated based on urinalysis results, are recommended. Submission of urine to look for BRAF gene mutation, which is associated with urinary bladder cancer, could be considered. Other diagnostic options include traumatic catheterization, fine needle aspirate (with small risk of tumor seeding/trailing) or cystoscopy for further sampling. Or, given the reported struvite crystalluria, if a BRAF is not elected at this time, management of a likely urinary tract infection and struvite crystalluria/small cystoliths could be performed with recheck imaging of the area to determine progression versus improvement, etc.

A fine needle aspirate of the liver mass, as well as the mid abdominal/suspected colonic mass is recommended if patients coagulation status is appropriate.

Ultimately, pending results of the recommended diagnostics, patient status, owner wishes, etc., an exploratory laparotomy for excisional biopsy of the liver mass and mid abdominal mass may be warranted, as both masses appear likely resectable based on these images, however, definitive resectability cannot be guaranteed and a presurgical planning abdominal CT scan could also be considered.







The information and recommendations provided are based on the images presented by the referring veterinarian. No evaluation can be communicated regarding pathology that was not visible in the image/video clips provided.

Thank you for this referral. If the clinical or image interpretation does not parallel your findings or if I can be of any further assistance please contact me.

Beth Johnson, DVM DACVIM
Beth.Johnson@SonoPath.com