

**PATIENT**

Reagan Jubinski

**SPECIES**

Canine

**BREED**

Hound Mix

**SEX**

FS

**AGE**

2013

**WEIGHT**

62.5

**INTERPRETED BY**

Beth Johnson, DVM  
DACVIM

**IMAGING PERFORMED BY**

Rebekah Jakum, CVT,  
ARDMS/RVT

**HOSPITAL NAME**

Dr. Sam's Veterinary  
Housecalls

**REFERRING VET**

Dr. Ottinger

**INVOICE**

10815

**DATE**

11/25/2025

**PRESENTING CLINICAL SIGNS**

Several week duration severe PU/PD, otherwise BAR.

**ULTRASONOGRAPHIC EXAMINATION OF THE ABDOMEN**

**Urinary System**

The urinary bladder is adequately distended with anechoic contents. No masses, inflammatory changes, echogenic sediment or cystoliths are observed. The urinary bladder, trigone and visible pelvic urethra are normal in thickness with a smooth mucosal surface.

The right kidney is normal is size (5.9 cm), shape and echogenicity. It has smooth peripheral margination. There is a normal 1:3 cortex to medulla ratio with appropriate corticomedullary distinction. There is no evidence of pyelectasia, mineral or infarcts observed.

The left kidney is normal is size (5.7 cm), shape and echogenicity. It has smooth peripheral margination. There is a normal 1:3 cortex to medulla ratio with appropriate corticomedullary distinction. There is no evidence of pyelectasia, mineral or infarcts observed.

**Adrenal Glands**

The right adrenal gland is normal in size (0.56 cm at cranial pole and 0.48 cm at caudal pole), shape and overall architecture, echogenicity and echotexture. Visible surrounding vasculature appears normal.

The left adrenal gland is normal in size (0.45 cm at cranial pole and 0.67 cm at caudal pole), shape and overall architecture, echogenicity and echotexture. Visible surrounding vasculature appears normal.

**Spleen**

Spleen is subjectively normal in size with a normal smooth capsular contour. Parenchyma is appropriately finely textured and homogenous with normal echogenicity relative to surrounding tissue (hyperechoic to liver). Multifocal well-demarcated hyperechoic homogenous nodules are noted. Splenic vasculature appears normal.

**Liver**

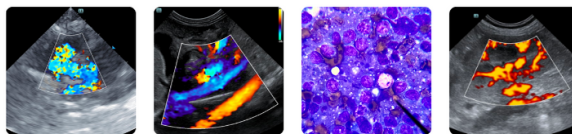
The liver is subjectively normal in size with normal smooth curvilinear peripheral contour. Parenchyma is appropriately hypoechoic to the spleen in echogenicity and appropriately mildly coarse and homogenous in echotexture. No focal lesions are observed. Visible vasculature and biliary tree appear normal without distension or congestion.

Gallbladder is moderately distended with anechoic bile as well as suspended and gravity dependent echogenic debris. The wall is smooth without visible thickening. There is no evidence of cystic or CBD dilation. There is no evidence of effusion or inflammation.

**Gastrointestinal**

The visible stomach wall is normal in thickness and layering. The lumen of the stomach is mildly distended with echogenic non-shadowing luminal contents and gas consistent with normal ingesta. There is no evidence of obstruction or foreign material noted. Pyloric outflow tract appears patent.

The visible small intestines are normal in wall thickness and layering. Small intestinal motility appears adequate (1-3 contractions per min). The lumen of the small intestine is mildly distended with



**PATIENT**

Reagan Jubinski

**SPECIES**

Canine

**BREED**

Hound Mix

**SEX**

FS

**AGE**

2013

**WEIGHT**

62.5

**INTERPRETED BY**

Beth Johnson, DVM  
DACVIM

**IMAGING PERFORMED BY**

Rebekah Jakum, CVT,  
ARDMS/RVT

**HOSPITAL NAME**

Dr. Sam's Veterinary  
Housecalls

**REFERRING VET**

Dr. Ottinger

**INVOICE**

10815

**DATE**

11/25/2025

echogenic non-shadowing luminal contents and gas consistent with normal ingesta. There is no evidence of obstruction or foreign material noted.

The visible colon is normal in wall thickness (< 0.2 cm) and layering. Contents are consistent with normal formed feces and gas.

**Pancreas**

The pancreas that is observed appears appropriately isoechoic to surrounding omental fat. Visible capsule is smooth and normal in contour. Visible pancreatic parenchyma is homogenous and unremarkable. There is no visible pancreatic duct dilation. There is no evidence of active peripancreatic inflammation.

**Free Abdomen**

There is no visible free peritoneal effusion noted in these images.

There is no apparent pathologic lymphadenopathy noted in these images.

**PRIMARY FINDINGS**

- Mild gallbladder debris - Cholecystic debris is of unknown clinical significance. It can be seen with biliary stasis from fasting or illness. Cholecystic debris is not necessarily related to hepatobiliary disease. Echogenic bile is most commonly an incidental finding in dogs and should be interpreted in combination with clinical signs such as nausea, inappetence, cranial abdominal discomfort and/or laboratory changes such as increased ALP and/or increased Tbili.

**SECONDARY FINDINGS**

- Hyperechoic splenic nodules - most consistent with benign myelolipomas. Other differentials such as fibrosis or calcification caused by old hematomas or infarcts, chronic inflammation, granulomatous disease or metastatic disease cannot be ruled out, but are considered less likely.

**INTERPRETATION OF THE FINDINGS & FURTHER RECOMMENDATIONS**

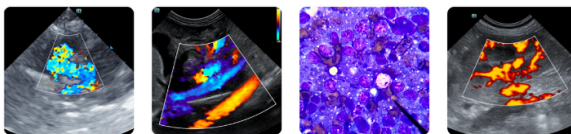
There is not a definitive ultrasonographically visible intraabdominal explanation for patient's reported PU/PD.

Differentials for PU/PD are vast and include, but are not limited to:

Primary polyuria caused by chronic kidney disease, pyelonephritis, liver disease, diabetes mellitus, hyperthyroidism, hypercalcemia, hyperadrenocorticism, hypoadrenocorticism, E.coli infections ie) pyometra in females, polycythemia, central diabetes insipidus or primary nephrogenic diabetes insipidus.

Primary polydipsia caused by psychogenic polydipsia, fever, pain, or central nervous system disease.

Most causes of PU/PD can be diagnosed with a comprehensive history and physical exam, a first AM urine specific gravity to see if urine concentration is possible (as most animals naturally consume less water overnight) followed by a comprehensive CBC, serum chemistry panel, electrolytes, and urinalysis.



**PATIENT**

Reagan Jubinski

**SPECIES**

Canine

**BREED**

Hound Mix

**SEX**

FS

**AGE**

2013

**WEIGHT**

62.5

**INTERPRETED BY**

Beth Johnson, DVM  
 DACVIM

**IMAGING PERFORMED BY**

Rebekah Jakum, CVT,  
 ARDMS/RVT

**HOSPITAL NAME**

Dr. Sam's Veterinary  
 Housecalls

**REFERRING VET**

Dr. Ottinger

**INVOICE**

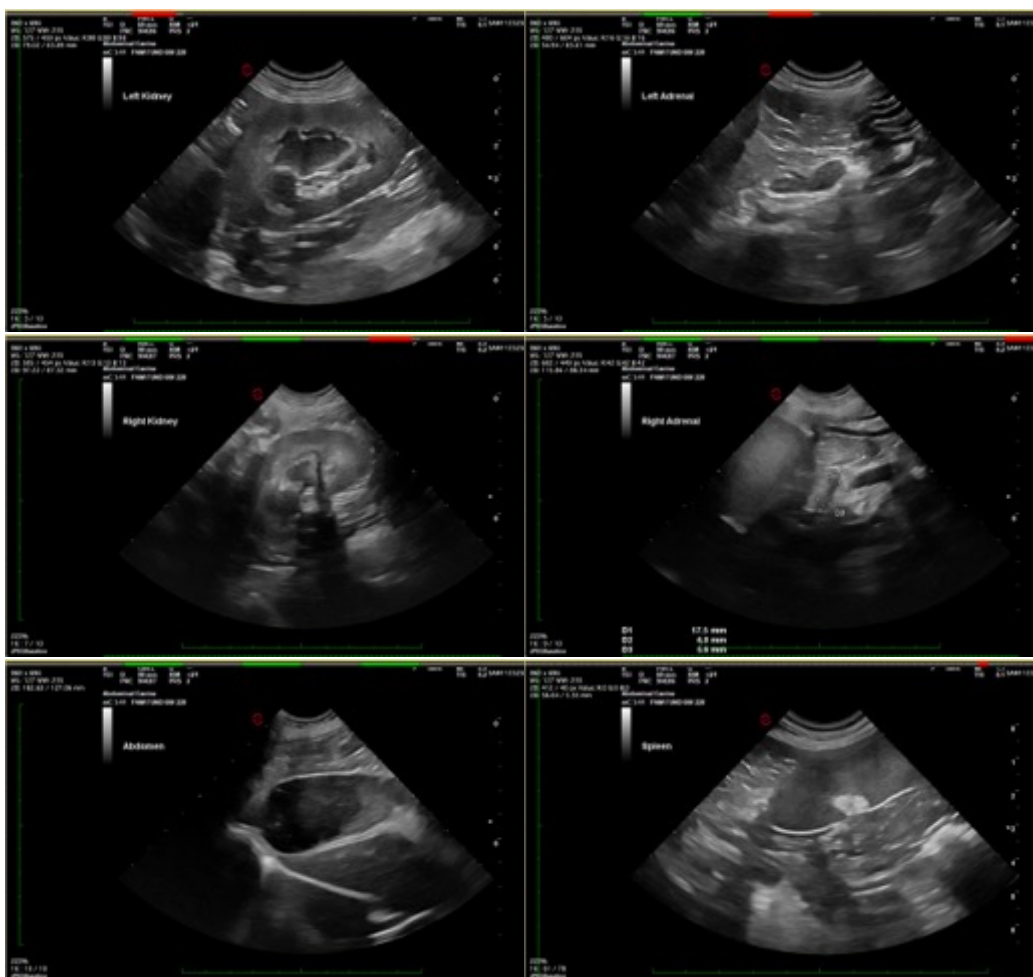
10815

**DATE**

11/25/2025

If not, next step(s) may include a urine culture, low dose dexamethasone suppression test, T4, bile acids, Leptospirosis testing and/or an empirical course of antibiotics.

If a diagnosis is still not obtained, a more advanced work-up is indicated and consultation with an internist may be warranted.



The information and recommendations provided are based on the images presented by the referring veterinarian/sonographer. No evaluation can be communicated regarding pathology that was not visible in the image/video clips provided.

Thank you for this referral. If the clinical or image interpretation does not parallel your findings or if I can be of any further assistance please contact me.

**Beth Johnson, DVM, DACVIM**  
 info@sonopath.com