

**PATIENT**

Gidget Keeler

**SPECIES**

Canine

**BREED**

Chihuahua Mix

**SEX**

FS

**AGE**

2011

**WEIGHT**

8.1

**INTERPRETED BY**

Beth Johnson, DVM  
DACVIM

**IMAGING PERFORMED BY**

Rebekah Jakum, CVT,  
ARDMS/RVT

**HOSPITAL NAME**

Pennsylvania Mobile

**REFERRING VET**

Dr. Meyer

**INVOICE**

10811

**DATE**

11/25/2025

**PRESENTING CLINICAL SIGNS**

1.4# weight loss in 4 months, clinically normal.

**ULTRASONOGRAPHIC EXAMINATION OF THE ABDOMEN**

**Urinary System**

The urinary bladder is adequately distended with anechoic contents. No masses, inflammatory changes, echogenic sediment or cystoliths are observed. The urinary bladder, trigone and visible pelvic urethra are normal in thickness with a smooth mucosal surface.

Kidneys are normal in shape with smooth peripheral margination. A normal 1:3 cortex to medulla ratio is maintained. The medulla and cortices are uniform in texture with some mild increased cortical echogenicity and mild loss of corticomedullary distinction, expected in this age patient. There is no evidence of pyelectasia, mineral or infarcts observed. The left is mildly subjectively small, measuring 2.7 cm. The right kidney is normal in size measuring 3.9 cm.

**Adrenal Glands**

The right adrenal gland is normal in size (0.54 cm at cranial pole and 0.4 cm at caudal pole), shape and overall architecture, echogenicity and echotexture. Visible surrounding vasculature appears normal.

The area of the left adrenal gland is examined without evident adrenal gland pathology but is unable to be well visualized/isolated for measurement.

**Spleen**

The spleen is subjectively normal in size (1.1 cm thick at the hilus) with a normal smooth capsular contour. Parenchyma is appropriately finely textured and homogenous with normal echogenicity relative to surrounding tissue (hyperechoic to liver). No focal nodules or masses are observed. Splenic vasculature appears normal.

**Liver**

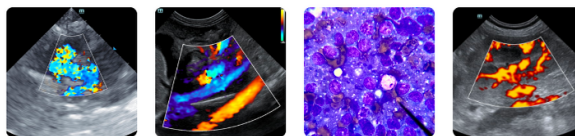
Liver is relatively normal in size and contour. Parenchyma is mildly heterogenous and coarse with mild likely age-related parenchymal remodeling noted. No focal lesions are observed. Visible vasculature and biliary tree appear normal without distension or congestion.

Gallbladder is non-distended in size. The wall is smooth without visible thickening. Luminal contents are primarily anechoic with some echogenic debris noted. There is no evidence of cystic or common bile duct dilation.

**Gastrointestinal**

The visible stomach wall is normal in thickness and layering. The lumen of the stomach is empty with no evidence of obstruction, foreign material or infiltrative disease. Pyloric outflow tract appears patent.

The visible small intestines are normal in wall thickness and layering. Small intestinal motility appears adequate (1-3 contractions per min). The lumen of the small intestine is empty with no evidence of obstruction, foreign material or infiltrative disease.



**PATIENT**

The visible colon is normal in wall thickness (< 0.2 cm) and layering. Contents are consistent with normal formed feces and gas.

Gidget Keeler

**Pancreas**

**SPECIES**

The pancreas that is observed appears appropriately isoechoic to surrounding omental fat. Visible capsule is smooth and normal in contour. Visible pancreatic parenchyma is homogenous and unremarkable. There is no visible pancreatic duct dilation. There is no evidence of active peripancreatic inflammation.

Canine

**BREED**

**Free Abdomen**

Chihuahua Mix

There is no visible free peritoneal effusion noted in these images.

**SEX**

There is no apparent pathologic lymphadenopathy noted in these images.

FS

**AGE**

**ULTRASONOGRAPHIC FINDINGS**

2011

- This is a largely unremarkable/normal structural senior ultrasound with age related changes, primarily noted in the kidneys, liver, and gallbladder. Early or emerging chronic kidney disease can't be definitively ruled out and should be suspected if supported via lab work results.

**WEIGHT**

**INTERPRETATION OF THE FINDINGS & FURTHER RECOMMENDATIONS**

8.1

If not already evaluated, a thorough evaluation of daily caloric intake is recommended to assure an adequate daily caloric intake is occurring vs an inadvertent reduction in calories due to change in diet and/or feeding schedule, competitive eating environment, etc.

**INTERPRETED BY**

If not recently evaluated, a general metabolic health screen (CBC, chemistry panel with electrolytes and urinalysis) is recommended.

Beth Johnson, DVM  
 DACVIM

Further recommendations for the reported weight loss are largely dependent on patient's appetite. Especially in the face of normal or even increased appetite. Further evaluation of digestion and absorption may be indicated via a gastrointestinal malabsorption panel (including cobalamin, folate, TLI and PLI) to Texas A&M GI Laboratory is recommended for further evaluation of GI and pancreatic function.

**IMAGING PERFORMED BY**

Rebekah Jakum, CVT,  
 ARDMS/RVT

**HOSPITAL NAME**

Otherwise, further evaluation for possible pain (dental, orthopedic, other), upper respiratory disease or oropharyngeal disease, cardiac disease and/or neurologic disease vs other as possible causes for decreased appetite and/or unintentional weight loss is also recommended.

Pennsylvania Mobile

**REFERRING VET**

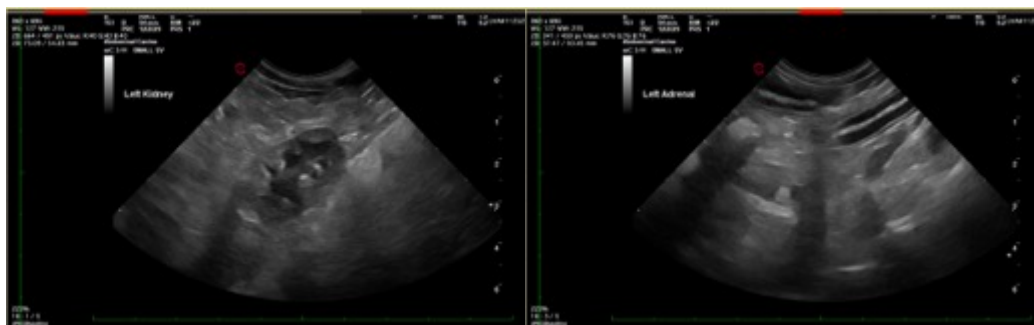Dr. Meyer

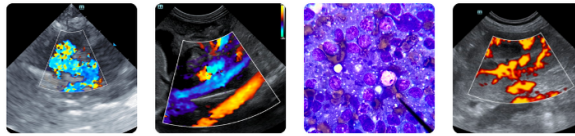
**INVOICE**

10811

**DATE**

11/25/2025





**PATIENT**

Gidget Keeler

**SPECIES**

Canine

**BREED**

Chihuahua Mix

**SEX**

FS

**AGE**

2011

**WEIGHT**

8.1

**INTERPRETED BY**

Beth Johnson, DVM  
DACVIM

**IMAGING PERFORMED BY**

Rebekah Jakum, CVT,  
ARDMS/RVT

**HOSPITAL NAME**

Pennsylvania Mobile

**REFERRING VET**

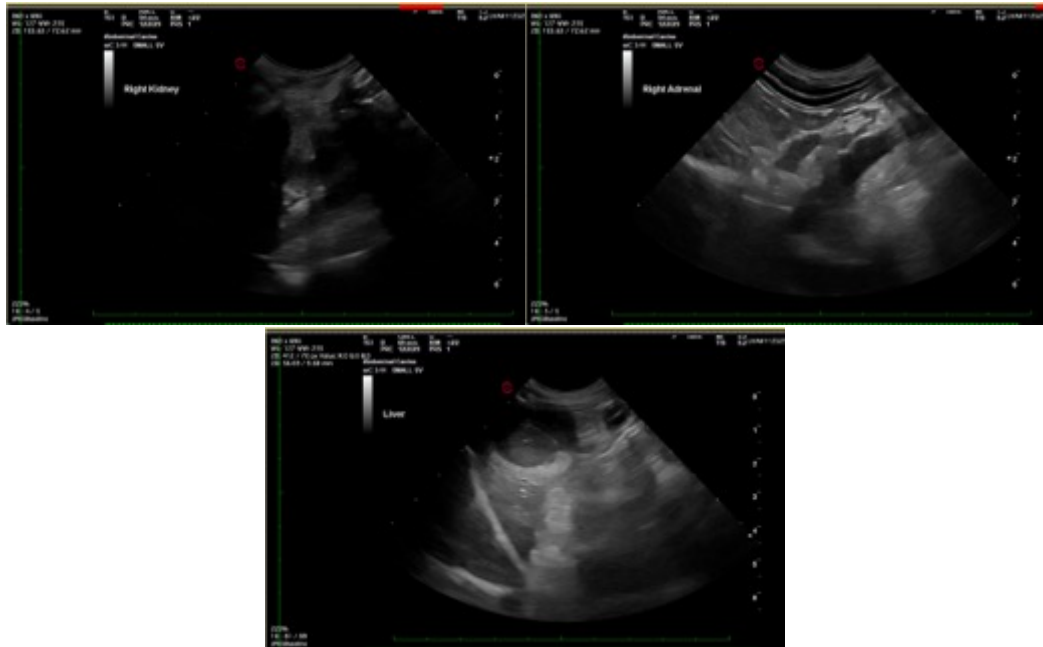
Dr. Meyer

**INVOICE**

10811

**DATE**

11/25/2025



The information and recommendations provided are based on the images presented by the referring veterinarian/sonographer. No evaluation can be communicated regarding pathology that was not visible in the image/video clips provided.

Thank you for this referral. If the clinical or image interpretation does not parallel your findings or if I can be of any further assistance please contact me.

**Beth Johnson, DVM, DACVIM**  
info@sonopath.com