



DATE PRESENTING CLINICAL SIGNS

11/24/25

Patient History: 11/7/25: Presented for increased thirst. PE: BAR; BCS 7/9; wt- lbs 13.16 / 5.97kg; mm- pink/moist; crt<2sec; eent- 3/4 dental tarter 2/4 gingivitis; h/l- no murmur or abn sounds; abd- soft, bladder very small, mild -mod tensing near bladder; s/c- dry with mild flaking; pln- wnl; rectal - not attempted. Unable to obtain a urine sample. Bloodwork showed marked leukocytosis and neutrophilia, with a mildly elevated ALT. P

PATIENT

Tigrilla Moncayo

given a convenia inj and sent home with Denamarin and gabapentin for next visit to help obtain a urine sample. 11/21/25: Presented to recheck. O reports she did well first week and this week has been vomiting hairballs, but O has also been changing diet. PE: General Appearance: BAR, Euhydrated, Pink moist MM

SPECIES

Feline

Current Medications: 11/7/25: Denamarin Advanced, convenia inj (8mg/kg) SQ

BREED

Labwork Results: Labwork not attached, reported as: 11/7/25: CBC: WBC 31.36, neut 26.06

DLH

Chem: ALT 133U/L, GGT 5U/L 11/21/25- UA- yellow, clear, cysto; SG- 1.050; Sed- +1 cocci;Stick- Protein- trace, Leukocytes- +500. pH- 6.5, Blood +50. Cbc- WBC 30.7 H* - wnl. Hepatic Panel- GGT 6 H*, ALT 184 H* - wnl

SEX

Date of Previous IntraPet Ultrasound: No previous.

Spayed Female

Sedation: Not required to complete full diagnostic ultrasound.

Stat Report: Not requested.

Imaging Performed by: Rachel Brillhart, RDMS.

AGE

ULTRASONOGRAPHIC EXAMINATION OF THE ABDOMEN

5/27/21

Urinary System

WEIGHT

12.83 Pounds

Urinary bladder is adequately distended with anechoic contents. No masses, inflammatory changes, echogenic sediment or cystoliths are observed. The urinary bladder, trigone and visible pelvic urethra are normal in thickness with a smooth mucosal surface.

INTERPRETED BY

Beth Johnson, DVM
DACVIM

Kidneys are overall normal in size and shape with smooth peripheral margination. A normal 1:3 cortex to medulla ratio is maintained. The medulla and cortices are uniform in texture with some mild increased cortical echogenicity and mild loss of corticomedullary distinction, expected in this age patient. There is no evidence of pyelectasia, mineral or infarcts observed. The left kidney measures 3.83 cm. The right kidney measures 3.69 cm.

HOSPITAL NAME

BPH Timonium

Adrenal Glands

REFERRING VET

Dr. Falkowski

Left adrenal gland is normal in size (0.53 cm), shape and overall architecture, echogenicity and echotexture. Visible surrounding vasculature appears normal.

Right adrenal gland is normal in size (0.41 cm), shape and overall architecture, echogenicity and echotexture. Visible surrounding vasculature appears normal.

INVOICE

35654

Spleen

Spleen is subjectively normal in size with a normal smooth capsular contour. Parenchyma is appropriately finely textured and homogenous with normal echogenicity relative to surrounding tissue (hyperechoic to liver). No focal nodules or masses are observed. Splenic vasculature appears normal.

Liver

Liver is subjectively enlarged (swollen contour) without disruption of architecture. It has a normal homogenous echotexture. Parenchyma is diffusely hyperechoic characterized by less prominent than normal portal vein walls and increased echogenicity relative to the spleen and falciform fat. No focal lesions are observed. Visible vasculature and biliary tree appear normal without distension or congestion.

Gallbladder is non-distended in size. The gallbladder wall is thick and edematous characterized by an intramural hypo to anechoic rim or "double rim effect or halo sign". Luminal contents are primarily anechoic. There is no evidence of cystic or common bile duct dilation.

Gastrointestinal

The visible stomach wall is normal in thickness and layering. The lumen of the stomach is empty with no evidence of obstruction, foreign material or infiltrative disease. Pyloric outflow tract appears patent.

The visible small intestine demonstrates areas of moderate to severely thick muscularis layer relative to mucosa (disruption of the normal 1:3 muscularis:mucosa ratio). Small intestinal submucosa is slightly irregular, thick and hyperechoic, without evident loss of layering appreciated. The lumen of the small intestine is empty with no evidence of obstruction or foreign material.

The visible colon is normal in wall thickness (< 0.2 cm) and layering. Contents are consistent with normal formed feces and gas.

Pancreas

Pancreas is prominent (enlarged) in size, hypoechoic to surrounding tissue and has a mildly irregular undulating contour. Parenchyma is coarse with mixed echogenic remodeling noted. No pancreatic duct dilation is noted.

Free Abdomen

There is no visible free peritoneal effusion noted in these images.

The colonic lymph nodes are prominent in size with swollen capsular contour. Normal elongated shape (length to width ratio) is maintained. There is no loss of parenchymal detail.

ULTRASONOGRAPHIC FINDINGS

Primary Findings

- Moderate inflammatory bowel disease pattern- Thick muscularis has been reported with infiltrative bowel disease including both benign inflammatory disease as well as infiltrative neoplasia such as lymphoma. No loss of layering, etc. is noted to make lymphoma more probable, but lymphoma cannot be definitively ruled out without tissue sampling.
- Concurrent chronic low grade smoldering pancreatitis is suspected.
- Moderately reactive colonic lymphadenopathy- infiltrative neoplastic disease cannot be ruled out but is considered less likely.

- Hyperechoic hepatomegaly- This appearance is most consistent with benign hepatic lipidosis or endocrine/DM hepatopathy. Infiltrative disease such as amyloidosis or round cell neoplasia, such as mast cell tumor or less likely, lymphoma, is also possible.
- Gallbladder halo sign- GB wall edema is a non-specific change and can be seen with any underlying etiology (ie vasculitis, hypoalbuminemia, CHF, other) that results in edema, as well as immune-mediated disease, anaphylactic shock, other. Cholecystitis cannot be ruled out.

Secondary Findings

- Age-related kidney changes

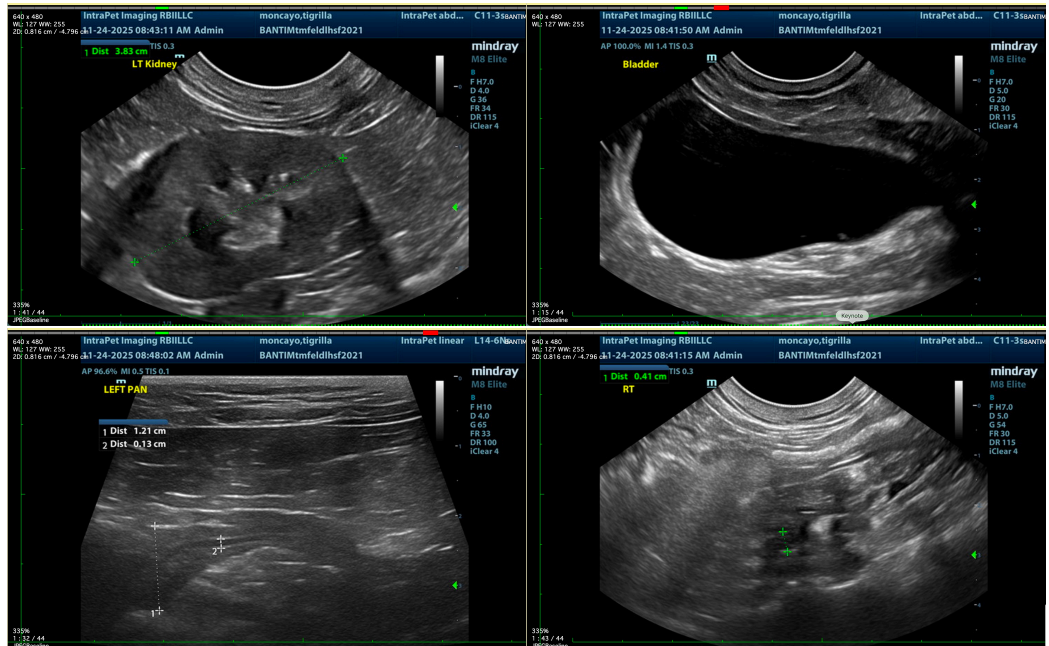
INTERPRETATION OF THE FINDINGS & FURTHER RECOMMENDATIONS

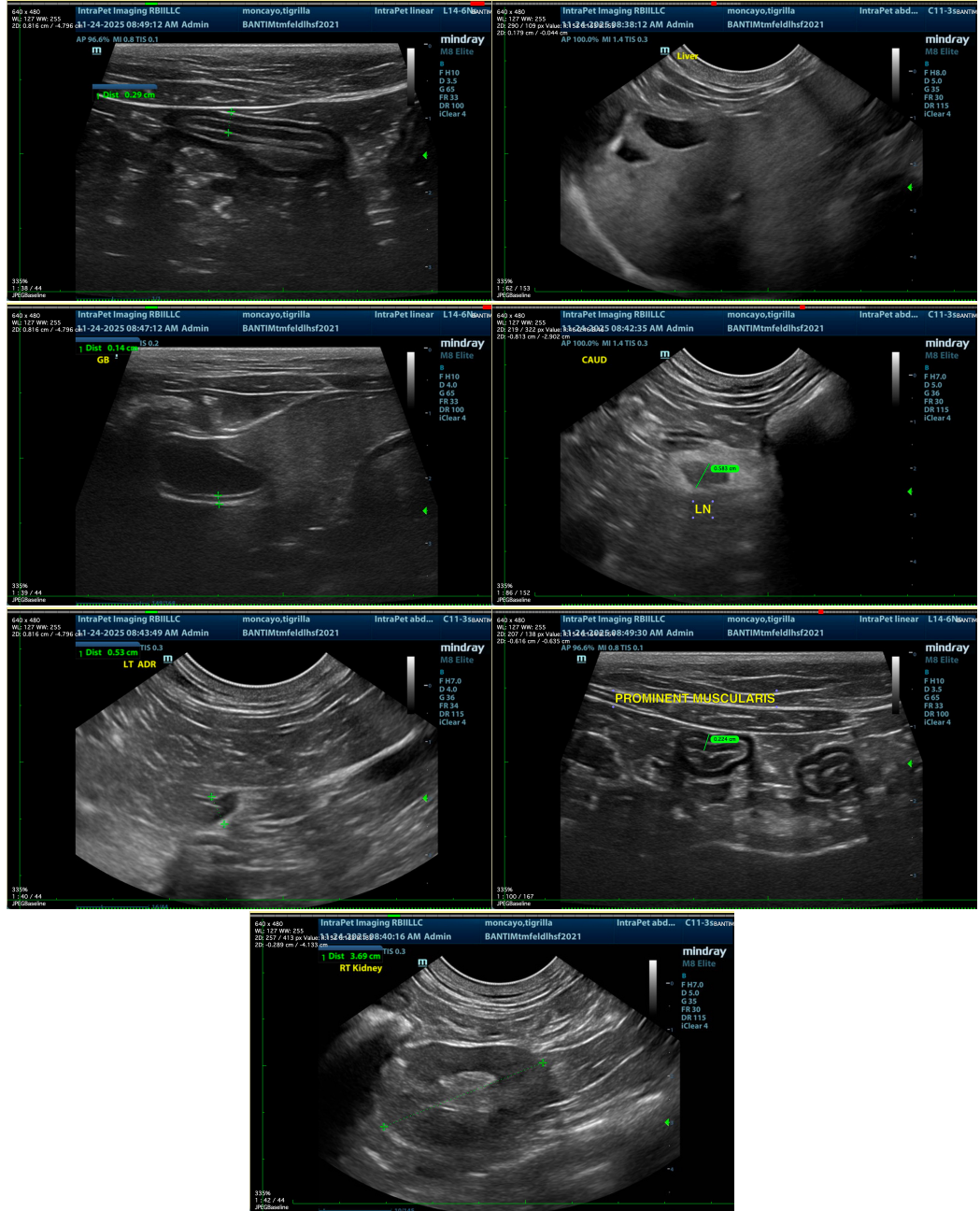
If not recently evaluated, a T4 +/- free T4 is recommended.

A gastrointestinal malabsorption panel (including cobalamin, folate, TLI and PLI) to Texas A&M GI Laboratory is recommended for further evaluation of GI and pancreatic function.

Tissue sampling may be necessary. Pending results of above, fine needle aspirates of the liver +/- enlarged lymph nodes (if they can safely be reached) could be considered if patient's coagulation status is appropriate. Or, ultimately, biopsies of the GI tract, being sure to include ileum, if possible, may be necessary for a definitive diagnosis, and therefore, to further guide medical management.

In the meantime, treatment recommendations include fluid therapy, anti-emetics, gastroprotectants, hepatic nutraceuticals such as ursodiol and/or Denamarin, and broad-spectrum antibiotics. Nutritional support is critical to prevent/manage concurrent hepatic lipidosis, so appetite stimulants and/or, if indicated, feeding tube placement is also recommended.





The information and recommendations provided are based on the images presented by the referring veterinarian/sonographer. No evaluation can be communicated regarding pathology that was not visible in the image/video clips provided.

Thank you for this referral. If the clinical or image interpretation does not parallel your findings or if I can be of any further assistance please contact me.

Beth Johnson, DVM DACVIM

info@sonopath.com