



PATIENT

Isomalt Belz

SPECIES

Feline

BREED

DMH

SEX

Neutered Male

AGE

18 Years

WEIGHT

14.87 Pounds

INTERPRETED BY

Beth Johnson, DVM
DACVIM

IMAGING PERFORMED BY

Amy Mayhew, LVT

HOSPITAL NAME

SVS Imaging MI

REFERRING VET

Belz/Four Paws VW

INVOICE

18184

DATE

11/21/22

PRESENTING CLINICAL SIGNS

History: Recurrent UTI

Abnormal PE/Chem/CBC/UA Results: Attached - bloodwork, u/a and c/s from the last few months. Patient is also diabetic and most recently does not seem regulated. Waiting for owner to send glucose curve Note: He has had these infections even when his DM has been well-regulated

ULTRASONOGRAPHIC EXAMINATION OF THE ABDOMEN

Urinary System

Urinary bladder is adequately distended. It has a normal uniform wall thickness. Contents include primarily anechoic fluid with occasional echogenic non-shadowing debris, most consistent with incidental suspended lipid in a cat, possibly combined with exfoliated cells, mucous and/or small blood clots. Both sterile inflammation as well as urinary tract infection can also present with echogenic debris. No masses or cystoliths are observed. The trigone and visible pelvic urethra are normal in thickness with a smooth mucosal surface.

Left kidney is normal is size (4.03 cm), shape and echogenicity. It has smooth peripheral margination. There is a normal 1:3 cortex to medulla ratio with appropriate corticomedullary distinction. There is no evidence of mineral or infarcts observed. Pyelectasia is present, measuring 0.51 cm in the transverse view.

Right kidney is normal is size (4.53 cm), shape and echogenicity. It has smooth peripheral margination. There is a normal 1:3 cortex to medulla ratio with appropriate corticomedullary distinction. There is no evidence of pyelectasia, mineral or infarcts observed.

Adrenal Glands

Left adrenal gland is normal in size (0.34 cm), shape and overall architecture, echogenicity and echotexture. Visible surrounding vasculature appears normal.

Right adrenal gland is normal in size (0.46 cm), shape and overall architecture, echogenicity and echotexture. Visible surrounding vasculature appears normal.

Spleen

Spleen is subjectively normal in size with a normal smooth capsular contour. Parenchyma is appropriately finely textured and homogenous with normal echogenicity relative to surrounding tissue (hyperechoic to liver). No focal nodules or masses are observed. Splenic vasculature appears normal.

Liver

Liver is subjectively enlarged (swollen contour) without disruption of architecture. It has a normal homogenous echotexture. Parenchyma is diffusely hyperechoic characterized by less prominent than normal portal vein walls and increased echogenicity relative to the spleen and falciform fat. No focal lesions are observed. Visible vasculature and biliary tree appear normal without distension or congestion.

Gallbladder is moderately distended with anechoic bile as well as suspended and gravity dependent echogenic debris. The wall is smooth without visible thickening. There is no evidence of cystic or CBD dilation. There is no evidence of effusion or inflammation.

Gastrointestinal



PATIENT

Isomalt Belz

The visible stomach wall is normal in thickness and layering. The lumen of the stomach is mildly distended with very echogenic reverberation artifact from intraluminal gas. There is no evidence of obstruction, foreign material or infiltrative disease; however, complete visualization of far wall is partially inhibited by gas. Pyloric outflow tract appears patent.

SPECIES

Feline

The visible small intestines are normal in wall thickness and layering. Small intestinal motility appears adequate (1-3 contractions per min). The lumen of the small intestine is mildly distended with echogenic non-shadowing luminal contents and gas consistent with normal ingesta. There is no evidence of obstruction, foreign material or infiltrative disease.

BREED

DMH

The visible colon is normal in wall thickness and layering. Contents are consistent with normal formed feces and gas.

SEX

Neutered Male

Pancreas

Pancreas is prominent (enlarged) in size, hypoechoic to surrounding tissue and has a mildly irregular undulating contour.

AGE

18 Years

Free Abdomen

A very scant amount of anechoic free fluid was present in the mid abdomen. There is no apparent lymphadenopathy.

ULTRASONOGRAPHIC FINDINGS

WEIGHT

14.87 Pounds

Primary Findings

- Hyperechoic hepatomegaly – This appearance is most consistent with benign hepatic lipidosis. Infiltrative disease such as amyloidosis or round cell neoplasia, such as mast cell tumor or less likely, lymphoma, is also possible.
- Left kidney Pyelectasia – Differentials for pyelectasia include pyelonephritis, diuresis, congenital malformation or ureteral or lower urinary tract obstruction.
- A scant amount of anechoic free fluid

INTERPRETED BY

Beth Johnson, DVM
DACVIM

Secondary Findings

- Urinary bladder debris
- Chronic active pancreatitis
- Gallbladder debris – Cholecytic debris is of unknown clinical significance. It can be seen with biliary stasis from fasting or illness, however, it can also be associated with hepatobiliary disease in cats and should be interpreted in combination with clinical signs such as nausea, inappetence, cranial abdominal discomfort and/or laboratory changes such as increased ALP and/or increased Tbili.

IMAGING PERFORMED BY

Amy Mayhew, LVT

HOSPITAL NAME

SVS Imaging MI

REFERRING VET

Belz/Four Paws VW

INVOICE

18184

INTERPRETATION OF THE FINDINGS & FURTHER RECOMMENDATIONS

There is no ultrasonographically visible structural/anatomic, etc., reason to explain this patients recurrent urinary tract infections, except to for the pyelectasia described above. Top differential is potentially pyelonephritis, potentially secondary to diabetes mellitus.

DATE

11/21/22

Recommendations include treatment of the urinary tract infection long term, as a complicated urinary



PATIENT

Isomalt Belz

tract infection based on culture and sensitivity results, i.e., at least 6 weeks with a follow up culture a week to 10 days after starting antibiotics to rule out any secondary bacteria and ending with a culture a week to 10 days after finishing antibiotics to assure full clearance.

SPECIES

Feline

The urinary tract infections are reportedly a problem even when the diabetes is well regulated but additionally given the reported lack of regulation recently, regulation of the diabetes is also necessary.

BREED

DMH

A probiotic such as Fortiflora could be considered in an attempt to prevent the recurrence of future infections.

SEX

Neutered Male

AGE

18 Years

WEIGHT

14.87 Pounds

INTERPRETED BY

Beth Johnson, DVM
DACVIM

IMAGING PERFORMED BY

Amy Mayhew, LVT

HOSPITAL NAME

SVS Imaging MI

REFERRING VET

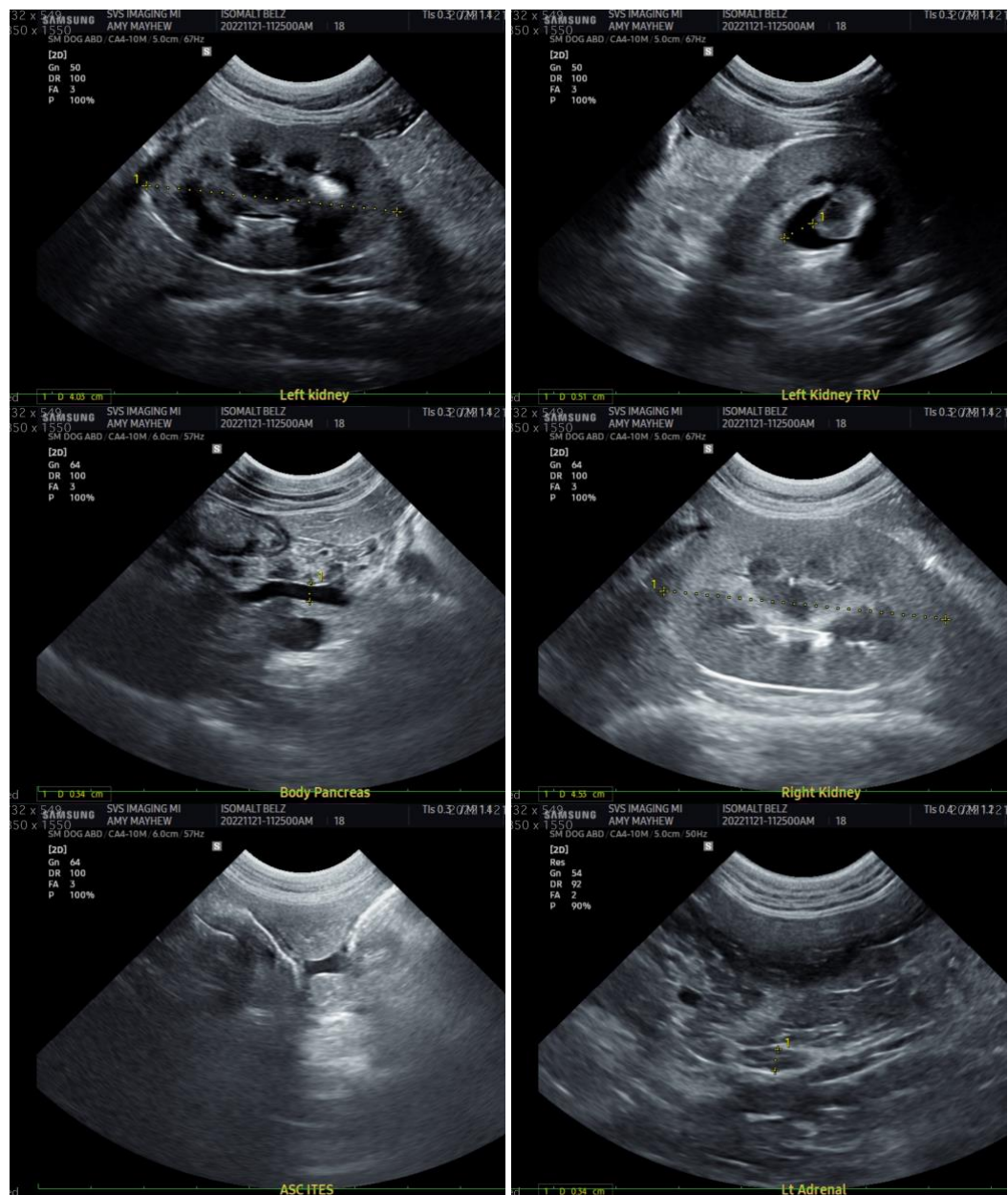
Belz/Four Paws VW

INVOICE

18184

DATE

11/21/22





PATIENT

Isomalt Belz

SPECIES

Feline

BREED

DMH

SEX

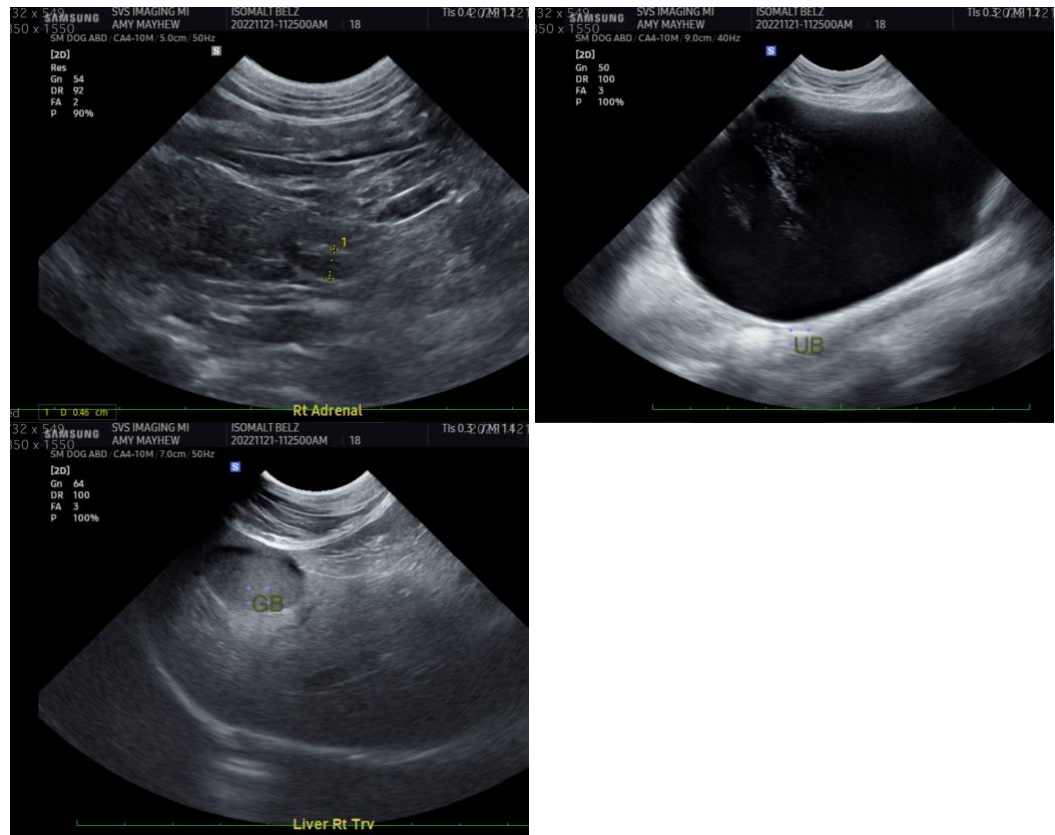
Neutered Male

AGE

18 Years

WEIGHT

14.87 Pounds



INTERPRETED BY

Beth Johnson, DVM
DACVIM

IMAGING PERFORMED BY

Amy Mayhew, LVT

HOSPITAL NAME

SVS Imaging MI

REFERRING VET

Belz/Four Paws VW

INVOICE

18184

DATE

11/21/22

The information and recommendations provided are based on the images presented by the referring veterinarian. No evaluation can be communicated regarding pathology that was not visible in the image/video clips provided.

Thank you for this referral. If the clinical or image interpretation does not parallel your findings or if I can be of any further assistance please contact me.

Beth Johnson, DVM DACVIM

Beth.Johnson@SonoPath.com