

**DATE**

11/21/22

PRESENTING CLINICAL SIGNS

History: Not eating well, vomiting yellow liquid, slowing down last 2 weeks.

PATIENT

Belle Ford

Current Medications: Starting cerenia 60mg, starting entyce 3cc, enro 136 1.5 am 1 pm

Lab Results: alp 795, alt 1110, cholesterol 399, bili 4.8

Date of Previous IntraPet Ultrasound: No previous.

Sedation: Not required to complete full diagnostic ultrasound.

Stat Report: Not requested.

Imaging Performed By: Rachel Brillhart, RDMS.

SPECIES

Canine

BREED

Golden Retriever

SEX

Spayed Female

AGE

11/26/10

WEIGHT

69 Pounds

ULTRASONOGRAPHIC EXAMINATION OF THE ABDOMEN**Urinary System**

Urinary bladder is adequately distended with anechoic contents. No masses, inflammatory changes, echogenic sediment or cystoliths are observed. The urinary bladder, trigone and visible pelvic urethra are normal in thickness with a smooth mucosal surface.

Left kidney is normal is size (7.18 cm), shape and echogenicity. It has smooth peripheral margination. There is a normal 1:3 cortex to medulla ratio with appropriate corticomedullary distinction. There is no evidence of pyelectasia, mineral or infarcts observed.

Right kidney is normal is size (7.37 cm), shape and echogenicity. It has smooth peripheral margination. There is a normal 1:3 cortex to medulla ratio with appropriate corticomedullary distinction. There is no evidence of pyelectasia, mineral or infarcts observed.

Adrenal Glands

Left adrenal gland is normal in size (2.9 cm long x 0.65 cm at cranial pole and 0.76 cm at caudal pole), shape and overall architecture, echogenicity and echotexture. Visible surrounding vasculature appears normal.

Right adrenal gland is normal in size (3.37 cm long x 0.69 cm at cranial pole and 0.69 cm at caudal pole), shape and overall architecture, echogenicity and echotexture. Visible surrounding vasculature appears normal.

Spleen

Spleen is subjectively large in size with a swollen and scalloped/undulating capsular contour. Multifocal coalescing nodules are noted throughout the parenchyma. Splenic vasculature appears normal. Enhanced hyperechoic surrounding fat is noted.

Liver

Liver is subjectively enlarged with mildly irregular margins. Parenchyma is heterogenous characterized by multiple poorly defined hypoechoic nodules within otherwise hyperechoic liver parenchyma. Visible vasculature and biliary tree appear normal without distension or congestion.

Gallbladder is moderately distended with anechoic bile as well as suspended and gravity dependent echogenic debris. The wall is smooth without visible thickening. There is no evidence of cystic or CBD dilation. There is no evidence of effusion or inflammation.

Gastrointestinal

The visible stomach wall is normal in thickness and layering. The lumen of the stomach is empty with no evidence of obstruction, foreign material or infiltrative disease. Pyloric outflow tract appears patent.

INTERPRETED BYBeth Johnson, DVM
DACVIM**HOSPITAL NAME**Animal Clinic of
Southgate**REFERRING VET**

Dr. Jones

INVOICE

18169

The visible small intestines are normal in wall thickness and layering. Small intestinal motility appears adequate (1-3 contractions per min). The lumen of the small intestine is empty with no evidence of obstruction, foreign material or infiltrative disease.

The visible colon is normal in wall thickness and layering. Contents are consistent with normal formed feces and gas.

Pancreas

The observed pancreas appears appropriately isoechoic to surrounding omental fat. Visible capsule is smooth and normal in contour. Visible pancreatic parenchyma is homogenous and unremarkable. There is no visible pancreatic duct dilation. There is no evidence of active peripancreatic inflammation.

Free Abdomen

There is no apparent lymphadenopathy. A scant amount of anechoic free fluid is noted, primarily around the spleen.

Other

No pericardial effusion is noted in these images.

ULTRASONOGRAPHIC FINDINGS

Primary Findings

- Honeycomb Spleen – This finding is strongly suggestive of infiltrative disease such as round cell neoplasia. Benign disease cannot be ruled out but is considered less likely.
- Heterogenous Liver – These changes are most consistent with benign processes such as nodular hyperplasia, steroid (vacuolar) hepatopathy, extramedullary hematopoiesis or possibly chronic inflammatory disease and less commonly infiltrative round cell or metastatic neoplasia.
- A scant amount of anechoic free fluid, primarily around the spleen

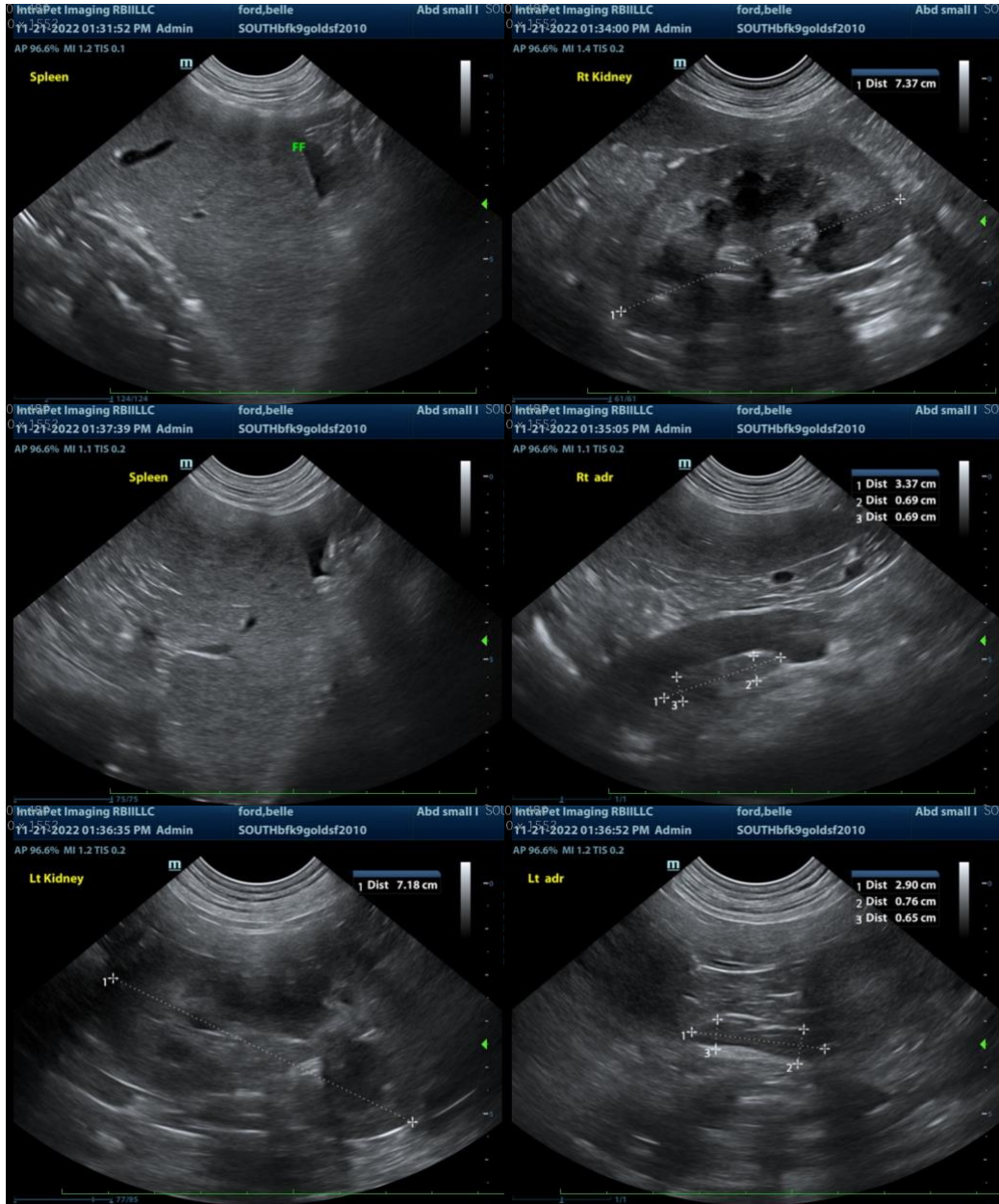
Secondary Findings

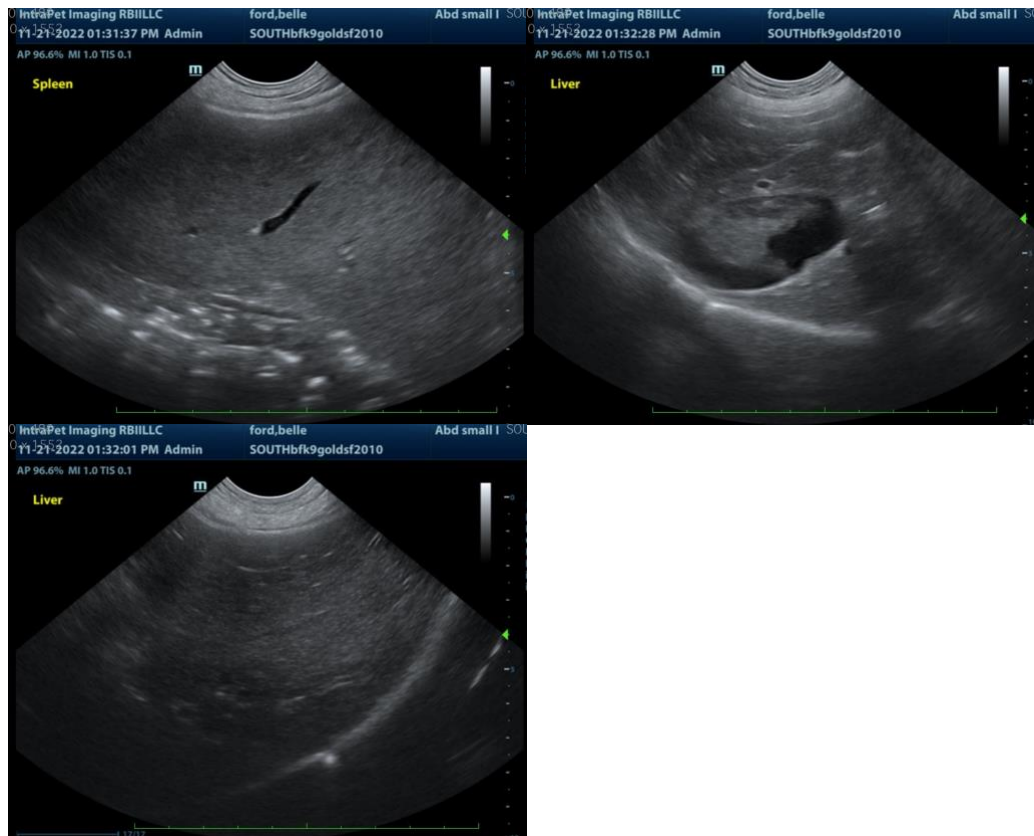
- Gallbladder debris - Cholecystic debris is of unknown clinical significance. It can be seen with biliary stasis from fasting or illness. Cholecystic debris is not necessarily related to hepatobiliary disease. Echogenic bile is most commonly an incidental finding in dogs and should be interpreted in combination with clinical signs such as nausea, inappetence, cranial abdominal discomfort and/or laboratory changes such as increased ALP and/or increased Tbili.

INTERPRETATION OF THE FINDINGS & FURTHER RECOMMENDATIONS

Three view thoracic radiographs are recommended for further assessment of cardio-pulmonary status as well as to further evaluate for any evidence of metastatic disease, if not recently evaluated.

The primary pathology noted in these images involves the spleen and is suspicious for infiltrative round cell neoplasia. However, given the reported liver enzyme increase, a fine needle aspirate of both the spleen and liver is recommended if patients coagulation status is appropriate.





The information and recommendations provided are based on the images presented by the referring veterinarian. No evaluation can be communicated regarding pathology that was not visible in the image/video clips provided.

Thank you for this referral. If the clinical or image interpretation does not parallel your findings or if I can be of any further assistance please contact me.

Beth Johnson, DVM DACVIM
Beth.Johnson@SonoPath.com