



PATIENT

Ophelia Wolfel

SPECIES

Feline

BREED

Domestic Longhair

SEX

Spayed Female

AGE

8 Years

WEIGHT

13.9 lbs

INTERPRETED BY

Beth Johnson, DVM
DACVIM

IMAGING PERFORMED BY

Meghan Morse, LVT,
CVT

HOSPITAL NAME

Kingston Animal
Hospital

REFERRING VET

Dr. Turner

INVOICE

72008

DATE

11/20/25

PRESENTING CLINICAL SIGNS

Chronic d+ and V+, no improvement on metro or diet change No current meds
Abnormal PE/Chem/CBC/UA Results: BW WNL

ULTRASONOGRAPHIC EXAMINATION OF THE ABDOMEN

Urinary System

The urinary bladder is adequately distended with anechoic contents. No masses, inflammatory changes, echogenic sediment or cystoliths are observed. The urinary bladder, trigone and visible pelvic urethra are normal in thickness with a smooth mucosal surface.

Kidneys are bilaterally irregular and diffusely echogenic with decreased corticomedullary distinction and poor visualization of internal architecture. There is no pyelectasia noted and no mineral is observed. Left kidney is normal size at 3.83 cm. Right kidney is normal size at 4.3 cm. Chronic infarcts are noted bilaterally.

Adrenal Glands

The right adrenal gland is normal in size (0.36 cm), shape and overall architecture, echogenicity and echotexture. Visible surrounding vasculature appears normal.

The left adrenal gland is normal in size (0.42 cm), shape and overall architecture, echogenicity and echotexture. Visible surrounding vasculature appears normal.

Spleen

The spleen is subjectively normal in size with a normal smooth capsular contour. Parenchyma is appropriately finely textured and homogenous with normal echogenicity relative to surrounding tissue (hyperechoic to liver). No focal nodules or masses are observed. Splenic vasculature appears normal.

Liver

The liver is subjectively normal in size with normal smooth curvilinear peripheral contour. Parenchyma is appropriately hypoechoic to the spleen in echogenicity and appropriately mildly coarse and homogenous in echotexture. No focal lesions are observed. Visible vasculature and biliary tree appear normal without distension or congestion.

The gallbladder is non-distended in size. The wall is smooth without visible thickening. Luminal contents are primarily anechoic. There is no evidence of cystic or common bile duct dilation.

Gastrointestinal

The visible stomach wall is normal in thickness and layering. The lumen of the stomach is empty with no evidence of obstruction, foreign material or infiltrative disease. Pyloric outflow tract appears patent.

The visible small intestine demonstrates areas of moderately thick muscularis layer relative to mucosa (disruption of the normal 1:3 muscularis:mucosa ratio). Small intestinal submucosa is slightly irregular, thick and hyperechoic, without evident loss of layering appreciated. The lumen of the small intestine is empty with no evidence of obstruction or foreign material.

The visible colon is normal in wall thickness (< 0.2 cm) and layering. Contents are consistent with normal formed feces and gas.



PATIENT

Ophelia Wolfel

SPECIES

Feline

BREED

Domestic Longhair

SEX

Spayed Female

AGE

8 Years

WEIGHT

13.9 lbs

INTERPRETED BY

Beth Johnson, DVM
DACVIM

IMAGING PERFORMED BY

Meghan Morse, LVT,
CVT

HOSPITAL NAME

Kingston Animal
Hospital

REFERRING VET

Dr. Turner

INVOICE

72008

DATE

11/20/25

Pancreas

The pancreas that is observed appears appropriately isoechoic to surrounding omental fat. Visible capsule is smooth and normal in contour. Visible pancreatic parenchyma is homogenous and unremarkable. There is no visible pancreatic duct dilation. There is no evidence of active peripancreatic inflammation.

Free Abdomen

There is no visible free peritoneal effusion noted in these images.

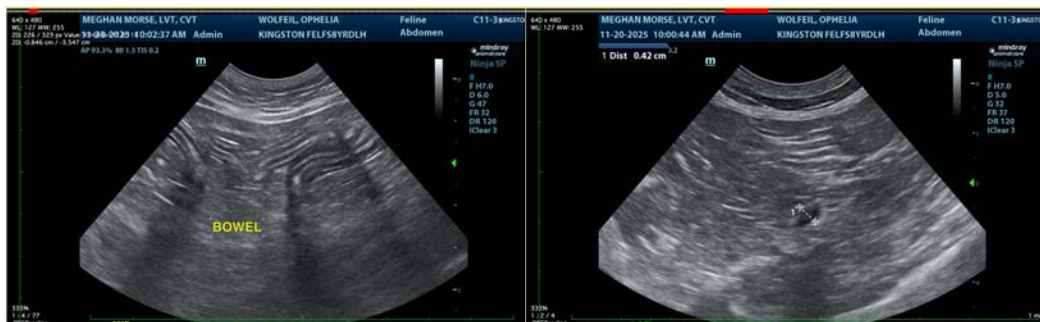
There is no apparent pathologic lymphadenopathy noted in these images.

ULTRASONOGRAPHIC FINDINGS

- Moderate inflammatory bowel disease (IBD) pattern – Thick muscularis has been reported with infiltrative bowel disease including both benign inflammatory disease as well as infiltrative neoplasia such as lymphoma. No loss of layering, etc. is noted to make lymphoma more probable, but lymphoma cannot be definitively ruled out without tissue sampling.
- Bilateral chronic infarcts in the kidneys.

INTERPRETATION OF THE FINDINGS & FURTHER RECOMMENDATIONS

- A gastrointestinal malabsorption panel (including cobalamin, folate, TLI and PLI) to Texas A&M GI Laboratory is recommended for further evaluation of GI and pancreatic function.
- Ideally, biopsies of the GI tract, being sure to include ileum if possible, are recommended to definitively diagnose and therefore manage the infiltrative bowel disease.
- If biopsies cannot be obtained, empirical therapies could include a probiotic (if diarrhea is present, such as visbiome or proviable), empirical deworming with a 5-day course of Panacur and, if tolerated, a transition in diet, based on trial-and-error response, beginning with a hydrolyzed protein diet. Some patients respond to one brand/version of a hydrolyzed protein diet better than another brand, so several trials may be required.
- Additional considerations could include cobalamin supplementation (unless cobalamin level is evaluated and supplementation is not warranted) and prednisolone (if not contraindicated based on patient contraindications, co-morbidities, etc.).





PATIENT

Ophelia Wolfel

SPECIES

Feline

BREED

Domestic Longhair

SEX

Spayed Female

AGE

8 Years

WEIGHT

13.9 lbs

INTERPRETED BY

Beth Johnson, DVM
DACVIM

IMAGING PERFORMED BY

Meghan Morse, LVT,
CVT

HOSPITAL NAME

Kingston Animal
Hospital

REFERRING VET

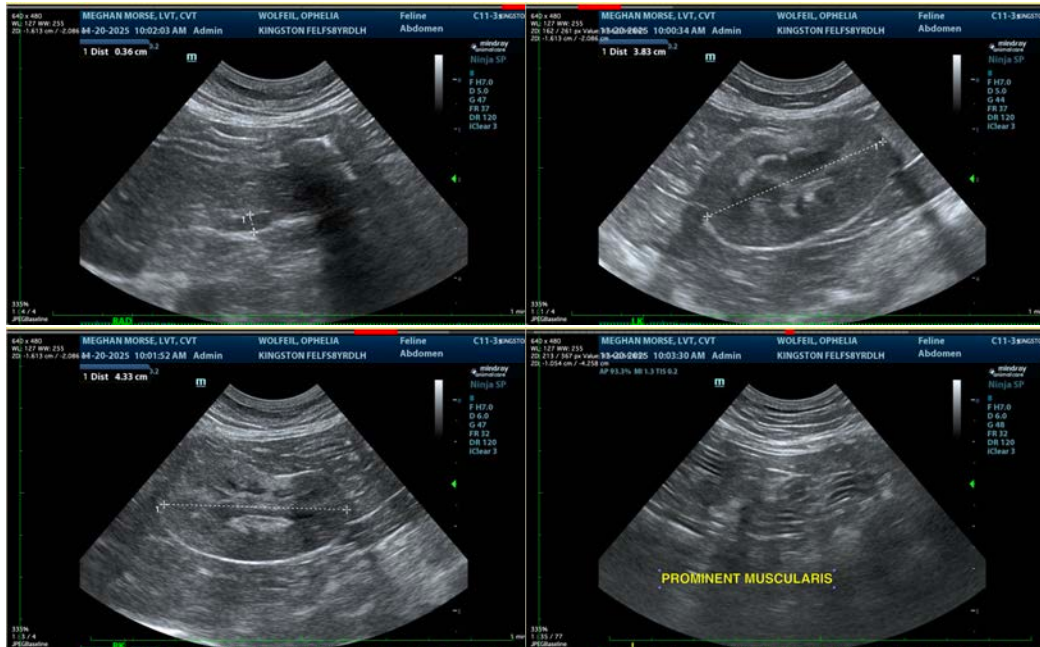Dr. Turner

INVOICE

72008

DATE

11/20/25



The information and recommendations provided are based on the images presented by the referring veterinarian/sonographer. No evaluation can be communicated regarding pathology that was not visible in the image/video clips provided.

Thank you for this referral. If the clinical or image interpretation does not parallel your findings or if I can be of any further assistance please contact me.

Beth Johnson, DVM, DACVIM
info@sonopath.com