

PATIENT

FloJo Keeney

SPECIES

Canine

BREED

Lab Retriever

SEX

Spayed Female

AGE

9 Years 2 Months

WEIGHT

57.4 lbs

INTERPRETED BY

Beth Johnson, DVM
 DACVIM

IMAGING PERFORMED BY

Kathleen Byrnes

HOSPITAL NAME

Stoney Creek
 Veterinary Hospital

REFERRING VET

Dr. Eldred

INVOICE

71986

DATE

11/20/25

PRESENTING CLINICAL SIGNS

P presented for US due to vomiting and diarrhea. P weighed 60.4# in October.

Abnormal PE/Chem/CBC/UA Results: 10/30/25 TP 4.9 (5.2-8.2), Amylase 1576 (500-1500) CBC Neu 11.7, Mono 11.4 11/20/25 TP normal, Amylase and Neutrophils mildly elevated

ULTRASONOGRAPHIC EXAMINATION OF THE ABDOMEN

Urinary System

The urinary bladder is adequately distended with anechoic contents. No masses, inflammatory changes, echogenic sediment or cystoliths are observed. The urinary bladder, trigone and visible pelvic urethra are normal in thickness with a smooth mucosal surface.

The right kidney is normal is size (6.0 cm), shape and echogenicity. It has smooth peripheral margination. There is a normal 1:3 cortex to medulla ratio with appropriate corticomedullary distinction. There is no evidence of pyelectasia, mineral or infarcts observed.

The left kidney is normal is size (5.77 cm), shape and echogenicity. It has smooth peripheral margination. There is a normal 1:3 cortex to medulla ratio with appropriate corticomedullary distinction. There is no evidence of pyelectasia, mineral or infarcts observed.

Adrenal Glands

The right adrenal gland is normal in size (0.82 cm at cranial pole and 0.54 cm at caudal pole), shape and overall architecture, echogenicity and echotexture. Visible surrounding vasculature appears normal.

The left adrenal gland is normal in size (0.48 cm at cranial pole and 0.50 cm at caudal pole), shape and overall architecture, echogenicity and echotexture. Visible surrounding vasculature appears normal.

Spleen

The spleen is subjectively normal in size (2.2 cm thick at the hilus) with a normal smooth capsular contour. Parenchyma is appropriately finely textured and homogenous with normal echogenicity relative to surrounding tissue (hyperechoic to liver). No focal nodules or masses are observed. Splenic vasculature appears normal.

Liver

The liver is subjectively mildly enlarged with mildly irregular margins, primarily in the mid to right caudal liver. Adjacent to the gallbladder there is a very subtly rounded, approximately 2.8 cm x 3.2 cm homogeneous, isoechoic density/rounded lobe. The remaining parenchyma is normal with smooth curvilinear peripheral contour and a parenchyma appropriately hypoechoic to the spleen in echogenicity and appropriately mildly coarse and homogenous in echotexture. Visible vasculature and biliary tree appear normal without distension or congestion.

Gallbladder is moderately distended with anechoic bile as well as suspended and gravity dependent echogenic debris. The wall is smooth without visible thickening. There is no evidence of cystic or CBD dilation. There is no evidence of effusion or inflammation.



PATIENT

FloJo Keeney

SPECIES

Canine

BREED

Lab Retriever

SEX

Spayed Female

AGE

9 Years 2 Months

WEIGHT

57.4 lbs

INTERPRETED BY

Beth Johnson, DVM
 DACVIM

IMAGING PERFORMED BY

Kathleen Byrnes

HOSPITAL NAME

Stoney Creek
 Veterinary Hospital

REFERRING VET

Dr. Eldred

INVOICE

71986

DATE

11/20/25

Gastrointestinal

The visible stomach wall is normal in thickness and layering. The lumen of the stomach is mildly distended with a small to moderate amount of echogenic non-shadowing luminal contents and gas consistent with normal ingesta. There is no evidence of obstruction, foreign material or infiltrative disease. Pyloric outflow tract appears patent.

The visible small intestines are normal in wall thickness and layering. Small intestinal motility appears adequate (1-3 contractions per min). The lumen is mildly distended with echogenic non-shadowing luminal contents and gas consistent with normal ingesta/chyme. There is no evidence of obstruction, foreign material or infiltrative disease.

The visible colon is normal in wall thickness (< 0.2 cm) and layering. Contents are consistent with normal formed feces and gas.

Pancreas

The pancreas that is observed appears appropriately isoechoic to surrounding omental fat. Visible capsule is smooth and normal in contour. Visible pancreatic parenchyma is homogenous and unremarkable. There is no visible pancreatic duct dilation. There is no evidence of active peripancreatic inflammation.

Free Abdomen

There is no visible free peritoneal effusion noted in these images.

Medial iliac lymph nodes are prominent in size with swollen capsular contour. Normal elongated shape (length to width ratio) is maintained. There is no loss of parenchymal detail.

ULTRASONOGRAPHIC FINDINGS

- The subtle liver changes are mild and could represent a benign process such as nodular hyperplasia, steroid or vacuolar hepatopathy, extramedullary hematopoiesis, or even chronic inflammatory disease, with infiltrative round cell or metastatic neoplasia versus other neoplasia being possible but considered less likely.
- Mild gallbladder debris - Cholecystic debris is of unknown clinical significance. It can be seen with biliary stasis from fasting or illness. Cholecystic debris is not necessarily related to hepatobiliary disease. Echogenic bile is most commonly an incidental finding in dogs and should be interpreted in combination with clinical signs such as nausea, inappetence, cranial abdominal discomfort and/or laboratory changes such as increased ALP and/or increased Tbili.
- Moderately reactive suspect medial iliac lymph nodes – infiltrative neoplastic disease cannot be ruled out but is considered less likely.

INTERPRETATION OF THE FINDINGS & FURTHER RECOMMENDATIONS

Three view thoracic radiographs are recommended for further assessment of cardio-pulmonary status as well as to further evaluate for any evidence of metastatic disease, if not recently evaluated.

Fine needle aspirates of the mid to right caudal liver could be considered if patient's coagulation status is appropriate.



PATIENT

FloJo Keeney

Having said that, I suspect those changes are unrelated to patient's presenting complaint, and therefore further gastrointestinal workup recommendations include a routine fecal/giardia exam if not recently evaluated.

SPECIES

Canine

A gastrointestinal malabsorption panel (including cobalamin, folate, TLI and PLI) to Texas A&M GI Laboratory is recommended for further evaluation of GI and pancreatic function.

BREED

Lab Retriever

A fecal enteropathogen PCR panel to Texas A&M GI Laboratory could be considered for further evaluation of possible infectious disease. Contact lab for recommendations on how long to discontinue antibiotics (if indicated) prior to obtaining a stool sample for submission.

SEX

Spayed Female

In the meantime:

- Supportive/symptomatic medical management of clinical signs is recommended, including anti-emetics, gastroprotectants (+/- sucralfate, especially with any history of hematemesis), an appetite stimulant and fluid therapy if indicated, etc.

AGE

9 Years 2 Months

- Additionally, empirical deworming with a 5-day course of Panacur is recommended.

WEIGHT

57.4 lbs

- A full course of empirical Helicobacter triple therapy could be considered.

- A probiotic, such a visbiome or proviable, may be helpful.

- Finally, if tolerated, a transition in diet could be considered, based on trial-and-error response with some options to consider including a gastrointestinal biome diet vs a hydrolyzed protein diet (sometimes several trials with different brands are necessary) vs an easy to digest, bland or low-fat diet vs other.

INTERPRETED BY

Beth Johnson, DVM
 DACVIM

IMAGING PERFORMED BY

Kathleen Byrnes

HOSPITAL NAME

Stoney Creek
 Veterinary Hospital

REFERRING VET

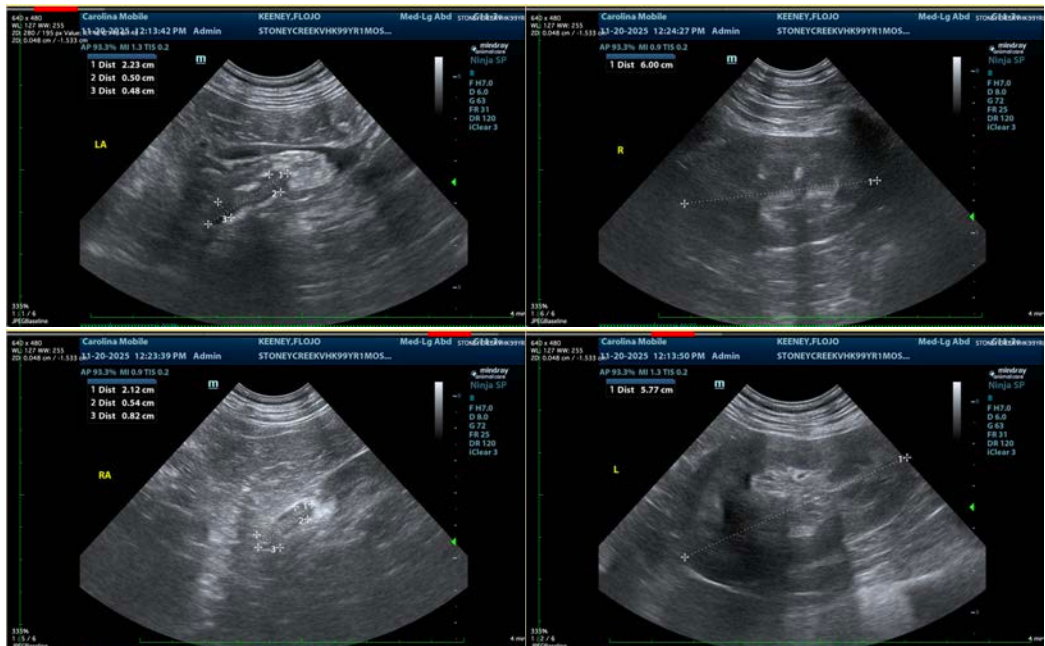
Dr. Eldred

INVOICE

71986

DATE

11/20/25





PATIENT

FloJo Keeney

SPECIES

Canine

BREED

Lab Retriever

SEX

Spayed Female

AGE

9 Years 2 Months

WEIGHT

57.4 lbs

INTERPRETED BY

Beth Johnson, DVM
 DACVIM

IMAGING PERFORMED BY

Kathleen Byrnes

HOSPITAL NAME

Stoney Creek
 Veterinary Hospital

REFERRING VET

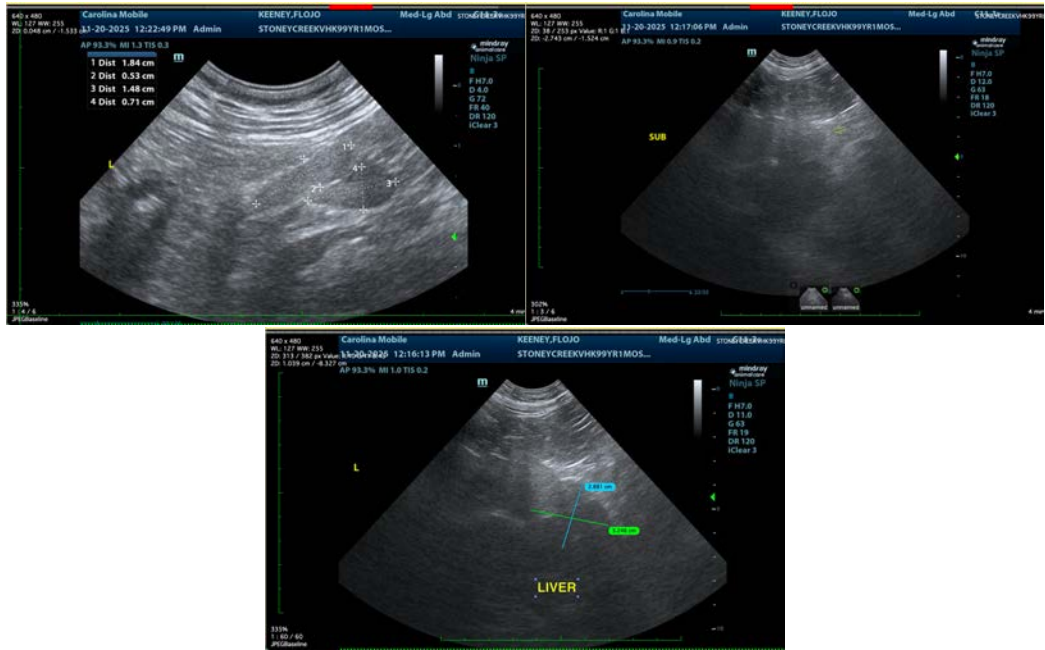
Dr. Eldred

INVOICE

71986

DATE

11/20/25



The information and recommendations provided are based on the images presented by the referring veterinarian/sonographer. No evaluation can be communicated regarding pathology that was not visible in the image/video clips provided.

Thank you for this referral. If the clinical or image interpretation does not parallel your findings or if I can be of any further assistance please contact me.

Beth Johnson, DVM, DACVIM
 info@sonopath.com