



PATIENT

Chloe Buckles

SPECIES

Canine

BREED

Lhasa Apso

SEX

Spayed Female

AGE

14 Years

WEIGHT

13.6 lbs

INTERPRETED BY

Beth Johnson, DVM
DACVIM

IMAGING PERFORMED BY

Meghan Morse, LVT,
CVT

HOSPITAL NAME

VCA HoHoKus
Veterinary Hospital

REFERRING VET

Dr. Gannon

INVOICE

72010

DATE

11/20/25

PRESENTING CLINICAL SIGNS

Recheck echo, alt slightly elevated, hx of GI issues- has been on low fat I/D
Abnormal PE/Chem/CBC/UA Results: ALT 523

ULTRASONOGRAPHIC EXAMINATION OF THE ABDOMEN

Urinary System

The urinary bladder is only mildly distended/empty. Visible contents are anechoic except for one 0.20 cm in diameter echogenic density/possible small cystolith. The urinary bladder wall is unable to be fully assessed for pathology without further distention. No visible masses observed. The trigone and visible pelvic urethra are normal in thickness with a smooth mucosal surface.

Kidneys are overall normal in size and shape with smooth peripheral margination. A normal 1:3 cortex to medulla ratio is maintained. The medulla and cortices are uniform in texture with some mild increased cortical echogenicity and mild loss of corticomedullary distinction, expected in this age patient. There is no evidence of pyelectasia or infarcts observed. Left kidney measures 3.77 cm. Right kidney measures 3.83 cm. Pinpoint non-obstructive nephroliths are noted bilaterally.

Adrenal Glands

The right adrenal gland is normal in size (0.96 cm at cranial pole and 0.65 cm at caudal pole), shape and overall architecture, echogenicity and echotexture. Visible surrounding vasculature appears normal.

The left adrenal gland is normal in size (0.44 cm at cranial pole and 0.51 cm at caudal pole), shape and overall architecture, echogenicity and echotexture. Visible surrounding vasculature appears normal.

Spleen

The spleen is subjectively normal in size with a normal smooth capsular contour. Parenchyma is appropriately finely textured and homogenous with normal echogenicity relative to surrounding tissue (hyperechoic to liver). No focal nodules or masses are observed. Splenic vasculature appears normal.

Liver

The liver is subjectively normal in size with normal smooth curvilinear peripheral contour. Parenchyma is appropriately hypoechoic to the spleen in echogenicity and appropriately mildly coarse and homogenous in echotexture, except for a small 0.46 cm in diameter anechoic density/cyst in the mid liver. Visible vasculature and biliary tree appear normal without distension or congestion.

The gallbladder is non-distended in size. The wall is smooth without visible thickening. Luminal contents are primarily anechoic. There is no evidence of cystic or common bile duct dilation.

Gastrointestinal

The visible stomach wall is normal in thickness and layering. The lumen of the stomach is empty with no evidence of obstruction, foreign material or infiltrative disease. Pyloric outflow tract appears patent.

The visible small intestines are normal in wall thickness and layering. Small intestinal motility appears adequate (1-3 contractions per min). The lumen of the small intestine is empty with no evidence of obstruction, foreign material or infiltrative disease.



PATIENT

Chloe Buckles

The visible colon is normal in wall thickness (< 0.2 cm) and layering. Contents are consistent with normal formed feces and gas.

SPECIES

Canine

Pancreas

The pancreas that is observed appears appropriately isoechoic to surrounding omental fat. Visible capsule is smooth and normal in contour. Visible pancreatic parenchyma is homogenous and unremarkable. There is no visible pancreatic duct dilation. There is no evidence of active peripancreatic inflammation.

BREED

Lhasa Apso

Free Abdomen

There is no visible free peritoneal effusion noted in these images.

SEX

Spayed Female

There is no apparent pathologic lymphadenopathy noted in these images.

AGE

14 Years

PRIMARY FINDINGS

- Suspect incidental hepatic cyst. Otherwise, an obvious cause for the reported increased liver enzymes is not identified in these images. Microscopic disease such as Leptospirosis, bacterial cholangiohepatitis, chronic active hepatitis, copper-associated hepatotoxicity, other hepatotoxicity, other reactive hepatopathy, infiltrative neoplasia (considered unlikely), etc. cannot be definitively ruled out.

WEIGHT

13.6 lbs

SECONDARY FINDINGS

- Age related kidney changes with pinpoint non-obstructive nephroliths bilaterally.
- Suspect small cystolith.

INTERPRETED BY

Beth Johnson, DVM
DACVIM

INTERPRETATION OF THE FINDINGS & FURTHER RECOMMENDATIONS

Differentials for a primary hepatocellular injury liver enzyme pattern (increased ALT) depend partially on the level of increase. Mild increases (less than 2 times normal) are often a “reactive hepatopathy” or the liver’s response to an insult elsewhere in the body including, but not limited to, pancreatitis, gastroenteritis, parasitic disease, dental disease, vacuolar or endocrine hepatopathy from diabetes mellitus or hyperadrenocorticism (steroid-induced), hypoadrenocorticism, certain drugs (e.g. phenobarbital, corticosteroids, azathioprine, etc.), and muscle ALT (more likely if AST and CK concurrently increased).

IMAGING PERFORMED BY

Meghan Morse, LVT,
CVT

It is a good indicator of active liver damage (cell membrane disruption, cellular necrosis), however, if the value is increased by at least 3-4 times normal. Differentials include infectious disease, including Leptospirosis, inflammatory disease (ie. active hepatitis, copper, other), toxic insult as well as infiltrative neoplasia.

HOSPITAL NAME

VCA HoHoKus
Veterinary Hospital

ALT levels vary in cases of vascular anomalies such as microvascular dysplasia and portosystemic shunts (PSS), but are often less significantly increased.

REFERRING VET

Dr. Gannon

INVOICE

72010

- Testing for Leptospirosis could be considered.
- Bile acids could be considered, if tбили is not increased.

DATE

11/20/25

- An empirical course of antibiotics and empirical hepatic nutraceuticals may be tried, with monitoring of ALT for improvement. If improvement is noted, antibiotics should be continued until liver enzymes either normalize or plateau (recheck every 2-3 weeks); however, if improvement is



PATIENT

Chloe Buckles

SPECIES

Canine

BREED

Lhasa Apso

SEX

Spayed Female

AGE

14 Years

WEIGHT

13.6 lbs

INTERPRETED BY

Beth Johnson, DVM
 DACVIM

IMAGING PERFORMED BY

Meghan Morse, LVT,
 CVT

HOSPITAL NAME

VCA HoHoKus
 Veterinary Hospital

REFERRING VET

Dr. Gannon

INVOICE

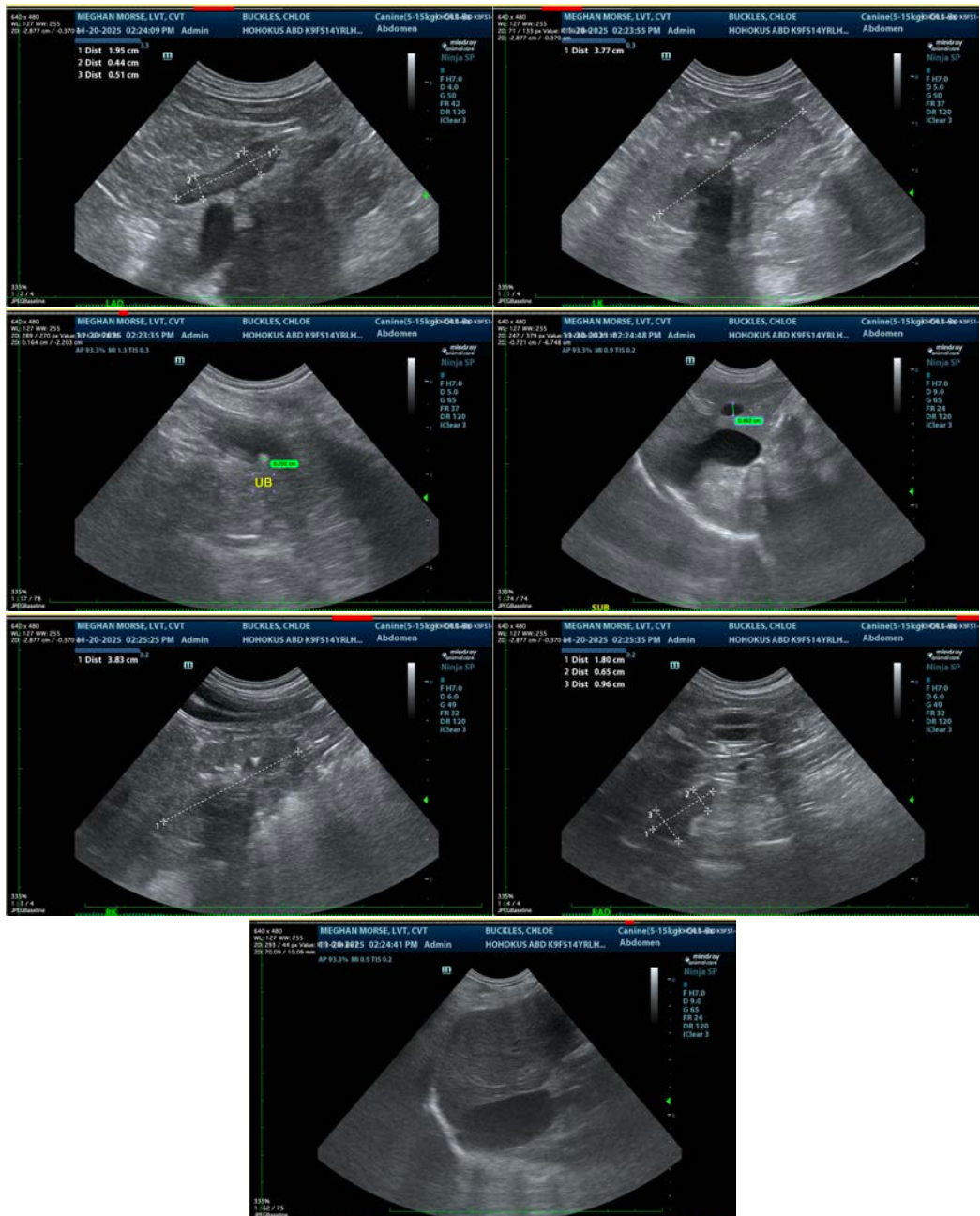
72010

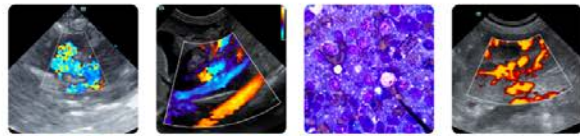
DATE

11/20/25

not noted and/or enzyme increase progresses, antibiotics should not be continued long term and liver tissue sampling is recommended.

- FNA of the liver can be performed to assess inflammatory cell type, rule in/out round cell neoplasia, etc. (if patient's coagulation status is appropriate).
- If round cell neoplasia is not diagnosed, a liver biopsy (including copper level assessment) may be required to definitively diagnose the underlying hepatopathy.





PATIENT

Chloe Buckles

SPECIES

Canine

BREED

Lhasa Apso

SEX

Spayed Female

AGE

14 Years

WEIGHT

13.6 lbs

INTERPRETED BY

Beth Johnson, DVM
DACVIM

IMAGING PERFORMED BY

Meghan Morse, LVT,
CVT

HOSPITAL NAME

VCA HoHoKus
Veterinary Hospital

REFERRING VET

Dr. Gannon

INVOICE

72010

DATE

11/20/25

The information and recommendations provided are based on the images presented by the referring veterinarian/sonographer. No evaluation can be communicated regarding pathology that was not visible in the image/video clips provided.

Thank you for this referral. If the clinical or image interpretation does not parallel your findings or if I can be of any further assistance please contact me.

Beth Johnson, DVM, DACVIM
info@sonopath.com