

**DATE PRESENTING CLINICAL SIGNS**

11/2/22

Patient presented on 10/19/22 for urinating frequently as well as leaking urine for 1-2 months in duration. Owner reported that pet would whine and push a lot while urinating. On PE pet was found to be obese but had lost 5lbs since last year. Severe dental calculus and gingivitis was noted. Organomegaly with abdominal distension (no associated pain) was noted on abdominal palpation. On brief US for cystocentesis an echogenic discrete mass was visualized within the bladder.

PATIENT

Amber Wertz

SPECIES

Canine

BREED

Pug X

SEX

Spayed Female

AGE

8/8/11

WEIGHT

19.94 Pounds

INTERPRETED BY

Kathleen Sennello DVM,
MS, Diplomate ACVIM
(Small Animal Internal
Medicine)

IMAGING PERFORMED BY

Rachel Brilhart RDMS

HOSPITAL NAME

Westminster VH

REFERRING VET

Dr. Hall

INVOICE

42502

Current Medications: None.

Lab Results: 10/20/22: CBC: Retic Hemoglobin: 24pg (24.5-31.8); Monocytes 1.336K/uL (0.13-1.15); Platelets: 482K/uL (143-448); CHEM: Chloride: 106mmol/L (108-119); ALT: 182U/L (18-121); ALP: 538U/L (5-160); GGT: 16U/L (0-13); CK: 344U/L (10-200); UA: SG: 1.020; pH: 6.0; Protein 2+; Blood: 2+; WBC: 2-5; RBC: 30-50; bacteria rare cocci; Epi Cell: 2+; Mucus: present

Date of Previous IntraPet Ultrasound: No previous.

Sedation: Not required to complete full diagnostic ultrasound.

Stat Report: Not requested.

ULTRASONOGRAPHIC EXAMINATION OF THE ABDOMEN**Urinary System**

Urinary bladder is adequately distended with primarily anechoic contents. There is a solitary sessile heterogenous vascular mass lesion (4.0 cm long x 2.0 cm thick), reaching from the trigone almost all the way to the apex of the urinary bladder. No cystoliths are observed.

The right kidney measures 6.13 cm long. A thin rim of renal cortex is the only tissue present, surrounding a markedly fluid dilated renal pelvis/collecting system. Narrow bands of hyperechoic tissue extend from the capsule towards the hilus.

The left kidney is normal in size (4.63 cm), shape and echogenicity. It has smooth peripheral margination. There is a normal 1:3 cortex to medulla ratio with appropriate corticomedullary distinction. There is no evidence of pyelectasia or infarcts observed. Non-obstructive linear multifocal hyperechoic diverticular foci with acoustic shadowing are noted.

Adrenal Glands

The right adrenal gland is normal in size (2.45 cm long x 0.54 cm at the cranial pole and 0.67 cm at the caudal pole), shape and contour. Corticomedullary structure is unremarkable. Visible surrounding vasculature appears normal.

The left adrenal gland is normal in size (2.0 cm long x 0.65 cm at the cranial pole and 0.87 cm at the caudal pole), shape and contour. Corticomedullary structure is unremarkable. Visible surrounding vasculature appears normal.

Spleen

The spleen is subjectively normal in size with a normal smooth capsular contour. Parenchyma is appropriately finely textured and homogenous with normal echogenicity relative to surrounding tissue (hyperechoic to liver). No focal nodules or masses are observed. Splenic vasculature appears normal.

Liver

Liver is subjectively enlarged with mildly irregular margins. Parenchyma is diffusely heterogenous characterized by multiple poorly defined hypoechoic nodules within otherwise hyperechoic liver parenchyma. A discrete focal vascular mass is noted in the deep mid liver that is heterogeneous and slightly hypoechoic in appearance, measuring 5.0 cm x 6.0 cm in size. Visible vasculature and biliary tree appear normal without distension or congestion.

Gallbladder is moderately distended with anechoic bile as well as suspended and gravity dependent echogenic debris. The wall is smooth without visible thickening. There is no evidence of cystic or CBD dilation. There is no evidence of effusion or inflammation.

Gastrointestinal

The stomach wall is normal in thickness (canine < 0.5 cm and feline < 0.4 cm) and layering. The lumen of the stomach is empty with no evidence of obstruction, foreign material or infiltrative disease. Pyloric outflow tract appears patent.

The visible small intestines are normal in wall thickness and layering. Hyperechoic mucosal fogging or speckling is noted. Small intestinal motility appears adequate (1-3 contractions per min).

The visible colon is normal in wall thickness (< 0.2 cm) and layering. Contents are consistent with normal formed feces and gas.

Pancreas

The pancreatic parenchyma is appropriately isoechoic to surrounding tissue. Visible capsule is smooth and normal in contour. There is no visible pancreatic duct dilation. There is no evidence of active peripancreatic inflammation.

Free Abdomen

There is no evidence of free peritoneal effusion noted in these images.

There is no apparent lymphadenopathy noted in these images.

PRIMARY FINDINGS

- **Urinary bladder mass with an obstructed right ureter resulting in hydroureter and hydronephrosis on the right side** – Urinary bladder wall changes are most concerning for infiltrative neoplasia such as transitional cell carcinoma vs other. Benign inflammatory disease (cystitis) cannot be ruled out but is considered less likely given the location and appearance of the tissue.
- **Diffusely heterogenous Liver with a discrete mass** – Concerning for infiltrative malignant neoplasia such as a primary hepatocellular carcinoma. A metastatic lesion, sarcoma, round cell neoplasia, etc. are also possible. A benign liver mass/lesion is possible but considered slightly less likely.

SECONDARY FINDINGS

- **Gallbladder debris** - Cholecystic debris is of unknown clinical significance. It can be seen with biliary stasis from fasting or illness. Cholecystic debris is not necessarily related to hepatobiliary disease. Echogenic bile is most commonly an incidental finding in dogs and should be interpreted in combination with clinical signs such as nausea, inappetence, cranial abdominal discomfort and/or laboratory changes such as increased ALP and/or increased Tbili.
- **Mucosal speckling** – Mucosal speckling is often present with inflammatory bowel disease (IBD). It is not specific for type or severity of disease. Mild speckling change can occur as a normal patient variant in the post-prandial state.

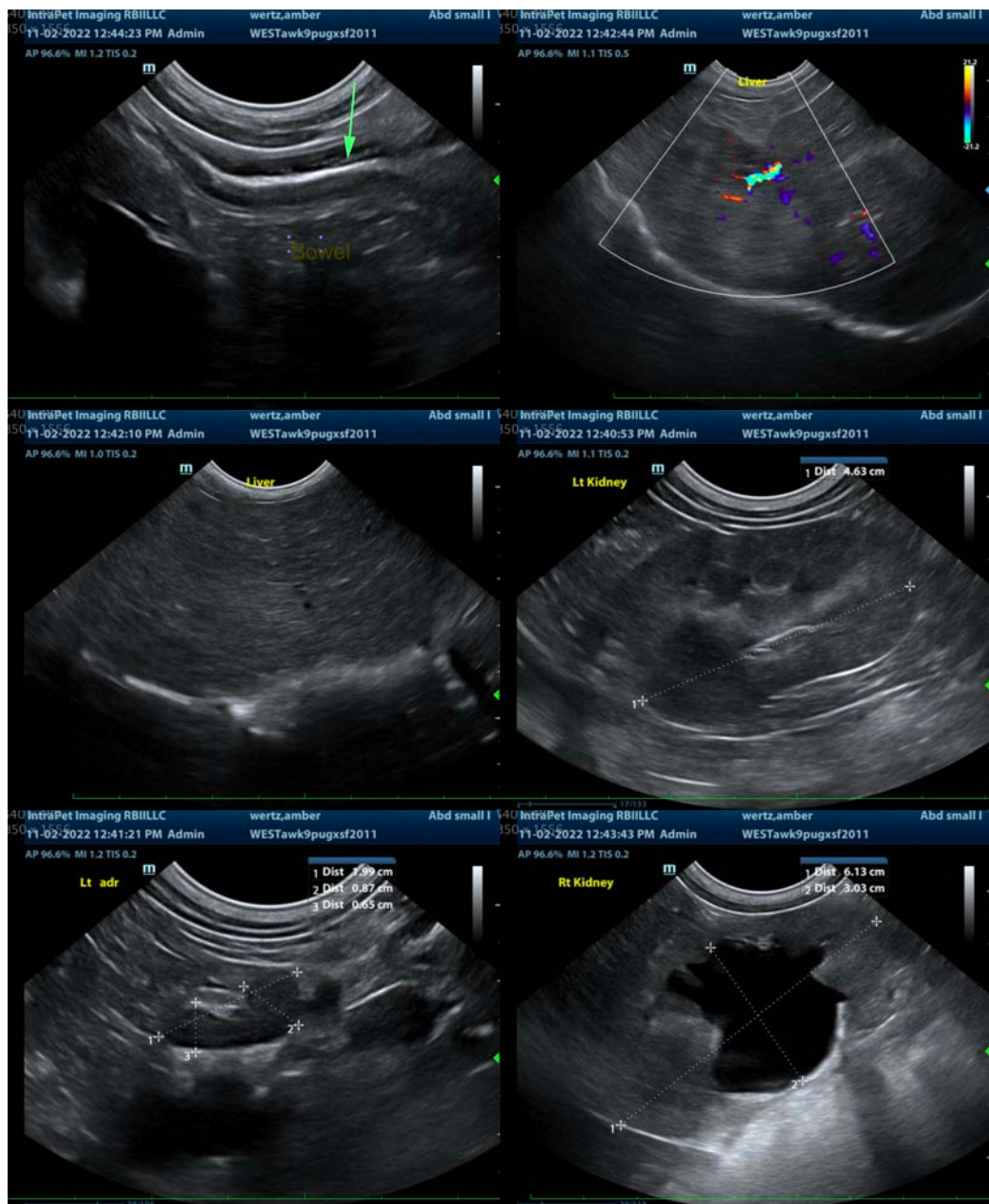
INTERPRETATION OF THE FINDINGS & FURTHER RECOMMENDATIONS

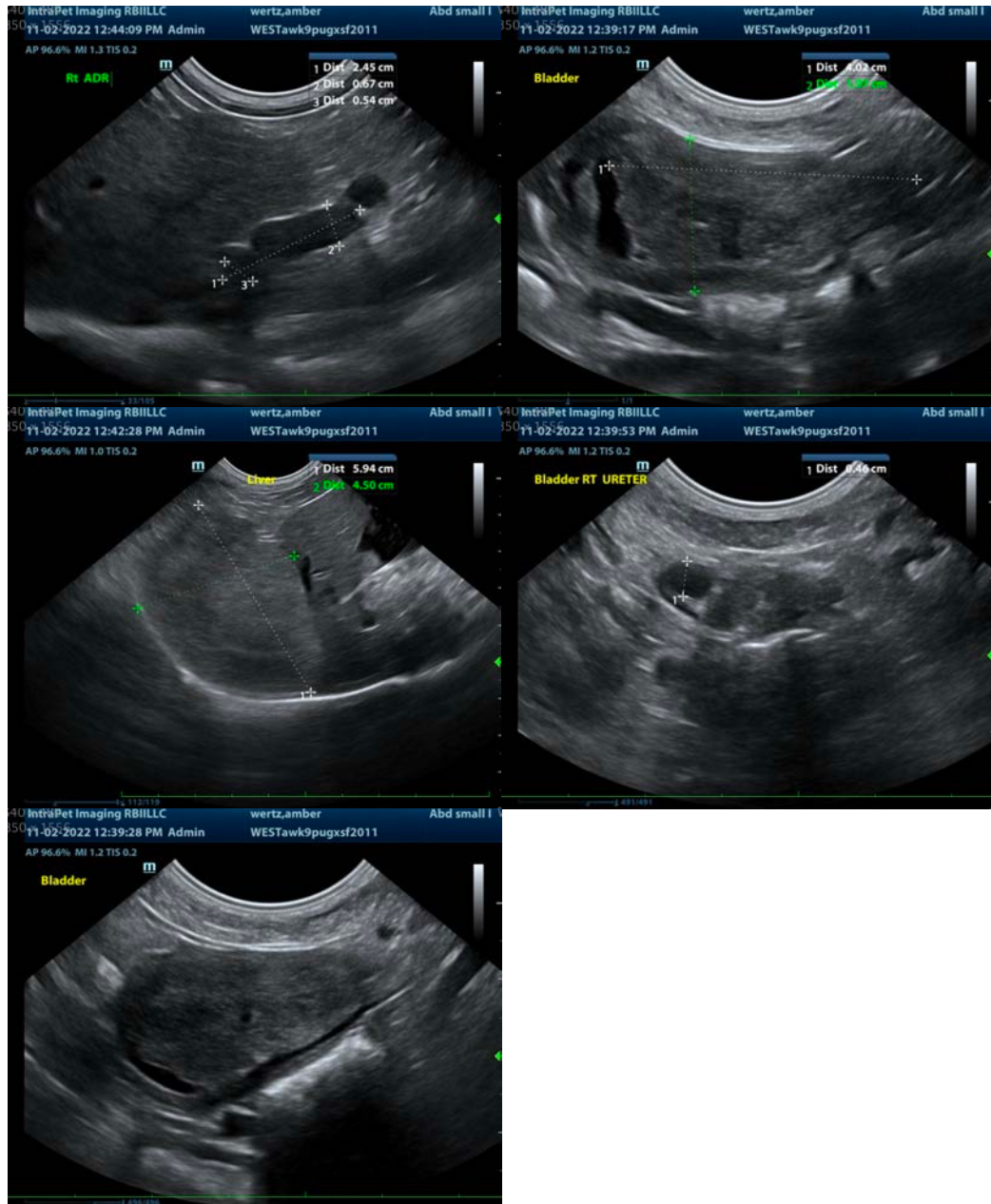
Three view thoracic radiographs are recommended for further assessment of cardio-pulmonary status as well as to further evaluate for any evidence of metastatic disease, if not recently evaluated.

Urinalysis and urine culture, if indicated based on urinalysis results, are recommended. Submission of urine to look for BRAF gene mutation, which is associated with urinary bladder cancer, could be considered. Other diagnostic options include traumatic catheterization, fine needle aspirate (with small risk of tumor seeding/trailing) or cystoscopy for further sampling.

A fine needle aspirate of the liver mass is recommended if patient's coagulation status is appropriate.

In the meantime, antibiotics, ideally based on culture and sensitivity results, and an anti-inflammatory may help begin alleviating some of the urinary clinical signs while waiting for results, and ultimately consultation with an oncologist.





The information and recommendations provided are based on the images presented by the referring veterinarian/sonographer. No evaluation can be communicated regarding pathology that was not visible in the image/video clips provided.

Thank you for this referral. If the clinical or image interpretation does not parallel your findings or if I can be of any further assistance please contact me.

Beth Johnson, DVM, DACVIM
Beth.Johnson@sonopath.com