



PATIENT

Newt Duschinsky

SPECIES

Canine

BREED

Husky x

SEX

Neutered Male

AGE

10 Years

WEIGHT

27.5 kg

INTERPRETED BY

Beth Johnson, DVM
 DACVIM

IMAGING PERFORMED BY

Amanda Stewart

HOSPITAL NAME

Woodstock Veterinary
 Hospital

REFERRING VET

Dr Duschinsky

INVOICE

71933

DATE

11/19/25

PRESENTING CLINICAL SIGNS

Chronic history of intermittent vomiting and inappetence that previously responded to short courses of prednisone and a hypo diet. - The patient presented five days ago on November 14/2025 for vomiting and anorexia.. Abdominal rads were relatively NAF other than a suspicious area around the stomach. - Hospital treatment included IV fluids, maropitant injections, methadone, and pradofloxacin. - Nausea, vomiting, and discomfort continued for two days before gradually improving. Meds: Cerenia 60mg SID, injectable methadone and gabapentin alternating, 2 nights ago started SAMY SID, Ursodiol 250mg SID, Veraflox SID 90mg

Abnormal PE/Chem/CBC/UA Results: See attached BW .. In September 2025, diagnostics revealed hypocobalaminemia, a mild elevation in ALT, and a moderate elevation in ALKP. - Initial bloodwork was consistent with pancreatitis, with mild elevations in liver enzymes and evidence of marked inflammation and/or infection on the CBC

ULTRASONOGRAPHIC EXAMINATION OF THE ABDOMEN

Urinary System

The urinary bladder is adequately distended with anechoic contents. No masses, inflammatory changes, echogenic sediment or cystoliths are observed. The urinary bladder, trigone and visible pelvic urethra are normal in thickness with a smooth mucosal surface.

Prostate is normal in size, echotexture and echogenicity for a neutered male.

The right kidney is normal is size (6.51 cm), shape and echogenicity. It has smooth peripheral margination. There is a normal 1:3 cortex to medulla ratio with appropriate corticomedullary distinction. There is no evidence of pyelectasia, mineral or infarcts observed.

The left kidney is normal is size (6.24 cm), shape and echogenicity. It has smooth peripheral margination. There is a normal 1:3 cortex to medulla ratio with appropriate corticomedullary distinction. There is no evidence of pyelectasia, mineral or infarcts observed.

Adrenal Glands

The right adrenal gland is normal in size (1.0 cm at cranial pole and 0.69 cm at caudal pole), shape and overall architecture, echogenicity and echotexture. Visible surrounding vasculature appears normal.

The left adrenal gland is normal in size (0.60 cm at cranial pole and 0.60 cm at caudal pole), shape and overall architecture, echogenicity and echotexture. Visible surrounding vasculature appears normal.

Spleen

Spleen is subjectively normal in size with a normal smooth capsular contour. Parenchyma is appropriately finely textured and homogenous with normal echogenicity relative to surrounding tissue (hyperechoic to liver). Multifocal well-demarcated hyperechoic homogenous nodules are noted. Splenic vasculature appears normal.

Liver

The liver is subjectively normal in size with normal smooth curvilinear peripheral contour. Parenchyma is appropriately hypoechoic to the spleen in echogenicity and appropriately mildly coarse and



PATIENT

Newt Duschinsky

homogenous in echotexture. No focal lesions are observed. Visible vasculature and biliary tree appear normal without distension or congestion.

SPECIES

Canine

The gallbladder is non-distended in size. The wall is smooth without visible thickening. Luminal contents are primarily anechoic. There is no evidence of cystic or common bile duct dilation.

BREED

Husky x

Gastrointestinal

The visible stomach wall is normal in thickness and layering. The lumen of the stomach is empty with no evidence of obstruction, foreign material or infiltrative disease. Pyloric outflow tract appears patent.

SEX

Neutered Male

The visible small intestines are normal in wall thickness and layering. Small intestinal motility appears adequate (1-3 contractions per min). The lumen of the small intestine is empty with no evidence of obstruction, foreign material or infiltrative disease.

AGE

10 Years

The visible colon is normal in wall thickness (< 0.2 cm) and layering. Contents are consistent with normal formed feces and gas.

WEIGHT

27.5 kg

Pancreas

The observed pancreas is prominent (enlarged) in size, hypoechoic to surrounding tissue and irregular in shape with a swollen undulating contour. Enhanced hyperechoic ill-defined surrounding fat is noted.

*This change is most visible in the left limb.

INTERPRETED BY

Beth Johnson, DVM
 DACVIM

Free Abdomen

There is no visible free peritoneal effusion noted in these images.

There is no apparent pathologic lymphadenopathy noted in these images.

IMAGING PERFORMED BY

Amanda Stewart

PRIMARY FINDINGS

- Suspect moderate to severe acute pancreatitis. Necrotizing pancreatitis can't be ruled out.

HOSPITAL NAME

Woodstock Veterinary
 Hospital

SECONDARY FINDINGS

- Hyperechoic splenic nodules – most consistent with benign myelolipomas. Other differentials such as fibrosis or calcification caused by old hematomas or infarcts, chronic inflammation, granulomatous disease or metastatic disease cannot be ruled out, but are considered less likely.

REFERRING VET

Dr Duschinsky

INTERPRETATION OF THE FINDINGS & FURTHER RECOMMENDATIONS

Fine needle aspirates of the pancreas +/- liver could be considered if patient's coagulation status is appropriate.

INVOICE

71933

In the meantime, medical management of pancreatitis with anti-emetics, gastroprotectants, appetite stimulants or nutritional support as needed, pain management, broad spectrum antibiotics, and fluid therapy is recommended. If possible, a fresh frozen plasma transfusion and hyperbaric oxygen therapy (HBOT) could be beneficial. Monitoring of the pancreas with power doppler is recommended to identify possible necrosis as well as other potential sequelae such as abscesses, etc.

DATE

11/19/25



PATIENT

Newt Duschinsky

SPECIES

Canine

BREED

Husky x

SEX

Neutered Male

AGE

10 Years

WEIGHT

27.5 kg

INTERPRETED BY

Beth Johnson, DVM
 DACVIM

IMAGING PERFORMED BY

Amanda Stewart

HOSPITAL NAME

Woodstock Veterinary
 Hospital

REFERRING VET

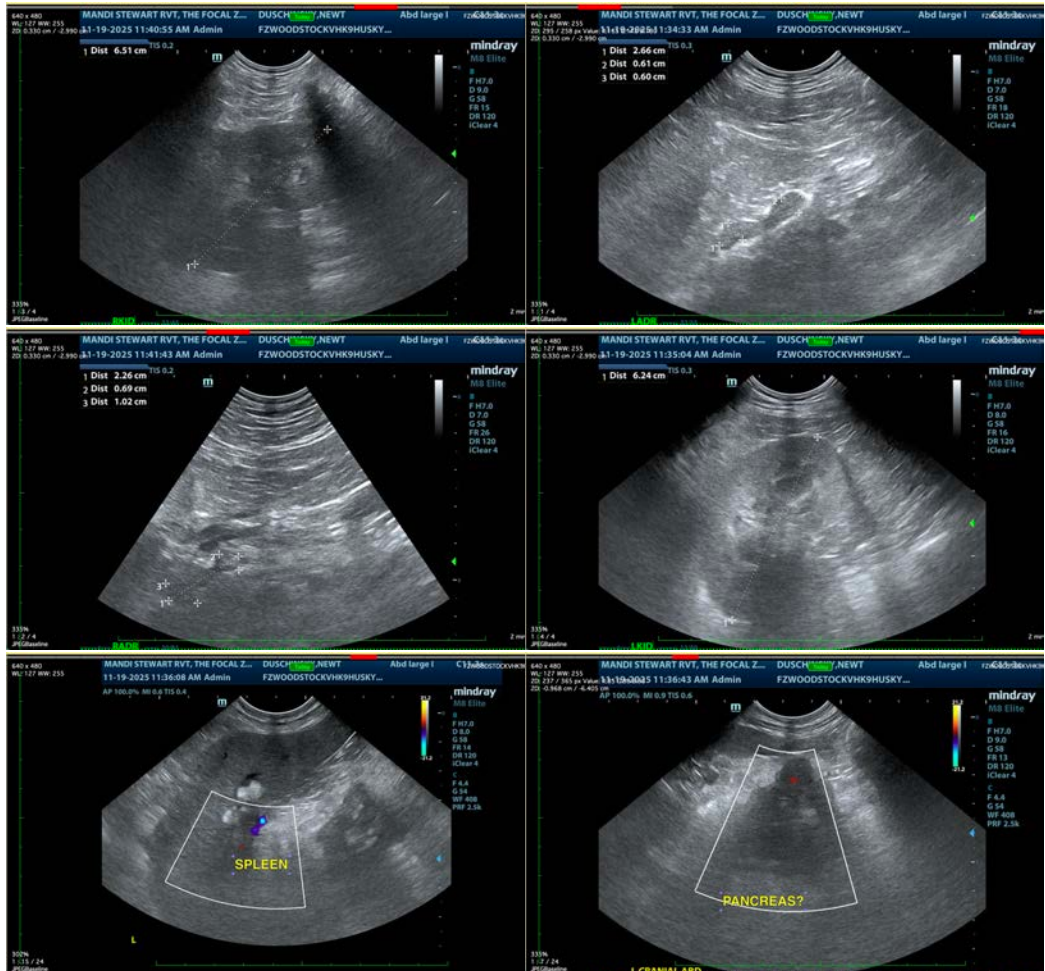
Dr Duschinsky

INVOICE

71933

DATE

11/19/25



The information and recommendations provided are based on the images presented by the referring veterinarian/sonographer. No evaluation can be communicated regarding pathology that was not visible in the image/video clips provided.

Thank you for this referral. If the clinical or image interpretation does not parallel your findings or if I can be of any further assistance please contact me.

Beth Johnson, DVM, DACVIM
 info@sonopath.com