



PATIENT

Max Dyer

SPECIES

Canine

BREED

Bulldog x

SEX

Neutered Male

AGE

3 Years 6 Months

WEIGHT

12.8 kg

INTERPRETED BY

Beth Johnson, DVM
DACVIM

IMAGING PERFORMED BY

Dr. Brian Barnes

HOSPITAL NAME

Westview Veterinary
Hospital

REFERRING VET

Dr. Brian Barnes

INVOICE

71951

DATE

11/19/25

PRESENTING CLINICAL SIGNS

R/C AUS Previous AUS results Jan 2025 1) History of mild increase in ALT after possible mushroom injection June 2024 2) Splenomegaly, 3) Moderate GB debris 4) Subtle bilateral medullary rim sign Has corneal ulcer from trauma

Abnormal PE/Chem/CBC/UA Results: R/C bloods today CBC Normal, ALT 160 History of elevated ALT Mar 2025 206 May 2024 193, 153 June 2025 BA panel normal. lepto Normal

ULTRASONOGRAPHIC EXAMINATION OF THE ABDOMEN

Urinary System

The urinary bladder is adequately distended with anechoic contents. No masses, inflammatory changes, echogenic sediment or cystoliths are observed. The urinary bladder, trigone and visible pelvic urethra are normal in thickness with a smooth mucosal surface.

Prostate is normal in size, echotexture and echogenicity for a neutered male.

The right kidney is normal in size (4.32 cm), shape and echogenicity. It has smooth peripheral margination. There is a normal 1:3 cortex to medulla ratio with appropriate corticomedullary distinction. There is no evidence of pyelectasia, mineral or infarcts observed. A hyperechoic band parallel to the corticomedullary border is present.

The left kidney is normal in size (4.96 cm), shape and echogenicity. It has smooth peripheral margination. There is a normal 1:3 cortex to medulla ratio with appropriate corticomedullary distinction. There is no evidence of pyelectasia, mineral or infarcts observed. A hyperechoic band parallel to the corticomedullary border is present.

Adrenal Glands

The right adrenal gland is normal in size (0.91 cm at cranial pole and 0.68 cm at caudal pole), shape and overall architecture, echogenicity and echotexture. Visible surrounding vasculature appears normal.

The left adrenal gland is normal in size (0.37 cm at cranial pole and 0.35 cm at caudal pole), shape and overall architecture, echogenicity and echotexture. Visible surrounding vasculature appears normal.

Spleen

Spleen is subjectively large in size (2.0 cm thick at the hilus) with normal smooth margins. Parenchyma is normal in echogenicity with a diffusely coarse/heterogenous echotexture. No discrete sizable focal nodules or masses are observed. Splenic vasculature appears normal.

Liver

Liver is subjectively enlarged (swollen contour) with a diffusely mildly coarse architecture and subtly increased portal markings. Mildly mixed echogenic changes are noted diffusely. No focal lesions are observed. Visible vasculature and biliary tree appear normal without distension or congestion.

Gallbladder is moderately distended with anechoic bile as well as suspended and gravity dependent echogenic debris. The wall is smooth without visible thickening. There is no evidence of cystic or CBD dilation. There is no evidence of effusion or inflammation.



PATIENT

Max Dyer

SPECIES

Canine

BREED

Bulldog x

SEX

Neutered Male

AGE

3 Years 6 Months

WEIGHT

12.8 kg

INTERPRETED BY

Beth Johnson, DVM
DACVIM

IMAGING PERFORMED BY

Dr. Brian Barnes

HOSPITAL NAME

Westview Veterinary
Hospital

REFERRING VET

Dr. Brian Barnes

INVOICE

71951

DATE

11/19/25

Gastrointestinal

The visible stomach wall is normal in thickness and layering. The lumen of the stomach is empty with no evidence of obstruction, foreign material or infiltrative disease. Pyloric outflow tract appears patent.

The visible small intestines are normal in wall thickness and layering. Small intestinal motility appears adequate (1-3 contractions per min). The lumen of the small intestine is empty with no evidence of obstruction, foreign material or infiltrative disease.

The visible colon is normal in wall thickness (< 0.2 cm) and layering. Contents are consistent with normal formed feces and gas.

Pancreas

The pancreas that is observed appears appropriately isoechoic to surrounding omental fat. Visible capsule is smooth and normal in contour. Visible pancreatic parenchyma is homogenous and unremarkable. There is no visible pancreatic duct dilation. There is no evidence of active peripancreatic inflammation.

Free Abdomen

There is no visible free peritoneal effusion noted in these images.

There is no apparent pathologic lymphadenopathy noted in these images.

ULTRASONOGRAPHIC FINDINGS

- Mild gallbladder debris - Cholecystic debris is of unknown clinical significance. It can be seen with biliary stasis from fasting or illness. Cholecystic debris is not necessarily related to hepatobiliary disease. Echogenic bile is most commonly an incidental finding in dogs and should be interpreted in combination with clinical signs such as nausea, inappetence, cranial abdominal discomfort and/or laboratory changes such as increased ALP and/or increased Tbili.
- Coarse splenomegaly – can be associated with congestion caused by sedation (if sedated) but can also be associated with diffuse infiltrative disease. Both benign conditions such as extramedullary hematopoiesis, lymphoid hyperplasia, as well as infiltrative neoplastic diseases such as round cell neoplasia should be considered.
- Bilateral medullary rim sign - This finding is of unknown clinical significance and can be a normal variant, often idiopathic. Medullary rim sign can be present with renal disease including lymphoma, hypercalcemic nephropathy, Leptospirosis, tubular disease, other and should be interpreted in combination with other more specific indications of kidney disease such as isosthenuria, proteinuria, azotemia, etc. This is a common incidental finding in patients with diabetes mellitus.
- An obvious cause for the subtle liver changes is not identified in these images. Microscopic disease such as Leptospirosis, bacterial cholangiohepatitis, chronic active hepatitis, copper-associated hepatotoxicity, other hepatotoxicity, other reactive hepatopathy, infiltrative neoplasia (considered unlikely), etc. cannot be definitively ruled out.



PATIENT

Max Dyer

SPECIES

Canine

BREED

Bulldog x

SEX

Neutered Male

AGE

3 Years 6 Months

WEIGHT

12.8 kg

INTERPRETED BY

Beth Johnson, DVM
DACVIM

IMAGING PERFORMED BY

Dr. Brian Barnes

HOSPITAL NAME

Westview Veterinary
Hospital

REFERRING VET

Dr. Brian Barnes

INVOICE

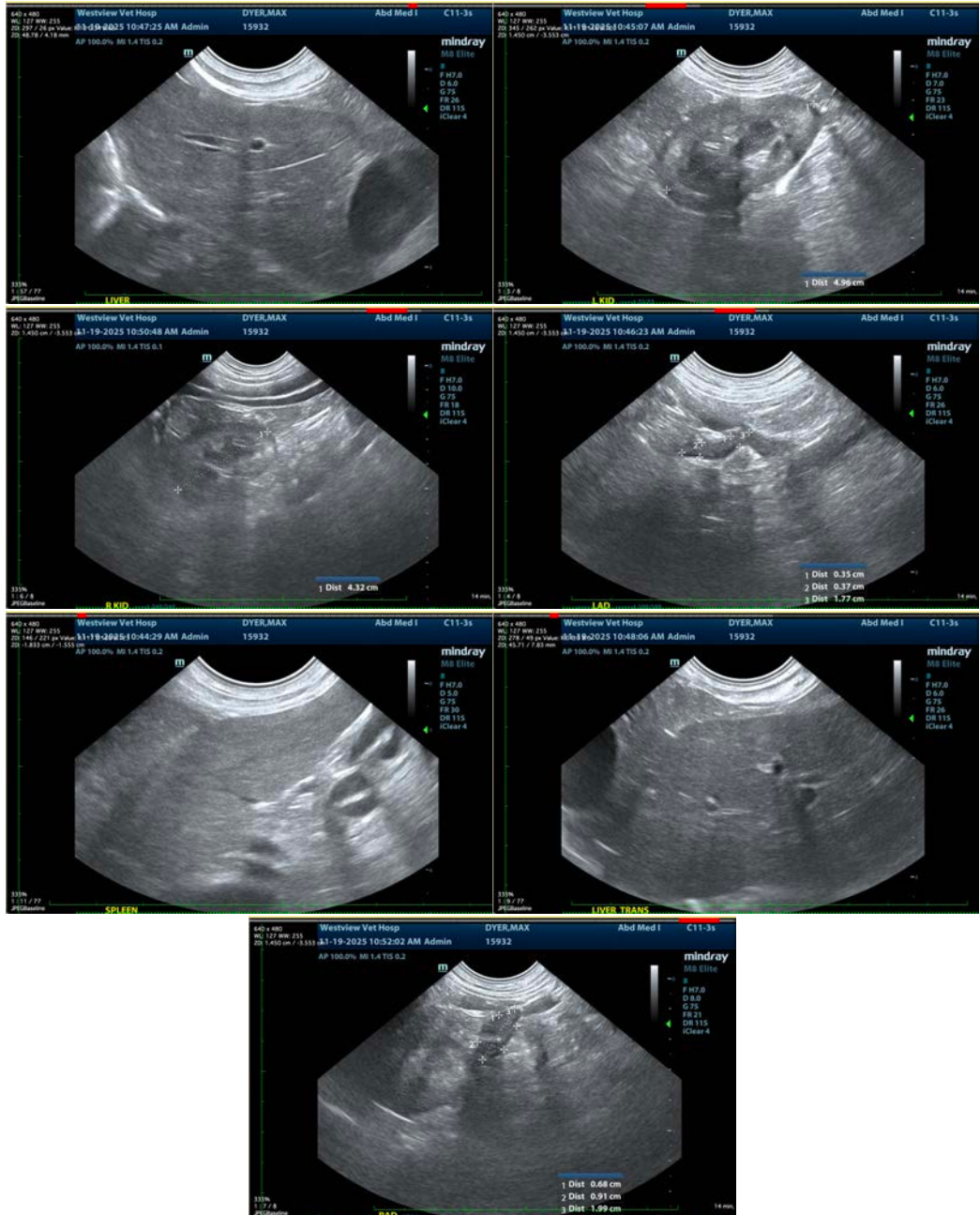
71951

DATE

11/19/25

INTERPRETATION OF THE FINDINGS & FURTHER RECOMMENDATIONS

There are some very mild/subtle liver changes as described, but otherwise this is a relatively static study compared to previous exams. Recommendations are similarly unchanged and ultimately include liver sampling. Fine needle aspirate could be considered if patient's coagulation status is appropriate, or ultimately a biopsy may be necessary, being sure to include copper level assessment if possible for definitive diagnosis and therefore to further guide medical management if indicated.





PATIENT

Max Dyer

SPECIES

Canine

BREED

Bulldog x

SEX

Neutered Male

AGE

3 Years 6 Months

WEIGHT

12.8 kg

INTERPRETED BY

Beth Johnson, DVM
DACVIM

IMAGING PERFORMED BY

Dr. Brian Barnes

HOSPITAL NAME

Westview Veterinary
Hospital

REFERRING VET

Dr. Brian Barnes

INVOICE

71951

DATE

11/19/25

The information and recommendations provided are based on the images presented by the referring veterinarian/sonographer. No evaluation can be communicated regarding pathology that was not visible in the image/video clips provided.

Thank you for this referral. If the clinical or image interpretation does not parallel your findings or if I can be of any further assistance please contact me.

Beth Johnson, DVM, DACVIM
info@sonopath.com