



PATIENT

Bertie Larson

SPECIES

Feline

BREED

DSH

SEX

Spayed Female

AGE

2.5 Years

WEIGHT

9.1

INTERPRETED BY

Beth Johnson, DVM
DACVIM

IMAGING PERFORMED BY

Dr. Betsy Lacroix

HOSPITAL NAME

Inspire Animal Hospital
- Highlands Ranch

REFERRING VET

Dr. Rachel Wolsky

INVOICE

71962

DATE

11/19/25

PRESENTING CLINICAL SIGNS

Patient has been having chronic vomiting for a few months, worse on novel protein diet (vomiting daily), also slightly lethargic. FeLV/FIV- neg/neg. CBC/chem/u/a unremarkable. No known FB/dietary indiscretion.

Abnormal PE/Chem/CBC/UA Results: Unremarkable PE BW unremarkable- A/G ratio 1.2 mild hemoconcentration/dehydration.

ULTRASONOGRAPHIC EXAMINATION OF THE ABDOMEN

Urinary System

The urinary bladder is adequately distended with anechoic contents. No masses, inflammatory changes, echogenic sediment or cystoliths are observed. The urinary bladder, trigone and visible pelvic urethra are normal in thickness with a smooth mucosal surface.

The right kidney is normal is size (3.04 cm), shape and echogenicity. It has smooth peripheral margination. There is a normal 1:3 cortex to medulla ratio with appropriate corticomedullary distinction. There is no evidence of pyelectasia, mineral or infarcts observed.

The left kidney is normal is size (3.2 cm), shape and echogenicity. It has smooth peripheral margination. There is a normal 1:3 cortex to medulla ratio with appropriate corticomedullary distinction. There is no evidence of pyelectasia, mineral or infarcts observed.

Adrenal Glands

The areas of the adrenal glands are examined without evident adrenal gland pathology.

Spleen

The spleen is subjectively normal in size with a normal smooth capsular contour. Parenchyma is appropriately finely textured and homogenous with normal echogenicity relative to surrounding tissue (hyperechoic to liver). No focal nodules or masses are observed. Splenic vasculature appears normal.

Liver

Liver is subjectively enlarged (swollen contour) with a diffusely mildly coarse architecture and subtly increased portal markings. Mildly mixed echogenic changes are noted diffusely. No focal lesions are observed. Visible vasculature and biliary tree appear normal without distension or congestion.

The gallbladder is non-distended in size. The wall is smooth without visible thickening. Luminal contents are primarily anechoic. There is no evidence of cystic or common bile duct dilation.

Gastrointestinal

The visible stomach wall is normal in thickness and layering. The lumen of the stomach is empty with no evidence of obstruction, foreign material or infiltrative disease. Pyloric outflow tract appears patent.

The visible small intestine demonstrates areas of mildly thick muscularis layer relative to mucosa (disruption of the normal 1:3 muscularis:mucosa ratio). Small intestinal submucosa is slightly irregular, thick and hyperechoic, without evident loss of layering appreciated. The lumen of the small intestine is empty with no evidence of obstruction or foreign material.



PATIENT

Bertie Larson

SPECIES

Feline

BREED

DSH

SEX

Spayed Female

AGE

2.5 Years

WEIGHT

9.1

INTERPRETED BY

Beth Johnson, DVM
DACVIM

IMAGING PERFORMED BY

Dr. Betsy Lacroix

HOSPITAL NAME

Inspire Animal Hospital
- Highlands Ranch

REFERRING VET

Dr. Rachel Wolsky

INVOICE

71962

DATE

11/19/25

The visible colon is normal in wall thickness (< 0.2 cm) and layering. Contents are consistent with normal formed feces and gas.

Pancreas

Pancreas is prominent (enlarged) in size, hypoechoic to surrounding tissue and has a mildly irregular undulating contour. Parenchyma is coarse with mixed echogenic remodeling noted. No pancreatic duct dilation is noted.

Free Abdomen

There is no visible free peritoneal effusion noted in these images.

There is no apparent pathologic lymphadenopathy noted in these images.

ULTRASONOGRAPHIC FINDINGS

- Mild/emerging inflammatory bowel disease (IBD) pattern – Thick muscularis has been reported with infiltrative bowel disease including both benign inflammatory disease as well as infiltrative neoplasia such as lymphoma. No loss of layering, etc. is noted to make lymphoma more probable, but lymphoma cannot be definitively ruled out without tissue sampling.
- Concurrent chronic low-grade smoldering pancreatitis can't be ruled out.
- The liver changes are subtle and non-specific, with differentials for a microscopic hepatopathy including bacterial, lymphoplasmacytic hepatitis, other infectious or inflammatory hepatopathy, hepatic lipidosis, or infiltrative neoplasia can't be ruled out without tissue sampling.

INTERPRETATION OF THE FINDINGS & FURTHER RECOMMENDATIONS

A routine fecal/giardia exam is recommended if not recently evaluated.

A gastrointestinal malabsorption panel (including cobalamin, folate, TLI and PLI) to Texas A&M GI Laboratory is recommended for further evaluation of GI and pancreatic function.

Fine needle aspirates of the liver +/- pancreas could be considered if patient's coagulation status is appropriate.

Ultimately, biopsies of the GI tract, being sure to include ileum, if possible, may be necessary for definitive diagnosis and therefore to further guide medical management of suspected emerging bowel disease, potentially as a component of "Triaditis".

In the meantime, in addition to supportive/symptomatic medical management of clinical signs, if tolerated, a transition in diet is recommended, based on trial-and-error response.

Some options to consider include a gastrointestinal biome diet vs a hydrolyzed protein diet (sometimes several trials with different brands are necessary) vs a fiber response/colitis diet vs a bland, easy to digest or low-fat diet vs other.



PATIENT

Bertie Larson

SPECIES

Feline

BREED

DSH

SEX

Spayed Female

AGE

2.5 Years

WEIGHT

9.1

INTERPRETED BY

Beth Johnson, DVM
DACVIM

IMAGING PERFORMED BY

Dr. Betsy Lacroix

HOSPITAL NAME

Inspire Animal Hospital
- Highlands Ranch

REFERRING VET

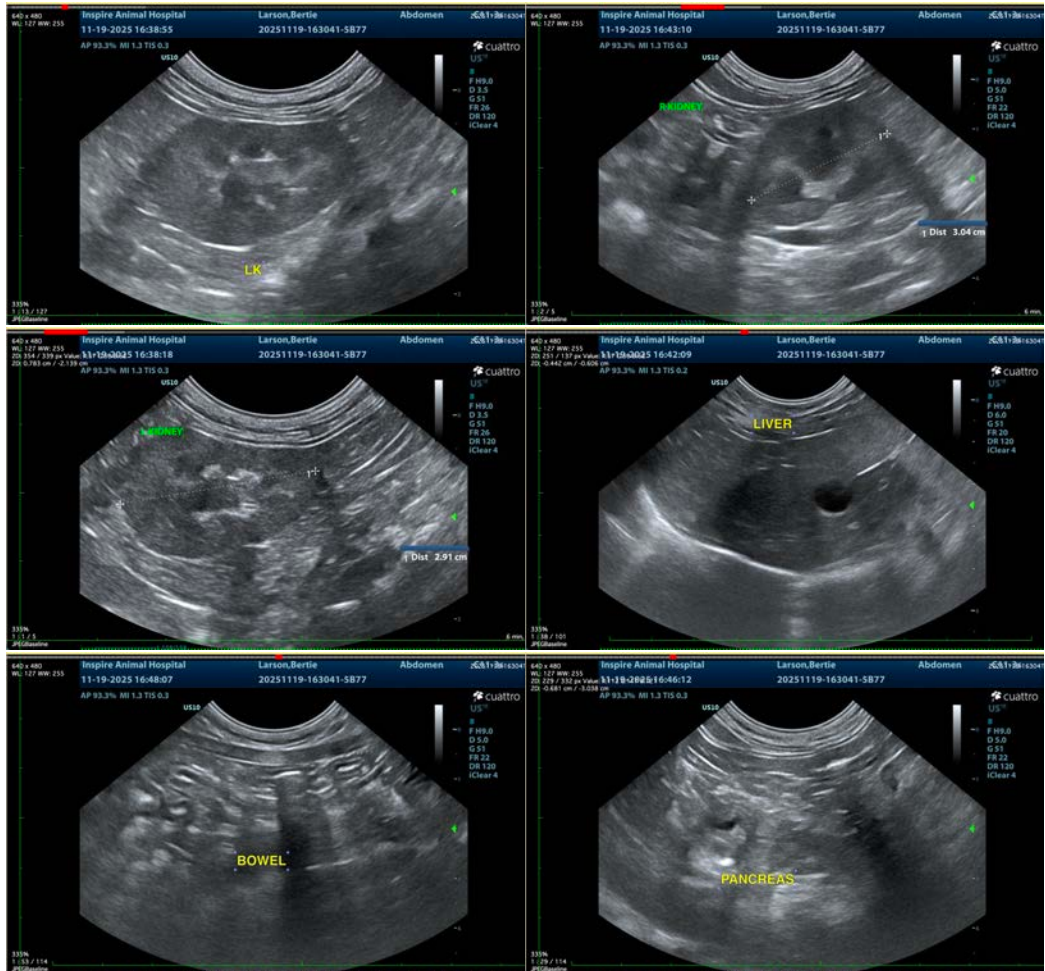
Dr. Rachel Wolsky

INVOICE

71962

DATE

11/19/25



The information and recommendations provided are based on the images presented by the referring veterinarian/sonographer. No evaluation can be communicated regarding pathology that was not visible in the image/video clips provided.

Thank you for this referral. If the clinical or image interpretation does not parallel your findings or if I can be of any further assistance please contact me.

Beth Johnson, DVM, DACVIM
info@sonopath.com