

PATIENT

Dylan Seprish

SPECIES

Feline

BREED

DSH

SEX

MN

AGE

9

WEIGHT

16.4

INTERPRETED BY

Beth Johnson, DVM
DACVIM

IMAGING PERFORMED BY

Jenn

HOSPITAL NAME

Rockaway Animal
Hospital

REFERRING VET

Dr. Maniar

INVOICE

10756

DATE

11/18/2025

PRESENTING CLINICAL SIGNS

V/D.

Abnormal PE/Chem/CBC/UA Results: GGT 13.

ULTRASONOGRAPHIC EXAMINATION OF THE ABDOMEN

Urinary System

The urinary bladder is adequately distended with anechoic contents. No masses, inflammatory changes, echogenic sediment or cystoliths are observed. The urinary bladder, trigone and visible pelvic urethra are normal in thickness with a smooth mucosal surface.

Kidneys are overall normal in size and shape with smooth peripheral margination. A normal 1:3 cortex to medulla ratio is maintained. The medulla and cortices are uniform in texture with some mild increased cortical echogenicity and mild loss of corticomedullary distinction, expected in this age patient. There is no evidence of mineral or infarcts observed. Trace pyelectasia is noted bilaterally. Left kidney measures 4.07 cm, and the right kidney measures 4.2 cm.

Adrenal Glands

The adrenal glands are unable to be well visualized in these images.

Spleen

The spleen is subjectively normal in size with a normal smooth capsular contour. Parenchyma is appropriately finely textured and homogenous with normal echogenicity relative to surrounding tissue (hyperechoic to liver). No focal nodules or masses are observed. Splenic vasculature appears normal.

Liver

The liver is subjectively normal in size with normal smooth curvilinear peripheral contour. Parenchyma is appropriately hypoechoic to the spleen in echogenicity and appropriately mildly coarse and homogenous in echotexture. No focal lesions are observed. Visible vasculature and biliary tree appear normal without distension or congestion.

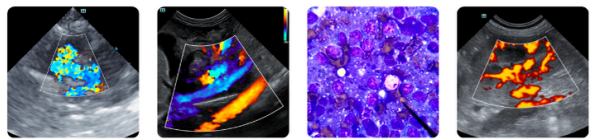
The gallbladder is non-distended in size. The wall is smooth without visible thickening. Luminal contents are primarily anechoic. There is no evidence of cystic or common bile duct dilation.

Gastrointestinal

The visible stomach wall is normal in thickness and layering. The lumen of the stomach is empty with no evidence of obstruction, foreign material or infiltrative disease. Pyloric outflow tract appears patent.

The visible small intestine demonstrates areas of moderately thick muscularis layer relative to mucosa (disruption of the normal 1:3 muscularis:mucosa ratio). Small intestinal submucosa is slightly irregular, thick and hyperechoic, without evident loss of layering appreciated. The lumen of the small intestine is empty with no evidence of obstruction or foreign material.

The visible colon is normal in wall thickness (< 0.2 cm) and layering. Contents are consistent with normal formed feces and gas.



PATIENT

Pancreas

Dylan Seprish

The pancreas that is observed appears appropriately isoechoic to surrounding omental fat. Visible capsule is smooth and normal in contour. Visible pancreatic parenchyma is homogenous and unremarkable. There is no visible pancreatic duct dilation. There is no evidence of active peripancreatic inflammation.

SPECIES

Feline

Free Abdomen

BREED

DSH

There is no visible free peritoneal effusion noted in these images.

SEX

MN

PRIMARY FINDINGS

AGE

9

- Moderate inflammatory bowel disease (IBD) pattern – Thick muscularis has been reported with infiltrative bowel disease including both benign inflammatory disease as well as infiltrative neoplasia such as lymphoma. No loss of layering, etc. is noted to make lymphoma more probable, but lymphoma cannot be definitively ruled out without tissue sampling.

WEIGHT

16.4

SECONDARY FINDINGS

- Ager related kidney changes with trace bilateral pyelectasia.

INTERPRETATION OF THE FINDINGS & FURTHER RECOMMENDATIONS

INTERPRETED BY

Beth Johnson, DVM
DACVIM

A gastrointestinal malabsorption panel (including cobalamin, folate, TLI and PLI) to Texas A&M GI Laboratory is recommended for further evaluation of GI and pancreatic function.

Ideally, biopsies of the GI tract, being sure to include ileum if possible, are recommended to definitively diagnose and therefore manage the infiltrative bowel disease.

IMAGING PERFORMED BY

Jenn

If biopsies cannot be obtained, empirical therapies could include a probiotic (if diarrhea is present, such as visbiome or proviable), empirical deworming with a 5-day course of Panacur and, if tolerated, a transition in diet, based on trial-and-error response, beginning with a hydrolyzed protein diet. Some patients respond to one brand/version of a hydrolyzed protein diet better than another brand, so several trials may be required.

HOSPITAL NAME

Rockaway Animal Hospital

Additional considerations could include cobalamin supplementation (unless cobalamin level is evaluated and supplementation is not warranted) and prednisolone (if not contraindicated based on patient contraindications, co-morbidities, etc.).

REFERRING VET

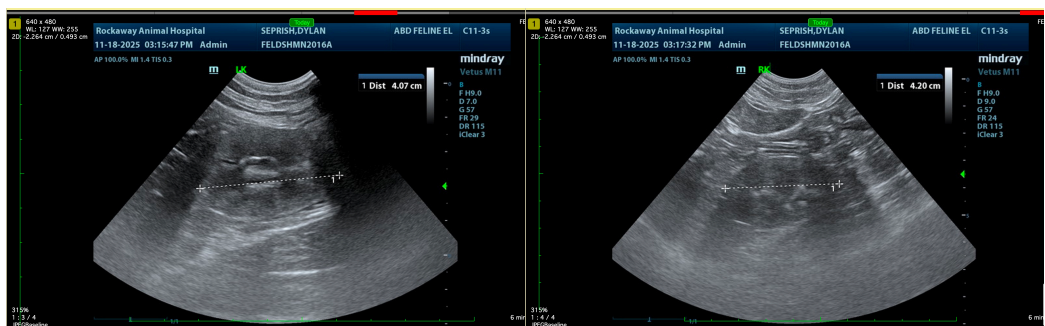Dr. Maniar

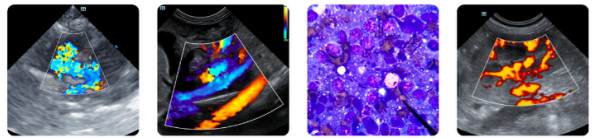
INVOICE

10756

DATE

11/18/2025





PATIENT

Dylan Seprish

SPECIES

Feline

BREED

DSH

SEX

MN

AGE

9

WEIGHT

16.4

INTERPRETED BY

Beth Johnson, DVM
DACVIM

IMAGING PERFORMED BY

Jenn

HOSPITAL NAME

Rockaway Animal
Hospital

REFERRING VET

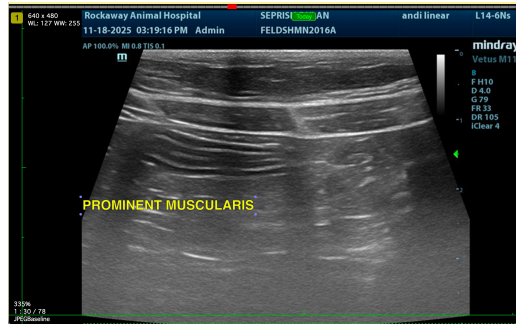
Dr. Maniar

INVOICE

10756

DATE

11/18/2025



The information and recommendations provided are based on the images presented by the referring veterinarian/sonographer. No evaluation can be communicated regarding pathology that was not visible in the image/video clips provided.

Thank you for this referral. If the clinical or image interpretation does not parallel your findings or if I can be of any further assistance please contact me.

Beth Johnson, DVM, DACVIM
info@sonopath.com