



**PATIENT**

Comet Schneider

**SPECIES**

Canine

**BREED**

Beagle

**SEX**

Neutered Male

**AGE**

10 Years

**WEIGHT**

40 lbs

**INTERPRETED BY**

Beth Johnson, DVM  
DACVIM

**IMAGING PERFORMED BY**

Kerri Becker

**HOSPITAL NAME**

Companion Animal  
Hospital Parsippany

**REFERRING VET**

Dr. Tsai

**INVOICE**

71899

**DATE**

11/18/25

**PRESENTING CLINICAL SIGNS**

Elevated liver enzymes.

Abnormal PE/Chem/CBC/UA Results: TP-9 Alb-5.2 Glob-3.8 AST-74 ALT-238 ALKp-232 mag-3.4 chol-400 trig-738 HGB-21.2

**ULTRASONOGRAPHIC EXAMINATION OF THE ABDOMEN**

**Urinary System**

The urinary bladder is adequately distended with anechoic contents. No masses, inflammatory changes, echogenic sediment or cystoliths are observed. The urinary bladder, trigone and visible pelvic urethra are normal in thickness with a smooth mucosal surface.

Prostate is normal in size, echotexture and echogenicity for a neutered male.

Kidneys are overall normal in size and shape with smooth peripheral margination. A normal 1:3 cortex to medulla ratio is maintained. The medulla and cortices are uniform in texture with some mild increased cortical echogenicity and mild loss of corticomedullary distinction, expected in this age patient. There is no evidence of pyelectasia, mineral or infarcts observed. Left kidney measures 5.5 cm. Right kidney measures 4.8 cm.

**Adrenal Glands**

The right adrenal gland is normal in size (0.67 cm at cranial pole and 0.42 cm at caudal pole), shape and overall architecture, echogenicity and echotexture. Visible surrounding vasculature appears normal.

The left adrenal gland is normal in size (0.59 cm at cranial pole and 0.49 cm at caudal pole), shape and overall architecture, echogenicity and echotexture. Visible surrounding vasculature appears normal.

**Spleen**

The spleen is subjectively normal in size with a normal smooth capsular contour. Parenchyma is appropriately finely textured and homogenous with normal echogenicity relative to surrounding tissue (hyperechoic to liver). No focal nodules or masses are observed. Splenic vasculature appears normal.

**Liver**

Liver is subjectively enlarged (swollen contour) with a diffusely mildly coarse architecture and subtly increased portal markings. Mildly mixed echogenic changes are noted diffusely. No focal lesions are observed. Visible vasculature and biliary tree appear normal without distension or congestion.

Gallbladder is moderately distended with anechoic bile as well as suspended and gravity dependent echogenic debris. The wall is smooth without visible thickening. There is no evidence of cystic or CBD dilation. There is no evidence of effusion or inflammation.

**Gastrointestinal**

The visible stomach wall is normal in thickness and layering. The lumen of the stomach is mildly distended with very echogenic reverberation artifact from intraluminal gas. There is no evidence of obstruction, foreign material, or infiltrative disease; however, visualization is partially inhibited by gas.



<b>PATIENT</b>	The visible small intestines are normal in wall thickness and layering. Small intestinal motility appears adequate (1-3 contractions per min). The lumen of the small intestine is mildly distended with very echogenic reverberation artifact from intraluminal gas. There is no evidence of obstruction, foreign material, or infiltrative disease; however, visualization is partially inhibited by gas.
Comet Schneider	
<b>SPECIES</b>	The visible colon is normal in wall thickness (< 0.2 cm) and layering. Contents are consistent with normal formed feces and gas.
Canine	
<b>BREED</b>	<b><i>Pancreas</i></b>
Beagle	The pancreas that is observed appears appropriately isoechoic to surrounding omental fat. Visible capsule is smooth and normal in contour. Visible pancreatic parenchyma is homogenous and unremarkable. There is no visible pancreatic duct dilation. There is no evidence of active peripancreatic inflammation.
<b>SEX</b>	<b><i>Free Abdomen</i></b>
Neutered Male	There is no visible free peritoneal effusion noted in these images.
<b>AGE</b>	There is no apparent pathologic lymphadenopathy noted in these images.
10 Years	
<b>WEIGHT</b>	<b>PRIMARY FINDINGS</b>
40 lbs	<ul style="list-style-type: none"> <li>An obvious cause for the liver changes is not identified in these images. Microscopic disease such as Leptospirosis, bacterial cholangiohepatitis, chronic active hepatitis, copper-associated hepatotoxicity, other hepatotoxicity, other reactive hepatopathy, infiltrative neoplasia (considered unlikely), etc. cannot be definitively ruled out.</li> <li>Moderate gallbladder debris - Cholecystic debris is of unknown clinical significance. It can be seen with biliary stasis from fasting or illness. Cholecystic debris is not necessarily related to hepatobiliary disease. Echogenic bile is most commonly an incidental finding in dogs and should be interpreted in combination with clinical signs such as nausea, inappetence, cranial abdominal discomfort and/or laboratory changes such as increased ALP and/or increased Tbili.</li> </ul>
<b>INTERPRETED BY</b>	<b>SECONDARY FINDINGS</b>
Beth Johnson, DVM DACVIM	<ul style="list-style-type: none"> <li>Age related kidney changes.</li> </ul>
<b>IMAGING PERFORMED BY</b>	<b>INTERPRETATION OF THE FINDINGS &amp; FURTHER RECOMMENDATIONS</b>
Kerri Becker	Differentials for a primary hepatocellular injury liver enzyme pattern (increased ALT) depend partially on the level of increase. Mild increases (less than 2 times normal) are often a "reactive hepatopathy" or the liver's response to an insult elsewhere in the body including, but not limited to, pancreatitis, gastroenteritis, parasitic disease, dental disease, vacuolar or endocrine hepatopathy from diabetes mellitus or hyperadrenocorticism (steroid-induced), hypoadrenocorticism, certain drugs (e.g. phenobarbital, corticosteroids, azathioprine, etc.), and muscle ALT (more likely if AST and CK concurrently increased).
<b>HOSPITAL NAME</b>	It is a good indicator of active liver damage (cell membrane disruption, cellular necrosis), however, if the value is increased by at least 3-4 times normal. Differentials include infectious disease, including Leptospirosis, inflammatory disease (ie. active hepatitis, copper, other), toxic insult as well as infiltrative neoplasia.
Companion Animal Hospital Parsippany	
<b>REFERRING VET</b>	
Dr. Tsai	
<b>INVOICE</b>	
71899	
<b>DATE</b>	
11/18/25	



**PATIENT**

Comet Schneider

**SPECIES**

Canine

**BREED**

Beagle

**SEX**

Neutered Male

**AGE**

10 Years

**WEIGHT**

40 lbs

**INTERPRETED BY**

Beth Johnson, DVM  
DACVIM

**IMAGING PERFORMED BY**

Kerri Becker

**HOSPITAL NAME**

Companion Animal  
Hospital Parsippany

**REFERRING VET**

Dr. Tsai

**INVOICE**

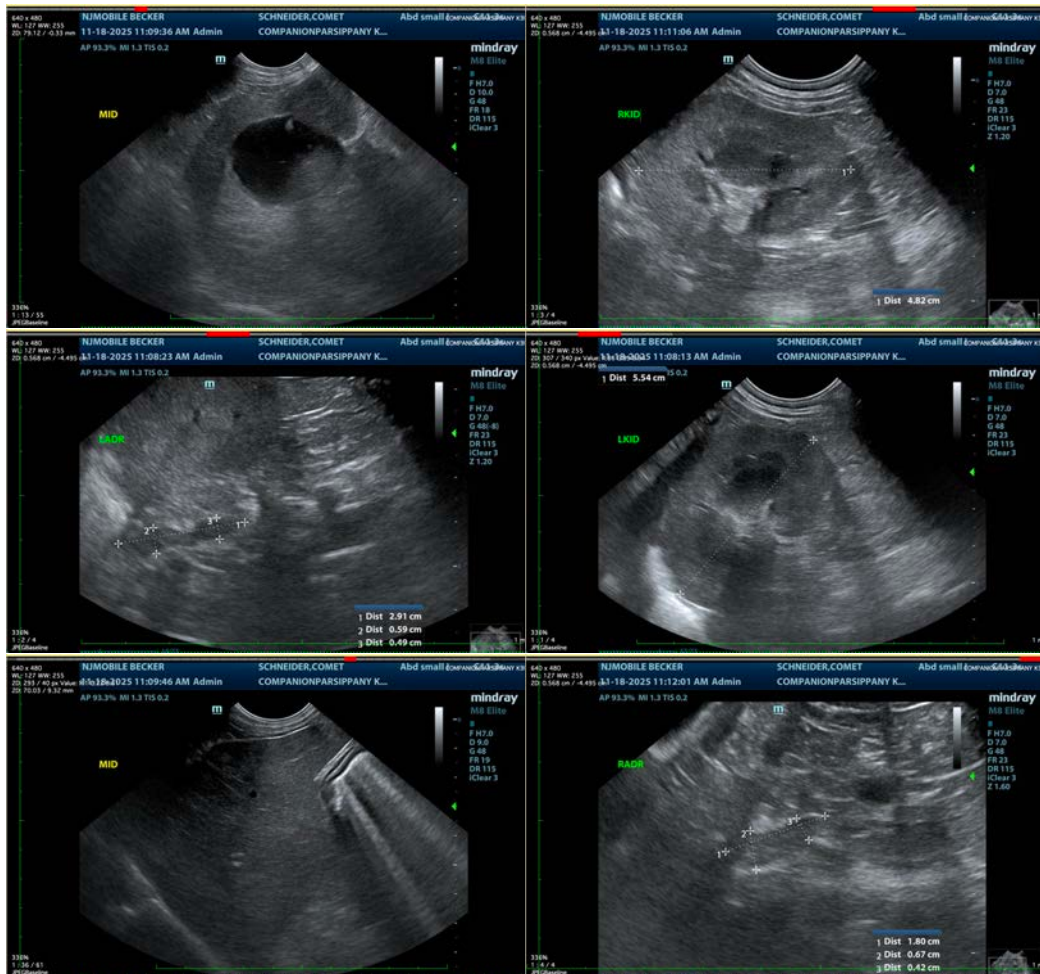
71899

**DATE**

11/18/25

ALT levels vary in cases of vascular anomalies such as microvascular dysplasia and portosystemic shunts (PSS), but are often less significantly increased.

- Testing for Leptospirosis could be considered.
- Bile acids could be considered, if tбили is not increased.
- An empirical course of antibiotics and empirical hepatic nutraceuticals (including Ursodiol, given the gallbladder debris) may be tried, with monitoring of ALT for improvement. If improvement is noted, antibiotics should be continued until liver enzymes either normalize or plateau (recheck every 2-3 weeks); however, if improvement is not noted and/or enzyme increase progresses, antibiotics should not be continued long term and liver tissue sampling is recommended.
- FNA of the liver can be performed to assess inflammatory cell type, rule in/out round cell neoplasia, etc. (if patient's coagulation status is appropriate).
- If round cell neoplasia is not diagnosed, a liver biopsy (including copper level assessment) may be required to definitively diagnose the underlying hepatopathy.





**PATIENT**

Comet Schneider

**SPECIES**

Canine

**BREED**

Beagle

**SEX**

Neutered Male

**AGE**

10 Years

**WEIGHT**

40 lbs

**INTERPRETED BY**

Beth Johnson, DVM  
DACVIM

**IMAGING  
PERFORMED BY**

Kerri Becker

**HOSPITAL NAME**

Companion Animal  
Hospital Parsippany

**REFERRING VET**

Dr. Tsai

**INVOICE**

71899

**DATE**

11/18/25

The information and recommendations provided are based on the images presented by the referring veterinarian/sonographer. No evaluation can be communicated regarding pathology that was not visible in the image/video clips provided.

Thank you for this referral. If the clinical or image interpretation does not parallel your findings or if I can be of any further assistance please contact me.

**Beth Johnson, DVM, DACVIM**  
[info@sonopath.com](mailto:info@sonopath.com)