



**DATE PRESENTING CLINICAL SIGNS**

11/17/25 Patient History: Recheck heart (2.5X2.0 cm heart base mass) and abdomen (multiple nonsignificant findings)  
No clinical issues. Chronic leishmaniasis - asymp., titer 112 (9/15/25 Univ. Cornell)

**PATIENT**

Mabel Felts Current Medications: Allopurinol 150mg bid  
Labwork Results: Diagnostics not attached, reported as: no recent labwork or radiographs  
Date of Previous IntraPet Ultrasound: 6/5/25, 7/17/23. See attached.

**SPECIES**

Canine Sedation: Not required to complete full diagnostic ultrasound.  
Stat Report: Not requested.  
Imaging Performed by: Stephanie Warga RDCS, RVT.

**BREED**

**ULTRASONOGRAPHIC EXAMINATION OF THE ABDOMEN**

English Bulldog

**Urinary System**

**SEX**

Spayed Female Urinary bladder is adequately distended with anechoic contents. No masses, inflammatory changes, echogenic sediment or cystoliths are observed. The urinary bladder, trigone and visible pelvic urethra are normal in thickness with a smooth mucosal surface.

**AGE**

3/21/17 Left kidney is normal in size (6.68 cm), shape and echogenicity. It has smooth peripheral margination. There is a normal 1:3 cortex to medulla ratio with appropriate corticomedullary distinction. There is no evidence of mineral or infarcts observed. Mild to moderate pyelectasia (0.48 cm transverse view) is noted. A hyperechoic band parallel to the corticomedullary border is present.

**WEIGHT**

35.6 Pounds Right kidney is normal in size (6.1 cm), shape and echogenicity. It has smooth peripheral margination. There is a normal 1:3 cortex to medulla ratio with appropriate corticomedullary distinction. There is no evidence of mineral or infarcts observed. Mild to moderate pyelectasia (0.36 cm transverse view) is noted. Additionally, a small cortical cyst is present in the right kidney. A hyperechoic band parallel to the corticomedullary border is present.

**INTERPRETED BY**

Beth Johnson, DVM  
DACVIM

**Adrenal Glands**

**HOSPITAL NAME**

Essex Middle River VC Adrenal glands are largely normal in size, shape and contour. Some parenchymal heterogeneity is present without concerning capsular distortion. These changes are likely normal for this age but should be monitored if there is any suspicion of adrenal disease. The left adrenal gland measures 0.62 cm at cranial pole and 0.63 cm at caudal pole. The right adrenal gland measures 0.66 cm at cranial pole and 0.86 cm at caudal pole.

**REFERRING VET**

Dr. Zulty

**Spleen**

**INVOICE**

35551 Spleen is subjectively large in size with normal smooth margins. Parenchyma is normal in echogenicity with a diffusely coarse/heterogeneous echotexture. Additionally, focally, near the cranial aspect of the spleen, is a mildly heterogeneous primarily hypoechoic non-capsule-disrupting nodule that measures approximately 1.8 cm x 2.1 cm in size. Splenic vasculature appears normal.

**Liver**

Liver is subjectively normal in size with normal smooth curvilinear peripheral contour. Parenchyma is appropriately hypoechoic to the spleen in echogenicity and appropriately mildly coarse and homogenous in

echotexture. No focal lesions are observed. Visible vasculature and biliary tree appear normal without distension or congestion.

Gallbladder is moderately distended with anechoic bile as well as suspended and gravity dependent echogenic debris. The wall is smooth without visible thickening. There is no evidence of cystic or CBD dilation. There is no evidence of effusion or inflammation.

### ***Gastrointestinal***

The visible stomach wall is normal in thickness and layering. The lumen of the stomach is empty with no evidence of obstruction, foreign material or infiltrative disease. Pyloric outflow tract appears patent.

The visible small intestines are normal in wall thickness and layering. Small intestinal motility appears adequate (1-3 contractions per min). The lumen of the small intestine is empty with no evidence of obstruction, foreign material or infiltrative disease.

The visible colon is normal in wall thickness (< 0.2 cm) and layering. Contents are consistent with normal formed feces and gas.

### ***Pancreas***

The pancreas that is observed appears appropriately isoechoic to surrounding omental fat. Visible capsule is smooth and normal in contour. Visible pancreatic parenchyma is homogenous and unremarkable. There is no visible pancreatic duct dilation. There is no evidence of active peripancreatic inflammation.

### ***Free Abdomen***

There is no visible free peritoneal effusion noted in these images.

There is no apparent pathologic lymphadenopathy noted in these images.

## **ULTRASONOGRAPHIC Findings**

### **Primary Findings**

- Coarse splenomegaly – can be associated with congestion caused by sedation (if sedated) but can also be associated with diffuse infiltrative disease. Both benign conditions such as extramedullary hematopoiesis, and lymphoid hyperplasia, as well as infiltrative neoplastic diseases such as round cell neoplasia should be considered. The focal nodule is largely static in appearance to potentially very mildly increased in size compared to the previous study, with differentials unchanged, including both benign lesions, such as a cyst, hematoma, nodular hyperplasia, extramedullary hematopoiesis, etc., as well as infiltrative neoplasia, which can mimic benign lesions, and can't be ruled out without additional information.

### **Secondary Findings**

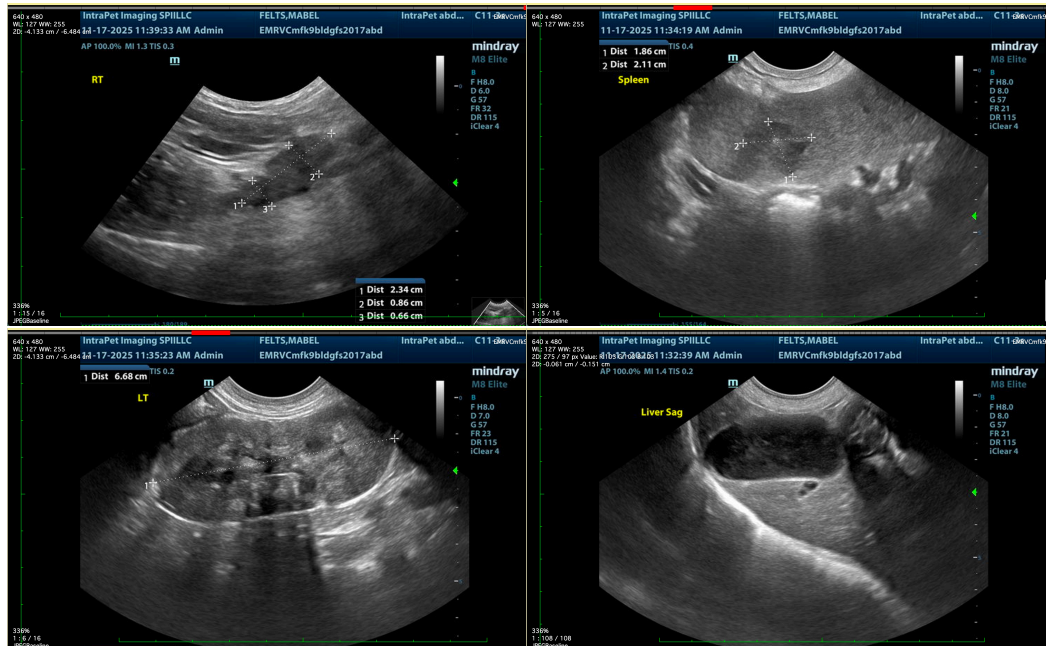
- Mild gallbladder debris- Cholecystic debris is of unknown clinical significance. It can be seen with biliary stasis from fasting or illness. Cholecystic debris is not necessarily related to hepatobiliary disease. Echogenic bile is most commonly an incidental finding in dogs and should be interpreted

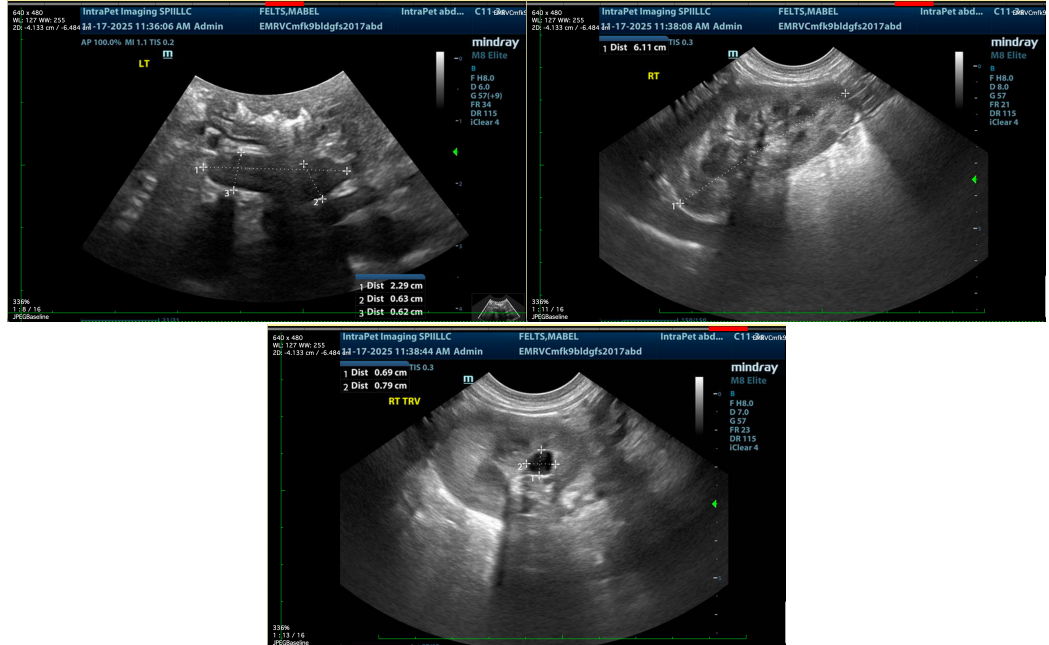
in combination with clinical signs such as nausea, inappetence, cranial abdominal discomfort and/or laboratory changes such as increased ALP and/or increased Tbili.

- Mild age-related adrenal gland changes.
- Mild/subtle bilateral Medullary rim sign - This finding is of unknown clinical significance and can be a normal variant, often idiopathic. Medullary rim sign can be present with renal disease including lymphoma, hypercalcemic nephropathy, Leptospirosis, tubular disease, other and should be interpreted in combination with other more specific indications of kidney disease such as isosthenuria, proteinuria, azotemia, etc. This is a common incidental finding in patients with diabetes mellitus. Additionally, an incidental cortical cyst was noted in the right kidney and mild to moderate bilateral pyelectasia.

### **INTERPRETATION OF THE FINDINGS & FURTHER RECOMMENDATIONS**

The appearance of this study is largely static/unchanged to the previous exam, with potential mild progression in size of the splenic nodule, as described above, from 1.4 cm x 2.4 cm in size to 1.8 cm x 2.1 cm in size in this study. Sampling could be considered if patient's coagulation status is appropriate or continued monitoring may be appropriate. As is reportedly already planned or in place, consultation with a veterinary oncologist is recommended.





**The information and recommendations provided are based on the images presented by the referring veterinarian/sonographer. No evaluation can be communicated regarding pathology that was not visible in the image/video clips provided.**

Thank you for this referral. If the clinical or image interpretation does not parallel your findings or if I can be of any further assistance please contact me.

**Beth Johnson, DVM DACVIM**

info@sonopath.com