

**DATE PRESENTING CLINICAL SIGNS**

11/10/22 Diagnosed with IBD by Towson Internal Medicine about a year ago. Was also treated for Hyperthyroidism by Radiocat about 2 months ago. Did great following but in the past 2 weeks he had diarrhea and a pickier appetite. Spec FPL elevated at 13 on 10/26/22.

PATIENT

Pippin Costello Current Medications: Budesonide 1 mg SID, Vitamin B12: 250 mcg weekly since 10/26, Probiotic
Date of Previous IntraPet Ultrasound: 4/1/19. Attached.

SPECIES

Sedation: Not required to complete full diagnostic ultrasound.
Stat Report: Not requested.

Feline

ULTRASONOGRAPHIC EXAMINATION OF THE ABDOMEN**BREED****Urinary System**

DLH

Urinary bladder is adequately distended. It has a normal uniform wall thickness. Contents include primarily anechoic fluid with occasional echogenic non-shadowing debris, most consistent with incidental suspended lipid in a cat, possibly combined with exfoliated cells, mucous and/or small blood clots. Both sterile inflammation as well as urinary tract infection can also present with echogenic debris. No masses or cystoliths are observed. The trigone and visible pelvic urethra are normal in thickness with a smooth mucosal surface.

SEX

Neutered Male

AGE

10/9/10

The right kidney is normal in size (4.44 cm), shape and echogenicity. It has smooth peripheral margination. There is a normal 1:3 cortex to medulla ratio with appropriate corticomedullary distinction. There is no evidence of pyelectasia, mineral or infarcts observed.

WEIGHT

11.4 Pounds

The left kidney is normal in size (3.85 cm), shape and echogenicity. It has smooth peripheral margination. There is a normal 1:3 cortex to medulla ratio with appropriate corticomedullary distinction. There is no evidence of pyelectasia, mineral or infarcts observed.

INTERPRETED BYBeth Johnson, DVM
DACVIM**Adrenal Glands**

The right adrenal gland is normal in size (0.46 cm), shape and contour. Corticomedullary structure is unremarkable. Visible surrounding vasculature appears normal.

IMAGING PERFORMED BY

The area of the left adrenal gland is examined without evident pathology.

Rachel Brillhart RDMS

Spleen

The spleen is subjectively normal in size with a normal smooth capsular contour. Parenchyma is appropriately finely textured and homogenous with normal echogenicity relative to surrounding tissue (hyperechoic to liver). No focal nodules or masses are observed. Splenic vasculature appears normal.

HOSPITAL NAME

Harborside Mobile VC

Liver

The liver is subjectively normal in size with normal smooth curvilinear peripheral contour. Parenchyma is appropriately hypoechoic to the spleen in echogenicity and appropriately mildly coarse and homogenous in echotexture. No focal lesions are observed. Visible vasculature and biliary tree appear normal without distension or congestion.

REFERRING VET

Dr. Hawkins

INVOICE

42726

The gallbladder is non-distended in size. The wall is smooth without visible thickening. Luminal contents are primarily anechoic. There is no evidence of cystic or common bile duct dilation.

Gastrointestinal

The stomach wall is normal in thickness (canine < 0.5 cm and feline < 0.4 cm) and layering. The lumen of the stomach is empty with no evidence of obstruction, foreign material or infiltrative disease. Pyloric outflow tract appears patent.

The visible small intestine demonstrates areas of very mildly thick muscularis layer relative to mucosa (disruption of the normal 1:3 muscularis:mucosa ratio). Small intestinal submucosa is slightly irregular, thick and hyperechoic, without evident loss of layering appreciated. The bowel changes may be mild due to current therapy. The lumen is empty with no evidence of obstruction or foreign material.

The visible colon is normal in wall thickness (< 0.2 cm) and layering. Contents are consistent with normal formed feces and gas.

Pancreas

Pancreas is prominent (enlarged) in size, hypoechoic to surrounding tissue and has a mildly irregular undulating contour. Parenchyma is coarse with mixed echogenic remodeling noted. Pancreatic duct dilation is noted. Hyperechoic mesenteric fat is surrounding the pancreas, suggestive of an acute flare up.

Free Abdomen

There is no evidence of free peritoneal effusion noted in these images.

The mesenteric lymph nodes are prominent in size with swollen capsular contour. Normal elongated shape (length to width ratio) is maintained. There is no loss of parenchymal detail.

PRIMARY FINDINGS

- Acute on chronic pancreatitis
- **Mild inflammatory bowel disease (IBD) pattern** – Thick muscularis has been reported with infiltrative bowel disease including both benign inflammatory disease as well as infiltrative neoplasia such as lymphoma. No aggressive lymphadenopathy, loss of layering, etc. is noted to make lymphoma more probable, but lymphoma cannot be definitively ruled out without tissue sampling.

SECONDARY FINDINGS

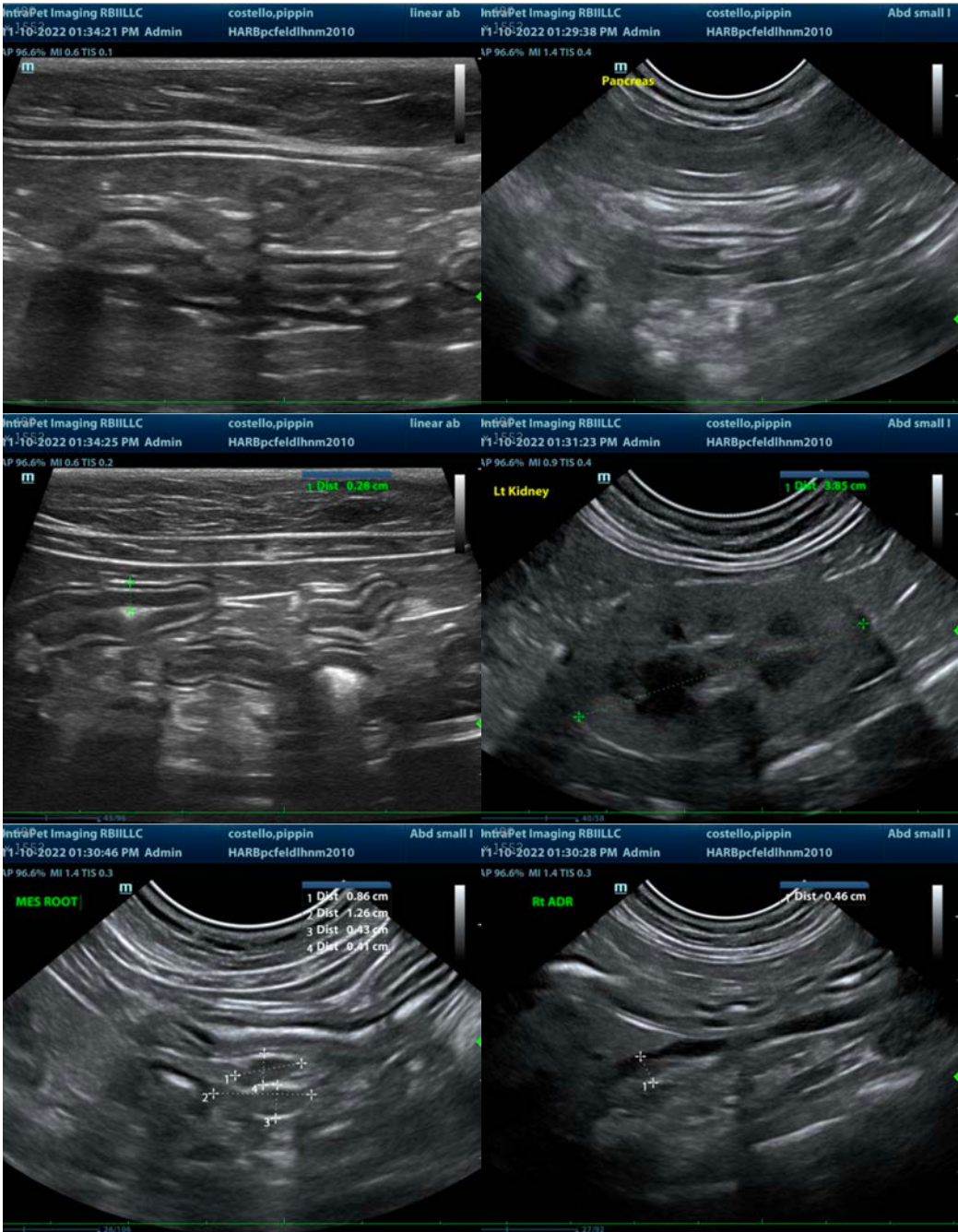
- Urinary bladder debris
- **Reactive mesenteric lymph nodes** – infiltrative neoplastic disease cannot be ruled out but is considered less likely.

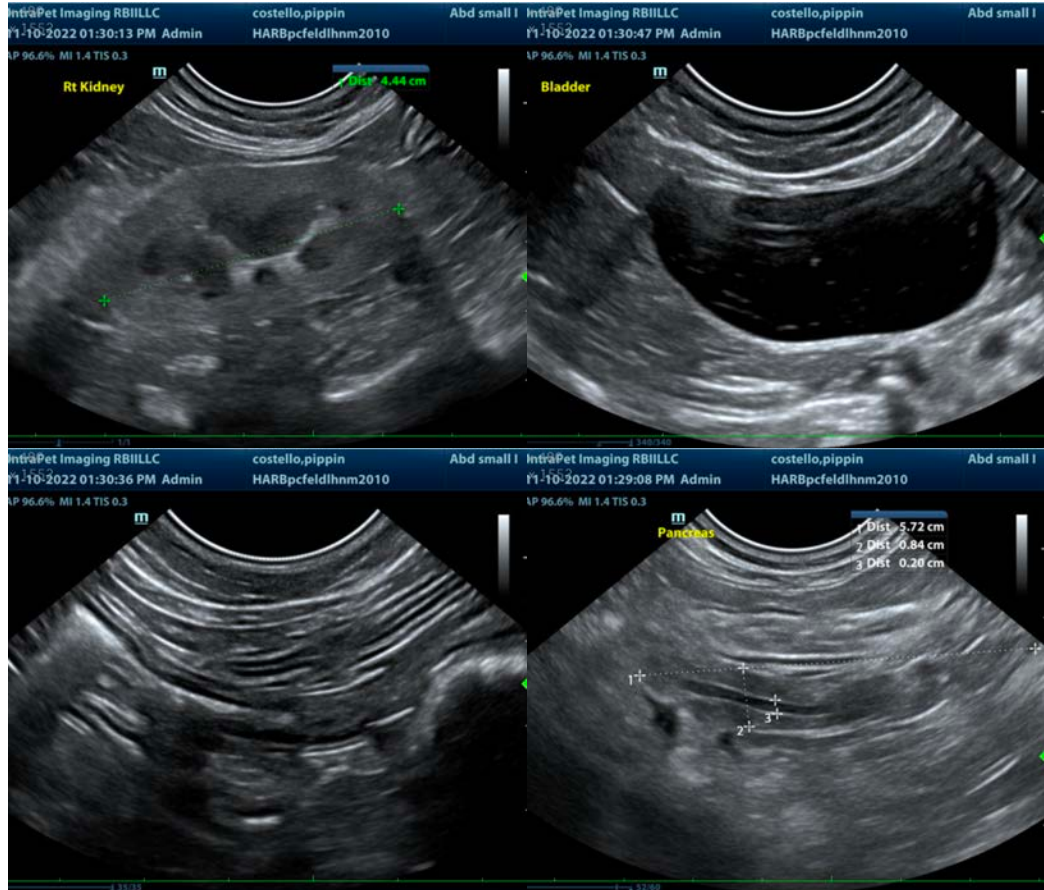
INTERPRETATION OF THE FINDINGS & FURTHER RECOMMENDATIONS

Further evaluation of the pancreas is recommended in the form of either a full gastrointestinal malabsorption panel to Texas A&M GI laboratory, or just a quantitative PLI. Given the recurrence of diarrhea, further evaluation for an underlying parasitic and/or infectious disease is recommended with a fecal exam and a fecal enteropathogen PCR panel to Texas A&M GI Laboratory.

In the meantime, supportive/symptomatic medical management of pancreatitis is recommended in the form of antiemetics, gastroprotectants, etc. if necessary, and continued probiotic and vitamin B12 administration as is already in place. Empirical deworming with a 5-day course of Panacur is recommended. If a secondary cause is not diagnosed and supportive management doesn't help improve the diarrhea, recheck biopsies or 1st time biopsies if biopsies have not been obtained previously may be indicated to definitively diagnose the suspected inflammatory bowel disease versus lymphoma, or transition from Budesonide to Prednisolone may be necessary.

If not recently evaluated, urinalysis and, if indicated based on urinalysis results, urine culture are recommended. If protein is present in an otherwise quiet sediment, protein quantification with a urine protein to creatinine ration is recommended.





The information and recommendations provided are based on the images presented by the referring veterinarian/sonographer. No evaluation can be communicated regarding pathology that was not visible in the image/video clips provided.

Thank you for this referral. If the clinical or image interpretation does not parallel your findings or if I can be of any further assistance please contact me.

Beth Johnson, DVM, DACVIM
Beth.Johnson@sonopath.com