

IMAGING PERFORMED BY

IntraPet.com



SonoPath

Clinical Sonography & Telectology

EDUCATIONAL TELECONSULTATION SERVICES™

1-800-838-4268 info@sonopath.com SonoPath.com

DATE PRESENTING CLINICAL SIGNS

11/10/22 Pet presented 11/2 for lethargy and checking a growth. O noted pet seems more sluggish than usual for a few weeks. Also noticed a growth on the caudal thigh that seems to be getting bigger. Pet also has had loose stools for about a week. Exam shows mild gingival hyperplasia and a 1 cm x 1 cm hairless raised mass caudal right thigh that is suggestive of a mast cell tumor.

PATIENT

Pepper Lianne Frazier

SPECIES

Canine

BREED

Pit Bull

SEX

Spayed Female

AGE

10/20/14

WEIGHT

64.3 Pounds

INTERPRETED BY

Beth Johnson, DVM
DACVIM

IMAGING PERFORMED BY

Rachel Brillhart RDMS

HOSPITAL NAME

Fullerton AH

REFERRING VET

Dr. Unger

INVOICE

42725

Current Medications: Provable capsules and paste.
Lab Results: Mild increase in HCT at 65% and increased PSL at 206
mast cells seen on cytology of mass
Date of Previous IntraPet Ultrasound: No previous.
Sedation: Not required to complete full diagnostic ultrasound.
Stat Report: Not requested.

ULTRASONOGRAPHIC EXAMINATION OF THE ABDOMEN

Urinary System

The urinary bladder is moderately distended with anechoic contents. No masses, inflammatory changes, echogenic sediment or cystoliths are observed. The urinary bladder, trigone and visible pelvic urethra are normal in thickness with a smooth mucosal surface.

The right kidney is normal in size (6.92 cm), shape and echogenicity. It has smooth peripheral margination. There is a normal 1:3 cortex to medulla ratio with appropriate corticomedullary distinction. There is no evidence of pyelectasia or infarcts observed. Non-obstructive areas of mineralization/nephroliths are noted.

The left kidney is normal in size (6.19 cm), shape and echogenicity. It has smooth peripheral margination. There is a normal 1:3 cortex to medulla ratio with appropriate corticomedullary distinction. There is no evidence of pyelectasia or infarcts observed. Non-obstructive areas of mineralization/nephroliths are noted.

Adrenal Glands

The right adrenal gland is normal in size (2.97 cm long x 0.97 cm at the cranial pole and 1.01 cm at the caudal pole), shape and contour. Corticomedullary structure is unremarkable. Visible surrounding vasculature appears normal.

The left adrenal gland is normal in size (2.69 cm long x 0.71 cm at the cranial pole and 0.68 cm at the caudal pole), shape and contour. Corticomedullary structure is unremarkable. Visible surrounding vasculature appears normal.

Spleen

The spleen is subjectively normal in size with a normal smooth capsular contour. Parenchyma is appropriately finely textured and homogenous with normal echogenicity relative to surrounding tissue (hyperechoic to liver). No focal nodules or masses are observed. Splenic vasculature appears normal.

Liver

Liver is subjectively enlarged (swollen contour). Mild parenchymal remodeling with diffusely mildly coarse architecture and increased portal markings is present. No focal nodules or masses are observed. Visible vasculature and biliary tree appear normal without distension or congestion.

The gallbladder is non-distended in size. The wall is smooth without visible thickening. Luminal contents are primarily anechoic. There is no evidence of cystic or common bile duct dilation.

Gastrointestinal

The visible stomach wall is normal in thickness and layering. The lumen of the stomach is mildly distended with echogenic non-shadowing luminal contents and gas consistent with normal ingesta. There is no evidence of obstruction, foreign material or infiltrative disease. Pyloric outflow tract appears patent.

The visible small intestines are normal in wall thickness and layering (canine duodenum < 0.5 cm and feline duodenum < 0.4 cm; other < 0.3 cm). Small intestinal motility appears adequate (1-3 contractions per min). The lumen of the small intestine is empty with no evidence of obstruction, foreign material or infiltrative disease.

The visible colon is normal in wall thickness (< 0.2 cm) and layering. Contents are consistent with normal formed feces and gas.

Pancreas

The pancreatic parenchyma is appropriately isoechoic to surrounding tissue. Visible capsule is smooth and normal in contour. There is no visible pancreatic duct dilation. There is no evidence of active peripancreatic inflammation.

Free Abdomen

There is no evidence of free peritoneal effusion noted in these images.

An isoechoic, normal shaped, prominent sublumber lymph node is noted, measuring 2.97 cm long x 0.62 cm thick.

PRIMARY FINDINGS

- **Hypoechoic hepatomegaly** – This appearance is consistent with an acute hepatopathy or acute cholangiohepatitis. Infiltrative neoplasia (round cell neoplasia) should also be considered.
- **Sublumber lymphadenopathy** – Both reactive lymphadenopathy as well as infiltrative neoplasia are differentials and cannot be differentiated without tissue sampling.

SECONDARY FINDINGS

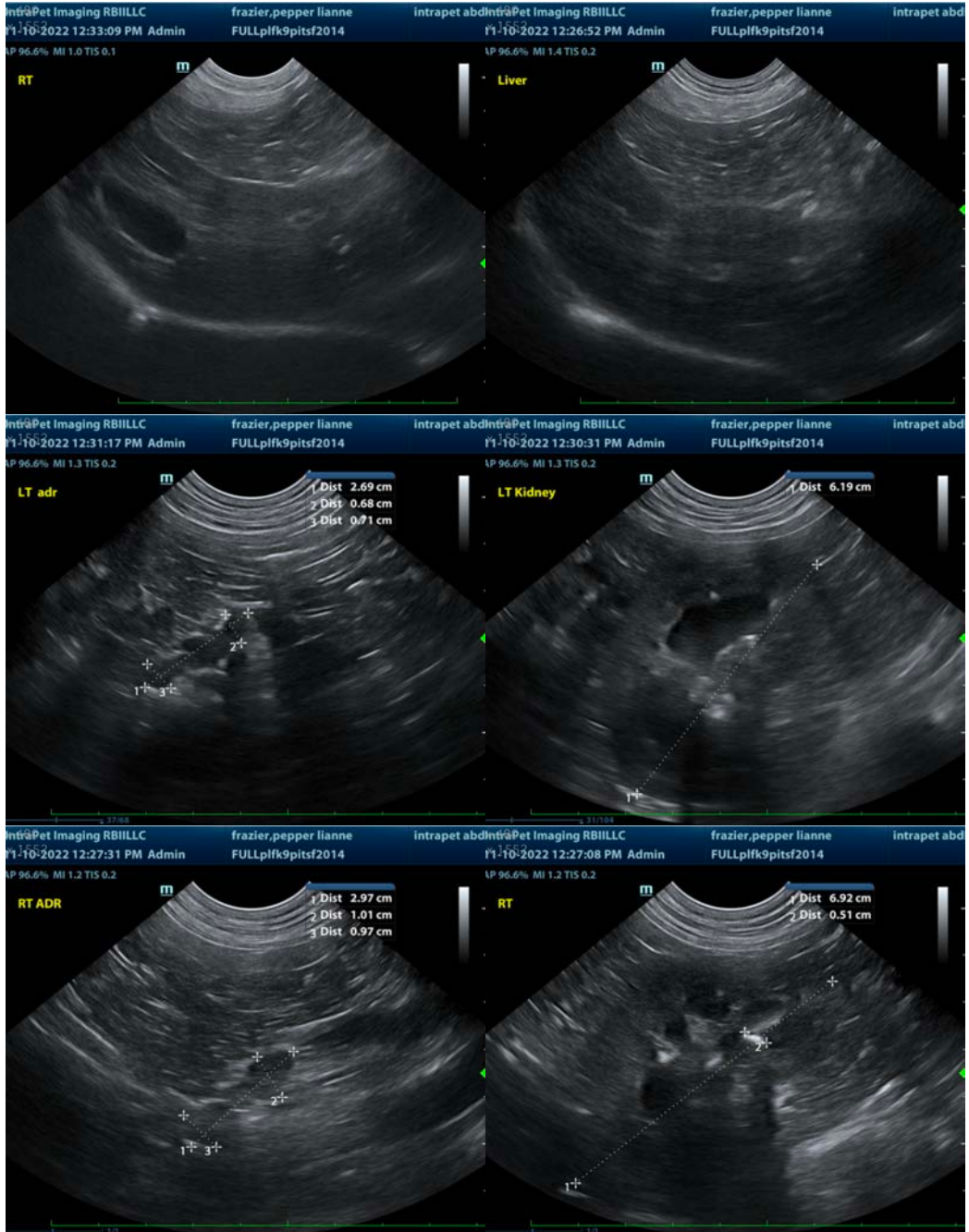
- Non-obstructive nephrolithiasis bilaterally in the kidneys

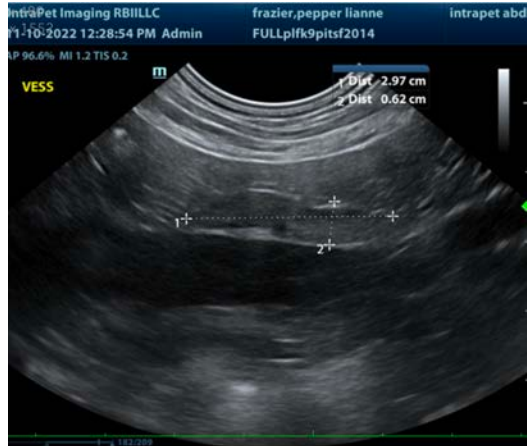INTERPRETATION OF THE FINDINGS & FURTHER RECOMMENDATIONS

A fine needle aspirate of the sublumber lymph node could be considered if it can safely be reached and if patient's coagulation status is appropriate. Premedication with diphenhydramine is recommended, given the history of mast cell tumor.

If the soft stool persists and further workup is necessary, a fecal exam is recommended, as is a gastrointestinal malabsorption panel (including cobalamin, folate, TLI and PLI) to Texas A&M GI Laboratory +/- A fecal enteropathogen PCR panel to Texas A&M GI Laboratory.

In the meantime, in addition to the probiotic, empirical deworming with a 5-day course of Panacur is recommended.





The information and recommendations provided are based on the images presented by the referring veterinarian/sonographer. No evaluation can be communicated regarding pathology that was not visible in the image/video clips provided.

Thank you for this referral. If the clinical or image interpretation does not parallel your findings or if I can be of any further assistance please contact me.

Beth Johnson, DVM, DACVIM
Beth.Johnson@sonopath.com