



| | |
|------------------------------|---|
| DATE | PRESENTING CLINICAL SIGNS |
| 11/10/22 | Recheck post alter (BPH w/ cysts). |
| PATIENT | Current Medications: None currently. Date of Previous IntraPet Ultrasound: 7/28/2022. See attached. Sedation: Not required to complete full diagnostic ultrasound. Stat Report: Not requested. |
| Dabke D'Ambrosio | |
| SPECIES | ULTRASONOGRAPHIC EXAMINATION OF THE ABDOMEN |
| Canine | Urinary System |
| BREED | The urinary bladder is moderately distended with anechoic contents. No masses, inflammatory changes, echogenic sediment or cystoliths are observed. The urinary bladder, trigone and visible pelvic urethra are normal in thickness with a smooth mucosal surface. |
| GSP | |
| SEX | The prostate appears normal now for a recently neutered dog and has shrunk in size from 6.2 cm wide to 3.3 cm wide. |
| Neutered Male | |
| AGE | The right kidney is normal in size (6.82 cm), shape and echogenicity. It has smooth peripheral margination. There is a normal 1:3 cortex to medulla ratio with appropriate corticomedullary distinction. There is no evidence of pyelectasia, mineral or infarcts observed. |
| 5/18/14 | |
| WEIGHT | The left kidney is normal in size (6.82 cm), shape and echogenicity. It has smooth peripheral margination. There is a normal 1:3 cortex to medulla ratio with appropriate corticomedullary distinction. There is no evidence of pyelectasia, mineral or infarcts observed. |
| 53 Pounds | |
| INTERPRETED BY | Adrenal Glands |
| Beth Johnson, DVM DACVIM | The right adrenal gland is normal in size (2.82 cm long x 0.68 cm at the cranial pole and 0.60 cm at the caudal pole), shape and contour. Corticomedullary structure is unremarkable. Visible surrounding vasculature appears normal. |
| IMAGING PERFORMED BY | The left adrenal gland is normal in size (2.5 cm long x 0.67 cm at the cranial pole and 0.62 cm at the caudal pole), shape and contour. Corticomedullary structure is unremarkable. Visible surrounding vasculature appears normal. |
| Stephanie Warga RDCS, RVT | |
| HOSPITAL NAME | Spleen |
| Bay Country VH | The spleen is subjectively normal in size with a normal smooth capsular contour. Parenchyma is appropriately finely textured and homogenous with normal echogenicity relative to surrounding tissue (hyperechoic to liver). No focal nodules or masses are observed. Splenic vasculature appears normal. |
| REFERRING VET | Liver |
| Dr. Bauer | The liver is subjectively normal in size with normal smooth curvilinear peripheral contour. Parenchyma is appropriately hypoechoic to the spleen in echogenicity and appropriately mildly coarse and homogenous in echotexture. No focal lesions are observed. Visible vasculature and biliary tree appear normal without distension or congestion. |
| INVOICE | The gallbladder is non-distended in size. The wall is smooth without visible thickening. Luminal contents are primarily anechoic. There is no evidence of cystic or common bile duct dilation. |
| 42721 | |

Gastrointestinal

The stomach wall is normal in thickness (canine < 0.5 cm and feline < 0.4 cm) and layering. The lumen of the stomach is empty with no evidence of obstruction, foreign material or infiltrative disease. Pyloric outflow tract appears patent.

The visible small intestines are normal in wall thickness and layering (canine duodenum < 0.5 cm and feline duodenum < 0.4 cm; other < 0.3 cm). Small intestinal motility appears adequate (1-3 contractions per min). The lumen of the small intestine is empty with no evidence of obstruction, foreign material or infiltrative disease.

The visible colon is normal in wall thickness (< 0.2 cm) and layering. Contents are consistent with normal formed feces and gas.

Pancreas

The pancreatic parenchyma is appropriately isoechoic to surrounding tissue. Visible capsule is smooth and normal in contour. There is no visible pancreatic duct dilation. There is no evidence of active peripancreatic inflammation.

Free Abdomen

There is no evidence of free peritoneal effusion noted in these images.

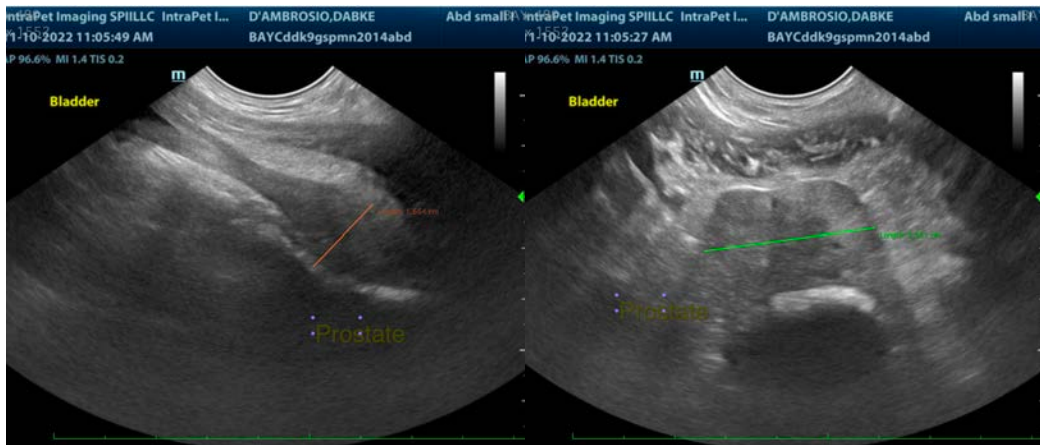
There is no apparent lymphadenopathy noted in these images.

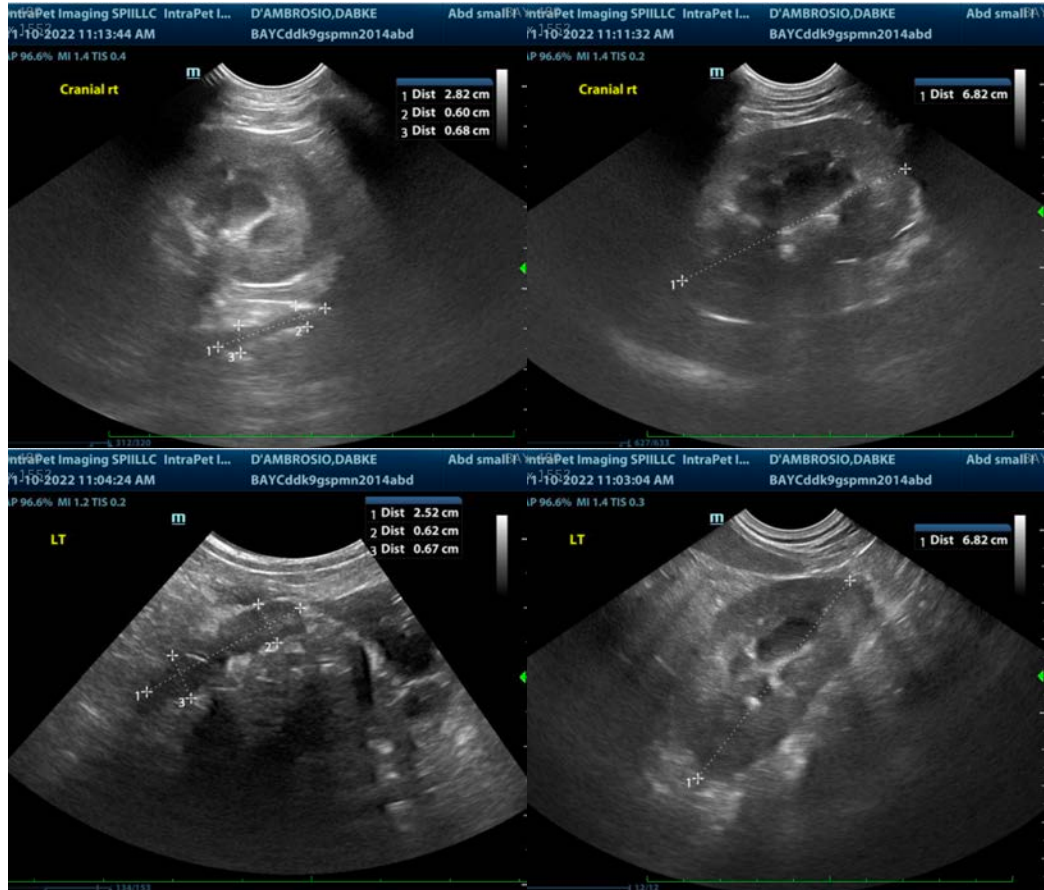
ULTRASONOGRAPHIC FINDINGS

- Normal/unremarkable abdomen with improved appearance to the previously described benign prostatic hyperplasia with cysts

INTERPRETATION OF THE FINDINGS & FURTHER RECOMMENDATIONS

No additional follow up recommended based on reported patient improvement, unless clinical signs return.





The information and recommendations provided are based on the images presented by the referring veterinarian/sonographer. No evaluation can be communicated regarding pathology that was not visible in the image/video clips provided.

Thank you for this referral. If the clinical or image interpretation does not parallel your findings or if I can be of any further assistance please contact me.

Beth Johnson, DVM, DACVIM
Beth.Johnson@sonopath.com