**PATIENT**

Ziggy Horne

SPECIES

Canine

BREED

Labrador Mix

SEX

Neutered Male

AGE

9 years

WEIGHT

103 Pounds

INTERPRETED BYBeth Johnson, DVM
DACVIM**IMAGING PERFORMED BY**

Amy Mayhew, LVT

HOSPITAL NAME

SVS Imaging Michigan

REFERRING VET

Family Pet Practice

INVOICE

42268

DATE

11/1/22

PRESENTING CLINICAL SIGNS

History: Current Medications: L Thyroxine .8 mg: 1 tab po q12 hr Heska Allergy Immunotherapy oral drops Patient History: See attached bloodwork- Hypercalcemia, mild elevation in ALP, Interested in dental in future. **O described over past month P has had a decreased appetite- was to the point that they were hand feeding to encourage P to eat, P has shown improvement over past couple of weeks Recommend AUS and chest rads- rule-out GI disease contributing to decreased appetite, possible reflux causing gagging vs pulmonary disease vs neoplasia vs age related disease

Abnormal PE/Chem/CBC/UA Results: 5. Mild to moderate generalized tartar- consider dental in near future. Rec. AUS, thoracic rads prior to anesthesia due to hx. 6. normal heart sounds. 7. panting during exams, lungs otherwise sound normal- Recent hx of gagging - rule-out GI vs respiratory vs lar par. Panting is not harsh, no change in bark noted at home- reviewed monitoring for lar par, can have laryngeal exam with surgeon but P does not seem to be overtly lar par today. Recommend thoracic radiographs with upper airway as well Recommend 2 week trial of omeperazole 20mg 1 tab PO BID to see if antacid helps with gagging 8. Alopecia with hyperpigmentation and thickened dermis right proximal forelimb, focal alopecia left forelimb with hyperpigmentation- dermis otherwise smooth. Thin roughened coat over tail- chronic ** BODY MAP linked to account. 9/10. mildly tense on abdominal palpation, rectal exam- mildly thickened left colonic tissue near left anal sac- no palpable masses or polyps- monitor for anal sacculitis/scooting/licking- may correlate with allergies (o noted recent flare-up of allergies 11. Prominent submandibular LN but not overtly abnormal for P size- recommend monitoring for growth Hx of atopy, currently doing well with immunotherapy 12. Reduced hip extension bilaterally- O has noted P slowing down recently- discussed option to start galliprant - recommend bloodwork prior to. 13. Weight gain noted- Recently rested for lameness (seen at ovsr?), weight gain may be due to decreased activity. **O described over past month P has had a decreased appetite- was to the point that they were hand feeding to encourage P to eat, P has shown improvement over past couple of weeks Recommend AUS and chest rads- rule-out GI disease contributing to decreased appetite, possible reflux causing gagging vs pulmonary disease vs neoplasia vs age related disease

ULTRASONOGRAPHIC EXAMINATION OF THE ABDOMEN**Urinary System**

Urinary bladder is adequately distended. It has a normal uniform wall thickness. Contents include primarily anechoic fluid with occasional echogenic non-shadowing debris, most consistent with exfoliated cells, mucous and/or small blood clots. Some mineral debris and potentially even tiny cystoliths are suspected. Both sterile inflammation as well as urinary tract infection can also present with echogenic debris. No masses or cystoliths are observed. The trigone and visible pelvic urethra are normal in thickness with a smooth mucosal surface.

Prostate (neutered) is normal in size, echotexture and echogenicity for a neutered male.

Left kidney is normal is size (7.17 cm), shape and echogenicity. It has smooth peripheral margination. There is a normal 1:3 cortex to medulla ratio with appropriate corticomedullary distinction. Non-obstructive linear multifocal hyperechoic diverticular foci with acoustic shadowing are noted. There is no evidence of pyelectasia or infarcts observed.

Right kidney is normal is size (6.83 cm), shape and echogenicity. It has smooth peripheral margination. There is a normal 1:3 cortex to medulla ratio with appropriate corticomedullary distinction. Non-obstructive linear multifocal hyperechoic diverticular foci with acoustic shadowing are noted. There is no evidence of pyelectasia or infarcts observed.

IMAGING PERFORMED BY

SVS Mobile Imaging MI 734-637-7711
svsimagingmi@gmail.com

**PATIENT**

Ziggy Horne

Adrenal Glands

Left adrenal gland is normal in size (0.54 cm at cranial pole and 0.64 cm at caudal pole), shape and overall architecture, echogenicity and echotexture. Visible surrounding vasculature appears normal.

SPECIES

Canine

Right adrenal gland is normal in size (0.64 cm at cranial pole and 0.86 cm at caudal pole), shape and overall architecture, echogenicity and echotexture. Visible surrounding vasculature appears normal.

BREED

Labrador Mix

Spleen

Spleen is subjectively large in size with normal smooth margins. Parenchyma is normal in echogenicity with a coarse/heterogenous echotexture. A 0.6 cm non-capsular disrupting, hypoechoic nodule was noted in the mid body. Splenic vasculature appears normal.

SEX

Neutered Male

Liver

Liver is subjectively normal in size with normal smooth curvilinear peripheral contour. Parenchyma is appropriately hypoechoic to the spleen in echogenicity and appropriately mildly coarse and homogenous in echotexture. No focal lesions are observed. Visible vasculature and biliary tree appear normal without distension or congestion.

AGE

9 years

WEIGHT

103 Pounds

Gallbladder is non-distended in size. The wall is smooth without visible thickening. Luminal contents are primarily anechoic. There is no evidence of cystic or common bile duct dilation.

INTERPRETED BY

Beth Johnson, DVM
DACVIM

Gastrointestinal

The visible stomach wall is normal in thickness and layering. The lumen of the stomach is mildly distended with very echogenic reverberation artifact from intraluminal gas. There is no evidence of obstruction, foreign material or infiltrative disease; however, complete visualization of far wall is partially inhibited by gas. Pyloric outflow tract appears patent.

IMAGING PERFORMED BY

Amy Mayhew, LVT

The visible small intestines are normal in wall thickness and layering. Small intestinal motility appears adequate (1-3 contractions per min). Some intraluminal gas was noted. The lumen of the small intestine is mildly distended with echogenic non-shadowing luminal contents and gas consistent with normal ingesta. There is no evidence of obstruction, foreign material or infiltrative disease.

HOSPITAL NAME

SVS Imaging Michigan

The visible colon is normal in wall thickness (< 0.2 cm) and layering. Contents are consistent with normal formed feces and gas.

REFERRING VET

Family Pet Practice

Pancreas

The observed pancreas appears appropriately isoechoic to surrounding omental fat. Visible capsule is smooth and normal in contour. Visible pancreatic parenchyma is homogenous and unremarkable. There is no visible pancreatic duct dilation. There is no evidence of active peripancreatic inflammation.

INVOICE

42268

DATE

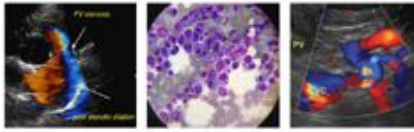
11/1/22

Free Abdomen

There is no evidence of free peritoneal effusion noted in these images.

IMAGING PERFORMED BY

SVS Mobile Imaging MI 734 - 637 - 7711
svsimagingmi@gmail.com



PATIENT

There is no apparent lymphadenopathy noted in these images.

Ziggy Horne

SPECIES

Canine

BREED

Labrador Mix

SEX

Neutered Male

AGE

9 years

WEIGHT

103 Pounds

INTERPRETED BY

Beth Johnson, DVM
DACVIM

IMAGING PERFORMED BY

Amy Mayhew, LVT

HOSPITAL NAME

SVS Imaging Michigan

REFERRING VET

Family Pet Practice

INVOICE

42268

DATE

11/1/22

ULTRASONOGRAPHIC FINDINGS

Primary Findings

- **Coarse splenomegaly** – can be associated with congestion caused by sedation (if sedated) but can also be associated with diffuse infiltrative disease. Both benign conditions such as extramedullary hematopoiesis, lymphoid hyperplasia as well as infiltrative neoplastic diseases such as round cell neoplasia should be considered.
- **Subjectively diffusely, gassy gastrointestinal tract.**

Secondary Findings

- **Urinary bladder debris.** Suspect, tiny cystoliths and non-obstructive, dystrophic mineralization bilaterally in the kidneys.

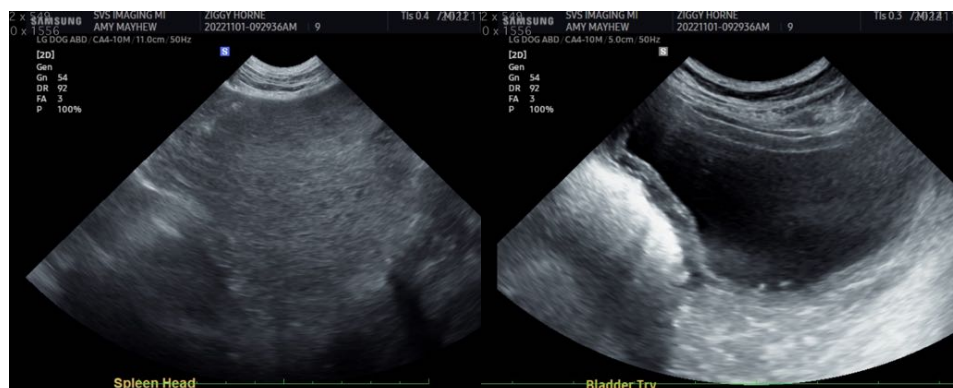INTERPRETATION OF THE FINDINGS & FURTHER RECOMMENDATIONS

Given the patient’s decreased appetite and subjectively gassy gastrointestinal tract:

1. A gastrointestinal malabsorption panel (including cobalamin, folate, TLI and PLI) to Texas A&M GI Laboratory is recommended for further evaluation of GI and pancreatic function.
2. Especially given the eosinophilia, a baseline cortisol is recommended. If baseline cortisol is less than 2, a full ACTH stimulation test is recommended to rule out hypoadrenocorticism.

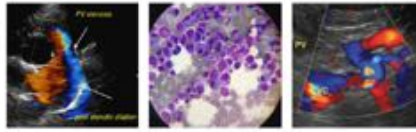
Given the reported hypercalcemia further investigation is recommended to try to determine underlying cause of the hypercalcemia and therefore manage it as a potential cause for decreased appetite beginning with a malignancy panel to include PTH, PTHrP, and ionized calcium.

In the meantime, empirical therapy can include deworming with a 5 day course of Panacur, antacid therapy as is reportedly already being considered and transition in diet based on trial and error response potentially beginning with a bland, easy to digest diet or healthy biome diet potentially a hydrolyzed protein diet.



IMAGING PERFORMED BY

SVS Mobile Imaging MI 734-637-7711
svsimagingmi@gmail.com



EDUCATIONAL TELECONSULTATION SERVICES™
1-800-838-4268 info@sonopath.com SonoPath.com

PATIENT

Ziggy Horne

SPECIES

Canine

BREED

Labrador Mix

SEX

Neutered Male

AGE

9 years

WEIGHT

103 Pounds

INTERPRETED BY

Beth Johnson, DVM
DACVIM

IMAGING PERFORMED BY

Amy Mayhew, LVT

HOSPITAL NAME

SVS Imaging Michigan

REFERRING VET

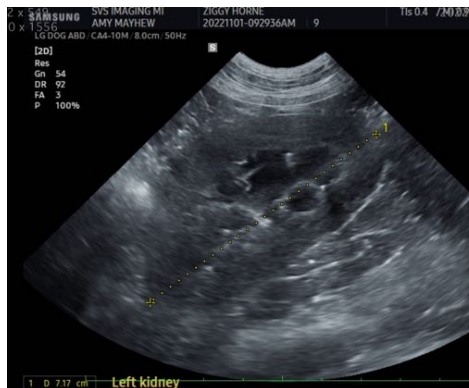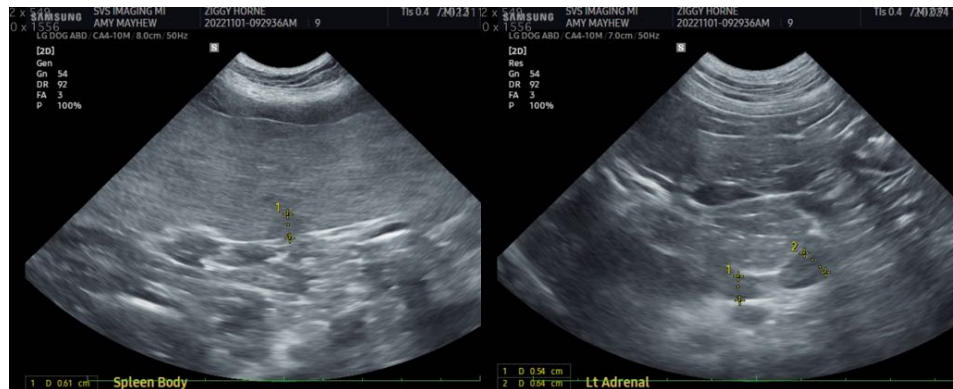
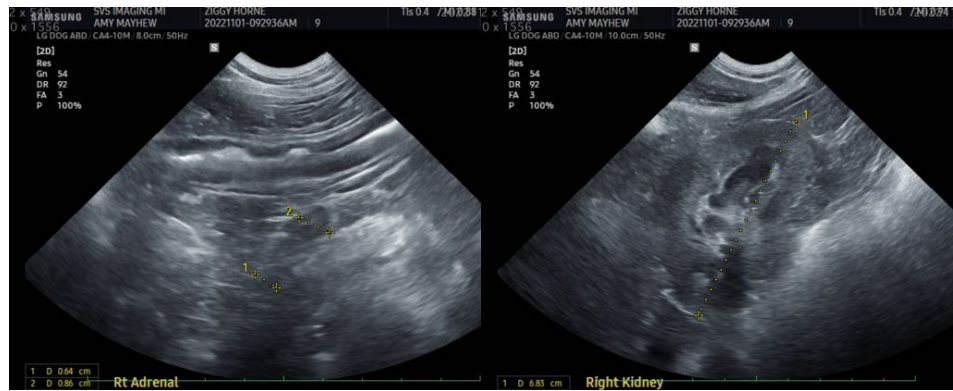
Family Pet Practice

INVOICE

42268

DATE

11/1/22



The information and recommendations provided are based on the images presented by the referring veterinarian/sonographer. No evaluation can be communicated regarding pathology that was not visible in the image/video clips provided.

Thank you for this referral. If the clinical or image interpretation does not parallel your findings or if I can be of any further assistance please contact me.

Beth Johnson, DVM DACVIM

Beth.Johnson@SonoPath.com