



**PATIENT**

Rosco Gerrity

**SPECIES**

Canine

**BREED**

Lab

**SEX**

Neutered Male

**AGE**

9 Years

**WEIGHT**

37.6 kg

**INTERPRETED BY**

Beth Johnson, DVM  
DACVIM

**IMAGING PERFORMED BY**

Erin Wicks

**HOSPITAL NAME**

Shores VEC

**REFERRING VET**

Dr. Miller

**INVOICE**

41925

**DATE**

10/9/22

**PRESENTING CLINICAL SIGNS**

Presented at our hospital for vomiting and diarrhea. O stated P started eating less in August, and vomited once in September when O was away at the beach. P started only picking at food, so P was taken to RDVM and found to be anaplasmosis positive. O was only able to give doxycycline for ~8d before P stopped eating. RDVM started P on z/d, and was going to start enrofloxacin if P did not vomit for 3 days. P vomited on day 3, which was Thursday. Today, P has several bouts of diarrhea which O described as bright yellow. O is concerned as there are a lot of feral cats in the area, and P recently rolled around in feces. Previous Health Concerns: Lyme positive in the past, anxiety with fireworks etc Current Medications: composure pills

Abnormal PE/Chem/CBC/UA Results: Abdominal: doughy; borborygma heard Rad at rDVM- no obvious masses/ effusions; Blood work at rDVM- all NR except (+) Lyme and Anaplasma EPOC today-(iCa)= 1.48(H) Na 154(H) Lymphatics: all peripheral Inn enlarged

**ULTRASONOGRAPHIC EXAMINATION OF THE ABDOMEN**

**Urinary System**

The urinary bladder is moderately distended with anechoic contents. No masses, inflammatory changes, echogenic sediment or cystoliths are observed. The urinary bladder, trigone and visible pelvic urethra are normal in thickness with a smooth mucosal surface.

The area of the prostate is examined without evident pathology.

The right kidney is normal in size (7.34 cm), shape and echogenicity. It has smooth peripheral margination. There is a normal 1:3 cortex to medulla ratio with appropriate corticomedullary distinction. There is no evidence of pyelectasia or infarcts observed. Non-obstructive linear multifocal hyperechoic diverticular foci with acoustic shadowing are noted.

The left kidney is normal in size (7.14 cm), shape and echogenicity. It has smooth peripheral margination. There is a normal 1:3 cortex to medulla ratio with appropriate corticomedullary distinction. There is no evidence of pyelectasia or infarcts observed. Non-obstructive linear multifocal hyperechoic diverticular foci with acoustic shadowing are noted.

**Adrenal Glands**

The area of the right adrenal gland is examined without evident pathology.

The left adrenal gland is normal in size (0.90 cm at the cranial pole and 0.90 cm at the caudal pole), shape and contour. Corticomedullary structure is unremarkable. Visible surrounding vasculature appears normal.

**Spleen**

The spleen is subjectively normal in size with a normal smooth capsular contour. Parenchyma is appropriately finely textured and homogenous with normal echogenicity relative to surrounding tissue (hyperechoic to liver). No focal nodules or masses are observed. Splenic vasculature appears normal.

**Liver**

The liver is subjectively normal in size with normal smooth curvilinear peripheral contour. Parenchyma is appropriately hypoechoic to the spleen in echogenicity and appropriately mildly coarse and homogenous in echotexture. No focal lesions are observed. Visible vasculature and biliary tree appear normal without distension or congestion.



<b>PATIENT</b>	The gallbladder is non-distended in size. The wall is smooth without visible thickening. Luminal contents are primarily anechoic. There is no evidence of cystic or common bile duct dilation.
Rosco Gerrity	
<b>SPECIES</b>	<b>Gastrointestinal</b>
Canine	The stomach wall is normal in thickness (canine < 0.5 cm and feline < 0.4 cm) and layering. The lumen of the stomach is empty with no evidence of obstruction, foreign material or infiltrative disease. Pyloric outflow tract appears patent.
<b>BREED</b>	The visible small intestines are normal in wall thickness and layering (canine duodenum < 0.5 cm and feline duodenum < 0.4 cm; other < 0.3 cm). Small intestinal motility appears adequate (1-3 contractions per min). The lumen of the small intestine is empty with no evidence of obstruction, foreign material or infiltrative disease.
Lab	
<b>SEX</b>	The visible colon is normal in wall thickness (< 0.2 cm) and layering. Contents are consistent with normal formed feces and gas.
Neutered Male	
<b>AGE</b>	<b>Pancreas</b>
9 Years	The pancreatic parenchyma is appropriately isoechoic to surrounding tissue. Visible capsule is smooth and normal in contour. There is no visible pancreatic duct dilation. There is no evidence of active peripancreatic inflammation.
<b>WEIGHT</b>	<b>Free Abdomen</b>
37.6 kg	There is no evidence of free peritoneal effusion noted in these images.
<b>INTERPRETED BY</b>	Medial iliac and mesenteric lymph nodes are enlarged with swollen irregular capsular contour and loss of normal length to width ratio (rounded in shape). Nodes are hypoechoic with loss of normal parenchymal detail.
Beth Johnson, DVM DACVIM	<b>PRIMARY FINDINGS</b>
<b>IMAGING PERFORMED BY</b>	<ul style="list-style-type: none"> <li><b>Aggressive medial iliac and mesenteric lymph nodes</b> – most consistent with infiltrative round cell or metastatic neoplasia. A benign aggressive inflammatory response cannot be ruled out without tissue sampling +/- culture.</li> </ul>
Erin Wicks	<b>SECONDARY FINDINGS</b>
<b>HOSPITAL NAME</b>	<ul style="list-style-type: none"> <li><b>Non-obstructive dystrophic mineralization bilaterally in the kidneys</b> – most consistent with infiltrative round cell or metastatic neoplasia. A benign aggressive inflammatory response cannot be ruled out without tissue sampling +/- culture.</li> </ul>
Shores VEC	<b>INTERPRETATION OF THE FINDINGS &amp; FURTHER RECOMMENDATIONS</b>
<b>REFERRING VET</b>	Given this patient's reported peripheral lymphadenomegaly and hypercalcemia, the top differential is lymphoma. Recommendations include aspiration of the peripheral lymph nodes as a less invasive option, and if a diagnosis is not obtained cytologically, then an aspirate of a medial iliac and/or mesenteric lymph node could be considered. While it's possible for some infectious disease to cause diffuse lymphadenopathy and even hypercalcemia when associated with granulomatous disease, it's not typically seen with the infectious diseases reported in this patient.
Dr. Miller	
<b>INVOICE</b>	
41925	
<b>DATE</b>	
10/9/22	



**PATIENT**

Rosco Gerrity

**SPECIES**

Canine

**BREED**

Lab

**SEX**

Neutered Male

**AGE**

9 Years

**WEIGHT**

37.6 kg

**INTERPRETED BY**

Beth Johnson, DVM  
DACVIM

**IMAGING PERFORMED BY**

Erin Wicks

**HOSPITAL NAME**

Shores VEC

**REFERRING VET**

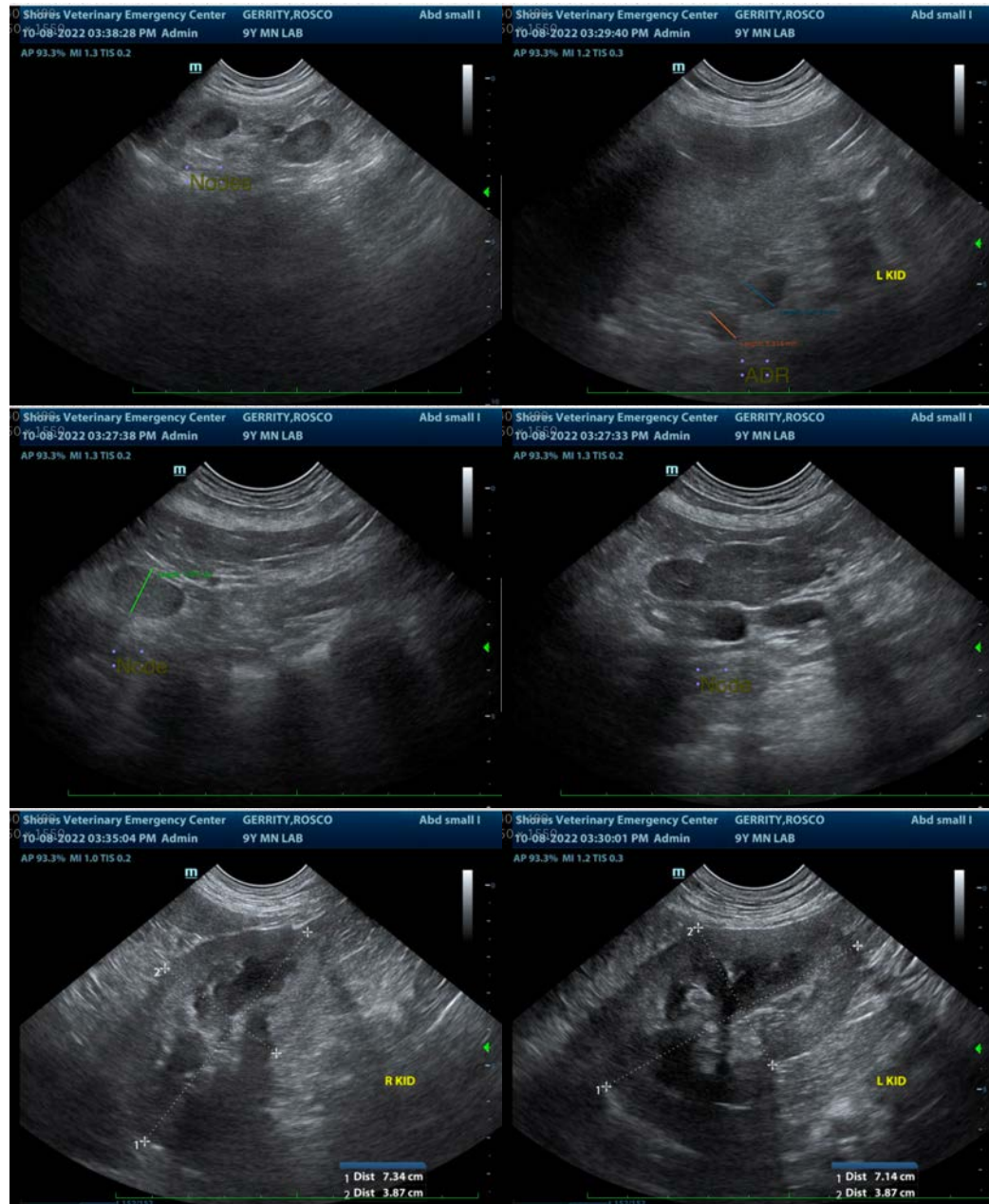
Dr. Miller

**INVOICE**

41925

**DATE**

10/9/22



The information and recommendations provided are based on the images presented by the referring veterinarian/sonographer. No evaluation can be communicated regarding pathology that was not visible in the image/video clips provided.

Thank you for this referral. If the clinical or image interpretation does not parallel your findings or if I can be of any further assistance please contact me.

Beth Johnson, DVM, DACVIM  
Beth.Johnson@sonopath.com