



**PATIENT**

Penny Cummings

**SPECIES**

Canine

**BREED**

Australian Shepherd

**SEX**

Spayed Female

**AGE**

9 years

**WEIGHT**

53 lbs

**INTERPRETED BY**

Beth Johnson, DVM  
DACVIM

**IMAGING PERFORMED BY**

Dr. Rodriguez

**HOSPITAL NAME**

Foxfield VS

**REFERRING VET**

Dr. Rodriguez

**INVOICE**

92238

**DATE**

10/7/21

**PRESENTING CLINICAL SIGNS**

History: Annual bloodwork. Urine culture pending  
TP: 7.7, Alb:4.7, Cal: 12.2, Mag: 3.3, Sodium: 155 USG: 1.043, Ca Ox 11-20, Bacteria <10,

**ULTRASONOGRAPHIC EXAMINATION OF THE ABDOMEN**

**Urinary System**

Urinary bladder is moderately distended with anechoic contents. It has normal uniform wall thickness (< 0.2 cm). No masses or cystoliths are observed.

Left kidney is normal in size (5.82 cm), shape and echogenicity. It has smooth peripheral margination and appropriate corticomedullary distinction. There is no pyelectasia noted. No mineral is observed.

Right kidney is normal in size (6.41 cm), shape and echogenicity. It has smooth peripheral margination and appropriate corticomedullary distinction. There is no pyelectasia noted. No mineral is observed.

**Adrenal Glands**

Left adrenal gland is normal in size (0.49 cm at cranial pole and 0.59 cm at caudal pole), shape and contour. Corticomedullary structure is unremarkable.

Right adrenal gland is normal in size (0.63 cm at cranial pole and 0.78 cm at caudal pole), shape and contour. Corticomedullary structure is unremarkable.

**Spleen**

Spleen is subjectively normal in size with normal smooth margins. Parenchyma is normal in echogenicity and echotexture. No focal nodules or masses are observed. Splenic vasculature appears normal.

**Liver**

Liver is subjectively normal in size. Margins are sharp and smooth. It has normal homogenous echotexture and normal echogenicity. No focal lesions are observed. Visible vasculature appears normal. Gallbladder is mildly distended with anechoic contents. The wall is smooth without visible thickening. There is no evidence of common bile duct dilation.

**Gastrointestinal**

The visible gastric wall is normal in thickness (canine < 0.5 cm and feline < 0.4 cm). The stomach is empty.

The small intestines are normal in wall thickness and layering. Small intestinal motility appears adequate (1-3 contractions per min). There are no luminal contents noted within small intestines.

Colon is normal in wall thickness (< 0.2 cm) and layering.



**PATIENT**

**Pancreas**

Penny Cummings

Pancreas has normal homogenous echotexture and is normal in echogenicity and smooth margination. There is no evidence of peripancreatic inflammation.

**SPECIES**

Canine

**Free Abdomen**

The medial iliac lymph nodes are measured at 0.9 x 0.37 cm thick.

**BREED**

Australian Shepherd

**ULTRASONOGRAPHIC FINDINGS**

**SEX**

Spayed Female

**Primary Findings**

Mild, most likely reactive medial iliac lymphadenopathy.

**AGE**

9 years

**INTERPRETATION OF THE FINDINGS & FURTHER RECOMMENDATIONS**

Given the patient's mild lymphadenopathy and hypercalcemia include a thorough anal sac evaluation via rectal exam if not already evaluated to rule out paraneoplastic hypercalcemia secondary to anal gland neoplasia followed by, if anal glands are normal, a malignancy panel including an ionized calcium, PTH and PTHrP to further investigate the hypercalcemia. If physical exam is normal the top differential for the hypercalcemia is hyperthyroidism.

**WEIGHT**

53 lbs

**INTERPRETED BY**

Beth Johnson, DVM  
DACVIM

**IMAGING PERFORMED BY**

Dr. Rodriguez

**HOSPITAL NAME**

Foxfield VS

**REFERRING VET**

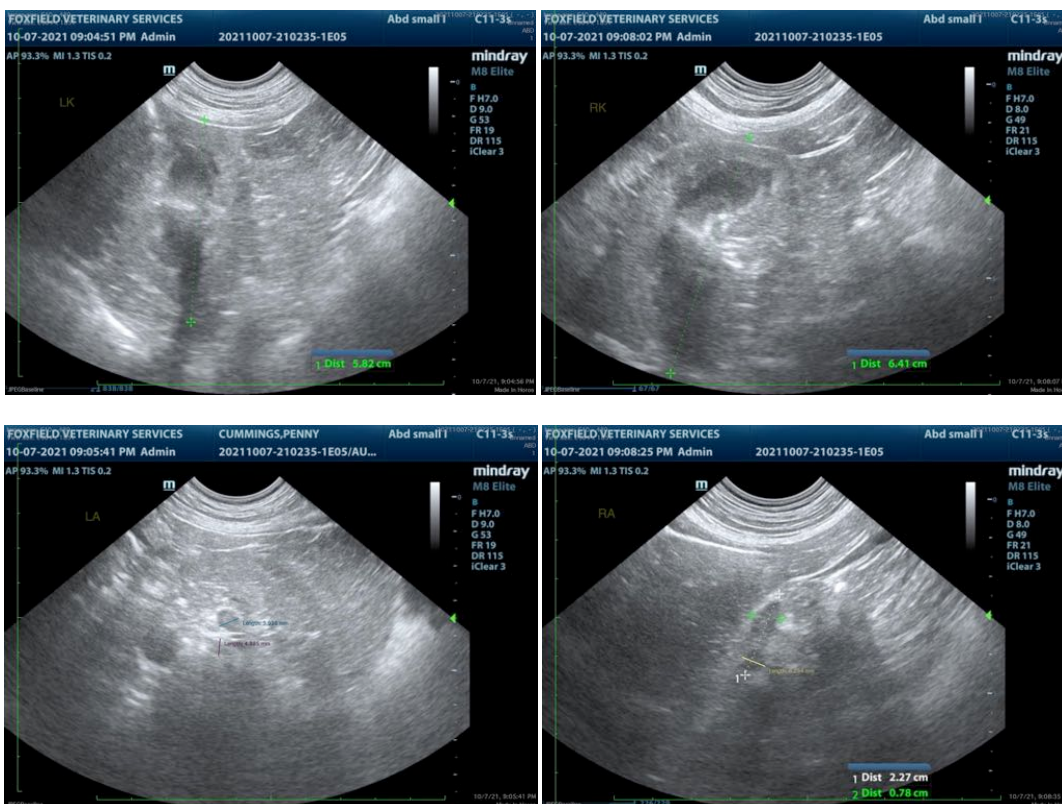
Dr. Rodriguez

**INVOICE**

92238

**DATE**

10/7/21





**PATIENT**

Penny Cummings

**SPECIES**

Canine

**BREED**

Australian Shepherd

**SEX**

Spayed Female

**AGE**

9 years

**WEIGHT**

53 lbs

**INTERPRETED BY**

Beth Johnson, DVM  
DACVIM

**IMAGING PERFORMED BY**

Dr. Rodriguez

**HOSPITAL NAME**

Foxfield VS

**REFERRING VET**

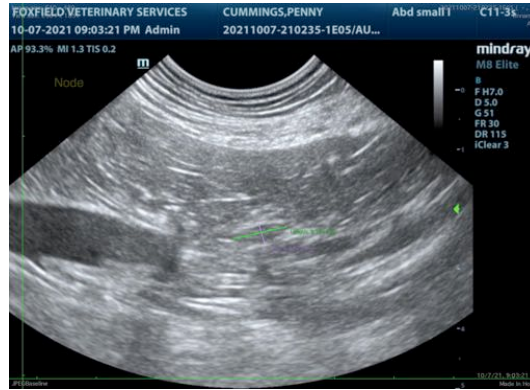Dr. Rodriguez

**INVOICE**

92238

**DATE**

10/7/21



The information and recommendations provided are based on the images presented by the referring veterinarian. No evaluation can be communicated regarding pathology that was not visible in the image/video clips provided.

Thank you for this referral. If the clinical or image interpretation does not parallel your findings or if I can be of any further assistance please contact me.

**Beth Johnson, DVM DACVIM**

Beth.Johnson@SonoPath.com