

**DATE PRESENTING CLINICAL SIGNS**

10/6/22

Anorexia, weight loss, vomiting, eye twitch. CVRC diagnosed with a ruptured ear drum and treated with Rimadyl, Cerenia, Codine and Enrofloxacin.

**PATIENT**

Sesame Hinkle

Current Medications: Cerenia 60mg SID, Entyce.  
Lab Results: WNL.  
Radiographs: Possible foreign body in stomach and abnormal spots in chest.

**SPECIES**

Canine

Date of Previous IntraPet Ultrasound: No previous.  
Sedation: Not required to complete full diagnostic ultrasound.  
Stat Report: Not requested.  
Imaging Performed By: Rachel Brillhart, RDMS.

**BREED**

Hound Mix

**ULTRASONOGRAPHIC EXAMINATION OF THE ABDOMEN**  
**Urinary System**

**SEX**

Neutered male

Urinary bladder is adequately distended with anechoic contents. No masses, inflammatory changes, echogenic sediment or cystoliths are observed. The urinary bladder, trigone and visible pelvic urethra are normal in thickness with a smooth mucosal surface.

**AGE**

10/27/20

The area of the prostate appears very pelvic and is difficult to fully visualize in these images.

**WEIGHT**

51.2 lbs

Left kidney is normal is size (6.47 cm), shape and echogenicity. It has smooth peripheral margination. There is a normal 1:3 cortex to medulla ratio with appropriate corticomedullary distinction. There is no evidence of pyelectasia, mineral or infarcts observed.

Right kidney is normal is size (6.86 cm), shape and echogenicity. It has smooth peripheral margination. There is a normal 1:3 cortex to medulla ratio with appropriate corticomedullary distinction. There is no evidence of pyelectasia, mineral or infarcts observed.

**INTERPRETED BY**

Beth Johnson, DVM  
DACVIM

**Adrenal Glands**

Left adrenal gland is normal in size (2.7 cm long, 0.61 cm at cranial pole and 0.6 cm at caudal pole), shape and overall architecture, echogenicity and echotexture. Visible surrounding vasculature appears normal.

**HOSPITAL NAME**

Animal Emergency  
Hospital

Right adrenal gland is normal in size (2.6 cm long, 0.7 at cranial pole and 0.7 cm at caudal pole), shape and overall architecture, echogenicity and echotexture. Visible surrounding vasculature appears normal.

**REFERRING VET**

**Spleen**

Spleen is subjectively normal in size with a normal smooth capsular contour. Parenchyma is appropriately finely textured and homogenous with normal echogenicity relative to surrounding tissue (hyperechoic to liver). No focal nodules or masses are observed. Splenic vasculature appears normal.

**INVOICE**

39952

**Liver**

Liver is subjectively normal in size with normal smooth curvilinear peripheral contour. Parenchyma is appropriately hypoechoic to the spleen in echogenicity and appropriately mildly coarse and homogenous in echotexture. No focal lesions are observed. Visible vasculature and biliary tree appear normal without distension or congestion.

Gallbladder is non-distended in size. The wall is smooth without visible thickening. Luminal contents are primarily anechoic. There is no evidence of cystic or common bile duct dilation.

### ***Gastrointestinal***

The stomach wall appears mildly thick and measures approximately 1.0 cm thick, however, the stomach is empty and folded with prominent rugal folds, so normal patient variant is considered most likely.

The visible small intestines are normal in wall thickness and layering. Small intestinal motility appears adequate (1-3 contractions per min). The lumen of the small intestine is empty with no evidence of obstruction, foreign material or infiltrative disease.

The visible colon is normal in wall thickness (< 0.2 cm) and layering. Contents are consistent with normal formed feces and gas.

### ***Pancreas***

The observed pancreas appears appropriately isoechoic to surrounding omental fat. Visible capsule is smooth and normal in contour. Visible pancreatic parenchyma is homogenous and unremarkable. There is no visible pancreatic duct dilation. There is no evidence of active peripancreatic inflammation.

### ***Free Abdomen***

There is no evidence of free peritoneal effusion noted in these images.

There is no apparent lymphadenopathy noted in these images.

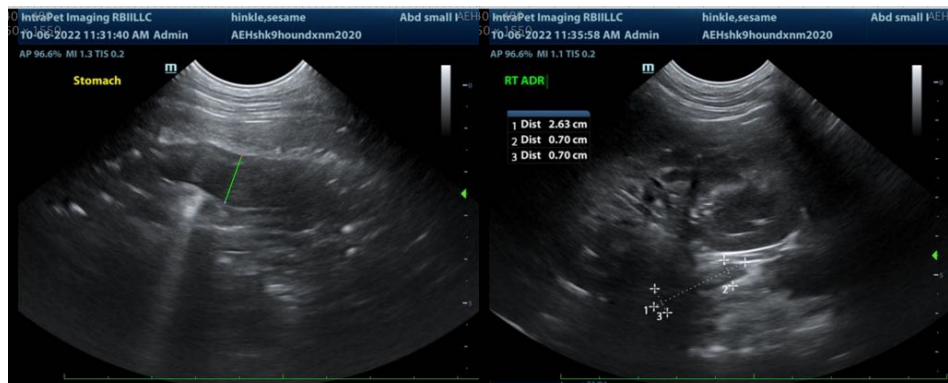## **ULTRASONOGRAPHIC FINDINGS**

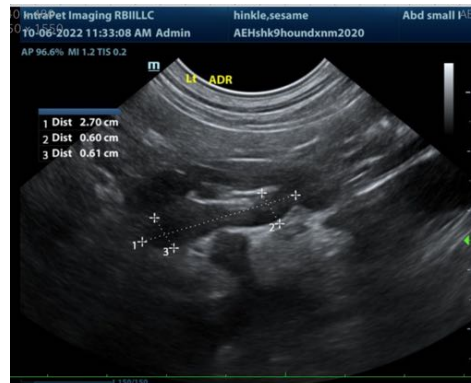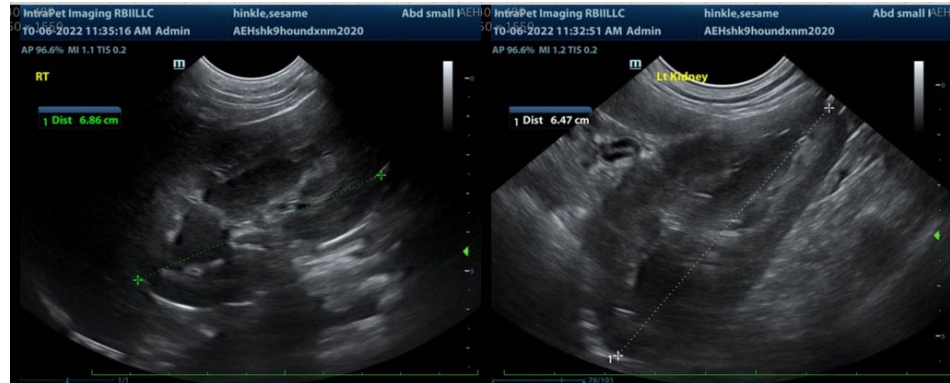
### **Primary Findings**

Possible, mildly thick gastric wall with the likely cause being a normal anatomic variant and prominent rugal folds, etc. However, inflammatory disease and/or infiltrative process cannot be definitely ruled out. Otherwise, this is an unremarkable/normal abdomen.

## **INTERPRETATION OF THE FINDINGS & FURTHER RECOMMENDATIONS**

Recommendations include managing the reported ear drum rupture and potentially nausea secondary or related to that. If clinical signs persist reevaluation of the stomach is recommended at which time if thickening is still present and/or confirmed additional recommendations/sampling can be discussed.





The information and recommendations provided are based on the images presented by the referring veterinarian. No evaluation can be communicated regarding pathology that was not visible in the image/video clips provided.

Thank you for this referral. If the clinical or image interpretation does not parallel your findings or if I can be of any further assistance please contact me.

**Beth Johnson, DVM DACVIM**  
Beth.Johnson@SonoPath.com