IMAGING PERFORMED BY

svsimaging.net 309-737-3070

SVS IMAGING

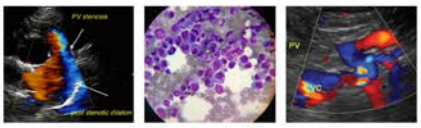

SonoPath

Clinical Sonography & Telecytology

EDUCATIONAL TELECONSULTATION SERVICES™

1-800-838-4268 info@sonopath.com SonoPath.com

PATIENT

Miss Kitty Boos

SPECIES

Feline

BREED

DSH

SEX

Intact Female

AGE

10 Years

WEIGHT

7.1 Pounds

INTERPRETED BY

Beth Johnson, DVM DACVIM

IMAGING PERFORMED BY

Sarah Pender, CVT

HOSPITAL NAME

SVS Imaging QC

REFERRING VET

Dr. Haenni

INVOICE

41848

DATE

10/5/22

PRESENTING CLINICAL SIGNS

discharge coming from vaginal area
Abnormal PE/Chem/CBC/UA Results: Mass seen on xray by the bladder UA: USG > 1.050, pH 6.7, clear, yellow, prot +++, RBC 13/field, WBC <1/field, few struvite, few Calcium Oxalate, no bacteria

ULTRASONOGRAPHIC EXAMINATION OF THE ABDOMEN

Urinary System

Urinary bladder is adequately distended. It has a normal uniform wall thickness. Contents include primarily anechoic fluid with occasional echogenic non-shadowing debris, most consistent with incidental suspended lipid in a cat, possibly combined with exfoliated cells, mucous and/or small blood clots. Both sterile inflammation as well as urinary tract infection can also present with echogenic debris. No masses or cystoliths are observed. The trigone and visible pelvic urethra are normal in thickness with a smooth mucosal surface.

The right kidney is normal in size (4.39 cm), shape and echogenicity. It has smooth peripheral margination. There is a normal 1:3 cortex to medulla ratio with appropriate corticomedullary distinction. There is no evidence of pyelectasia, mineral or infarcts observed.

The left kidney is normal in size (4.82 cm), shape and echogenicity. It has smooth peripheral margination. There is a normal 1:3 cortex to medulla ratio with appropriate corticomedullary distinction. There is no evidence of pyelectasia, mineral or infarcts observed.

Adrenal Glands

The right adrenal gland is normal in size (0.98 cm long x 0.47 cm at the cranial pole and 0.36 cm at the caudal pole), shape and contour. Corticomedullary structure is unremarkable. Visible surrounding vasculature appears normal.

The left adrenal gland is normal in size (0.95 cm long x 0.37 cm at the cranial pole and 0.36 cm at the caudal pole), shape and contour. Corticomedullary structure is unremarkable. Visible surrounding vasculature appears normal.

Spleen

The spleen is subjectively normal in size with a normal smooth capsular contour. Parenchyma is appropriately finely textured and homogenous with normal echogenicity relative to surrounding tissue (hyperechoic to liver). No focal nodules or masses are observed. Splenic vasculature appears normal.

Liver

The liver is subjectively normal in size with normal smooth curvilinear peripheral contour. Parenchyma is appropriately hypoechoic to the spleen in echogenicity and appropriately mildly coarse and homogenous in echotexture. No focal lesions are observed. Visible vasculature and biliary tree appear normal without distension or congestion.

The gallbladder is non-distended in size. The wall is smooth without visible thickening. Luminal contents are primarily anechoic. There is no evidence of cystic or common bile duct dilation.

Gastrointestinal

The stomach wall is normal in thickness (canine < 0.5 cm and feline < 0.4 cm) and layering. The lumen of the stomach is empty with no evidence of obstruction, foreign material or infiltrative disease. Pyloric outflow tract appears patent.

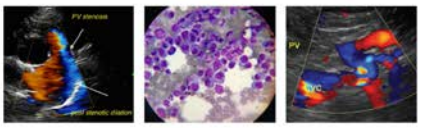

PATIENT

Miss Kitty Boos

SPECIES

Feline

BREED

DSH

SEX

Intact Female

AGE

10 Years

WEIGHT

7.1 Pounds

INTERPRETED BY

Beth Johnson, DVM
DACVIM

IMAGING PERFORMED BY

Sarah Pender, CVT

HOSPITAL NAME

SVS Imaging QC

REFERRING VET

Dr. Haenni

INVOICE

41848

DATE

10/5/22

The visible small intestines are normal in wall thickness and layering (canine duodenum < 0.5 cm and feline duodenum < 0.4 cm; other < 0.3 cm). Small intestinal motility appears adequate (1-3 contractions per min). The lumen of the small intestine is empty with no evidence of obstruction, foreign material or infiltrative disease.

The visible colon is normal in wall thickness (< 0.2 cm) and layering. Contents are consistent with normal formed feces and gas.

Pancreas

The pancreatic parenchyma is appropriately isoechoic to surrounding tissue. Visible capsule is smooth and normal in contour. There is no visible pancreatic duct dilation. There is no evidence of active peripancreatic inflammation.

Free Abdomen

The uterus is visible with a mildly thick, irregular, hyperechoic lining that appears to be attached to a 2.5 cm x 4.0 cm homogeneous, hypoechoic mass just dorsal to the urinary bladder trigone.

There is no evidence of free peritoneal effusion noted in these images.

There is no apparent lymphadenopathy noted in these images.

ULTRASONOGRAPHIC FINDINGS

- Caudal abdominal mass – believed to be uterine in origin. If so, differentials include both benign tumor such as adenoma or leiomyoma as well as malignant tumor such as adenocarcinoma or leiomyosarcoma.
- Urinary bladder debris

INTERPRETATION OF THE FINDINGS & FURTHER RECOMMENDATIONS

A fine needle aspirate of the caudal abdominal/uterine mass could be considered if patient's coagulation status is appropriate. However, a cytologic diagnosis likely won't change the recommended treatment, which is an ovariohysterectomy, so an alternative approach would be to proceed directly to spay.

If not recently evaluated, urinalysis and, if indicated based on urinalysis results, urine culture are recommended. If protein is present in an otherwise quiet sediment, protein quantification with a urine protein to creatinine ration is recommended.

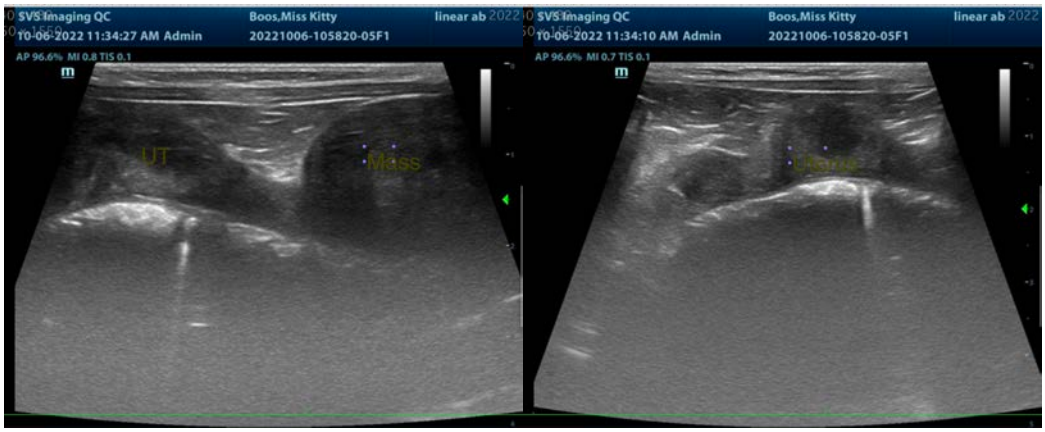

IMAGING PERFORMED BY

svsimaging.net 309-737-3070

SVS IMAGING

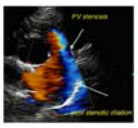

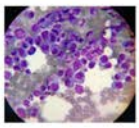

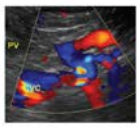

SonoPath

Clinical Sonography & Telecytology

EDUCATIONAL TELECONSULTATION SERVICES™

1-800-838-4268 info@sonopath.com SonoPath.com

PATIENT

Miss Kitty Boos

SPECIES

Feline

BREED

DSH

SEX

Intact Female

AGE

10 Years

WEIGHT

7.1 Pounds

INTERPRETED BY

Beth Johnson, DVM
DACVIM

IMAGING PERFORMED BY

Sarah Pender, CVT

HOSPITAL NAME

SVS Imaging QC

REFERRING VET

Dr. Haenni

INVOICE

41848

DATE

10/5/22

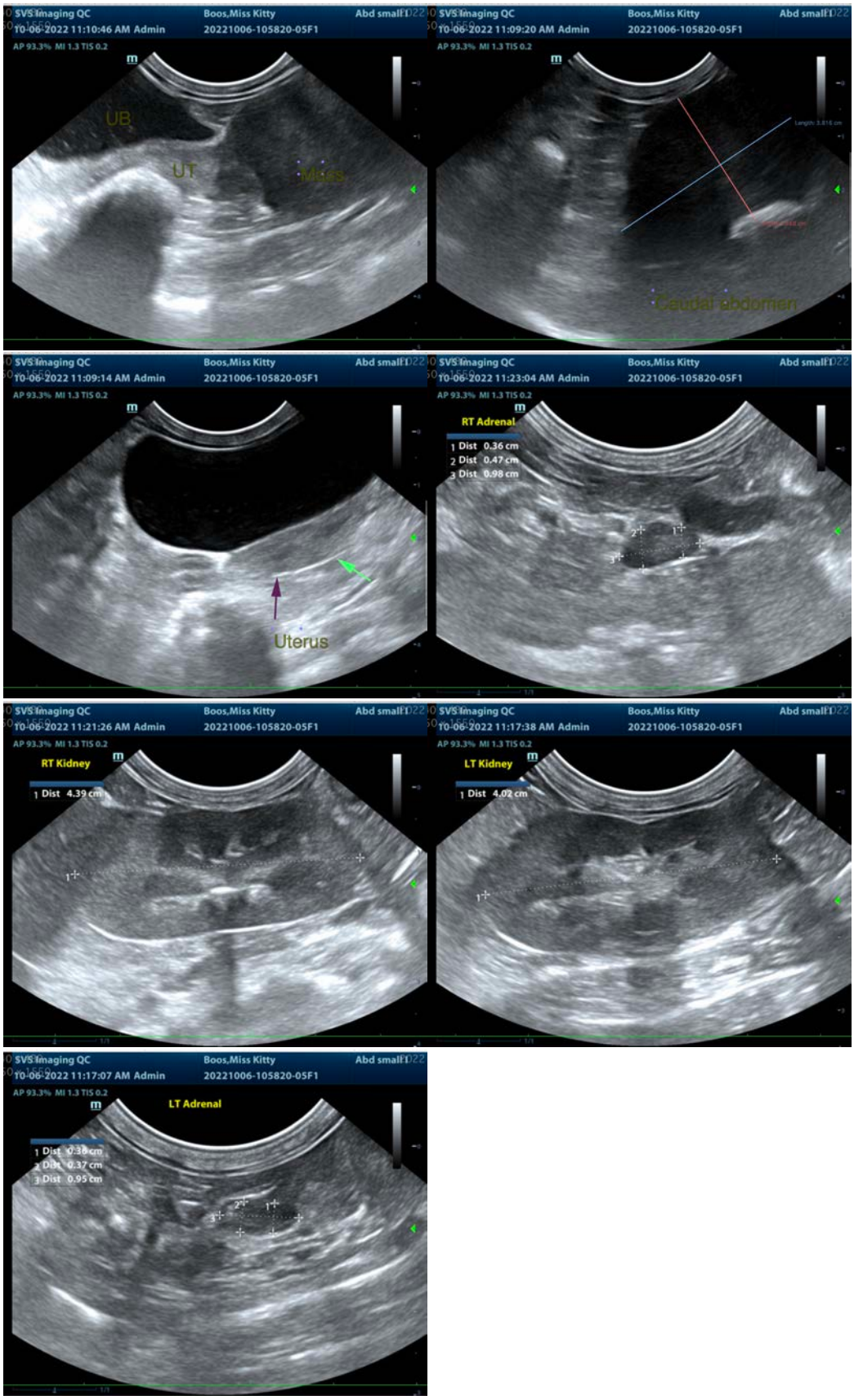

IMAGING PERFORMED BY

svsimaging.net 309-737-3070

SVS IMAGING

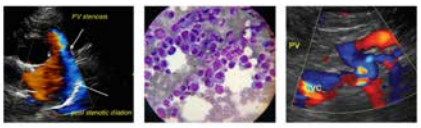

SonoPath

Clinical Sonography & Telecytology

EDUCATIONAL TELECONSULTATION SERVICES™

1-800-838-4268 info@sonopath.com SonoPath.com

PATIENT

Miss Kitty Boos

SPECIES

Feline

BREED

DSH

SEX

Intact Female

AGE

10 Years

WEIGHT

7.1 Pounds

INTERPRETED BY

Beth Johnson, DVM
DACVIM

IMAGING PERFORMED BY

Sarah Pender, CVT

HOSPITAL NAME

SVS Imaging QC

REFERRING VET

Dr. Haenni

INVOICE

41848

DATE

10/5/22

The information and recommendations provided are based on the images presented by the referring veterinarian/sonographer. No evaluation can be communicated regarding pathology that was not visible in the image/video clips provided.

Thank you for this referral. If the clinical or image interpretation does not parallel your findings or if I can be of any further assistance please contact me.

Beth Johnson, DVM, DACVIM
Beth.Johnson@sonopath.com