

**DATE**

10/31/22

**PRESENTING CLINICAL SIGNS**

Patient presented with consistent elevated Lipase and ALT and ALP.

Current Medications: None.

Lab Results: See attached.

**PATIENT**

Luke Hatch

Date of Previous IntraPet Ultrasound: No previous.

Sedation: Not required to complete full diagnostic ultrasound.

Stat Report: Not requested.

Imaging Performed By: Stephanie Warga RDCS, RVT.

**SPECIES**

Canine

**ULTRASONOGRAPHIC EXAMINATION OF THE ABDOMEN****Urinary System**

Urinary bladder is adequately distended with anechoic contents. No masses, inflammatory changes, echogenic sediment or cystoliths are observed. The urinary bladder, trigone and visible pelvic urethra are normal in thickness with a smooth mucosal surface.

**BREED**Staffordshire Terrier  
Mix

The area of the prostate is examined without evident pathology.

**SEX**

Neutered male

Left kidney is normal is size (6.08 cm), shape and echogenicity. It has smooth peripheral margination. There is a normal 1:3 cortex to medulla ratio with appropriate corticomedullary distinction. There is no evidence of pyelectasia, mineral or infarcts observed.

**AGE**

5/22/11

Right kidney is normal is size (6.14 cm), shape and echogenicity. It has smooth peripheral margination. There is a normal 1:3 cortex to medulla ratio with appropriate corticomedullary distinction. There is no evidence of pyelectasia, mineral or infarcts observed.

**WEIGHT**

65 lbs

**Adrenal Glands**

Adrenal glands are plump/swollen in size. Normal shape and contour are maintained without evidence of capsular invasion. Corticomedullary structure is unremarkable. Visible surrounding vasculature appears normal. The left adrenal gland measured 3.0 cm long, 0.46 cm at cranial pole and 1.0 cm at caudal pole. The right adrenal measured 2.7 cm long, 0.86 cm at cranial pole and 0.74 cm at caudal pole.

**INTERPRETED BY**Beth Johnson, DVM  
DACVIM**HOSPITAL NAME**Lake Shore Pet  
Hospital**Spleen**

Spleen is subjectively normal in size with a normal smooth capsular contour. Parenchyma is appropriately finely textured and homogenous with normal echogenicity relative to surrounding tissue (hyperechoic to liver). No focal nodules or masses are observed. Splenic vasculature appears normal.

**REFERRING VET**

Dr. Ashley

**Liver**

Liver is subjectively enlarged with mildly irregular margins. Parenchyma is heterogenous characterized by multiple poorly defined hypoechoic nodules within otherwise hyperechoic liver parenchyma. Visible vasculature and biliary tree appear normal without distension or congestion.

**INVOICE**

42226

Gallbladder is moderately distended with anechoic bile as well as suspended and gravity dependent echogenic debris. The wall is smooth without visible thickening. There is no evidence of cystic or CBD dilation. There is no evidence of effusion or inflammation.

### ***Gastrointestinal***

The visible stomach wall is normal in thickness and layering. The lumen of the stomach is mildly distended with echogenic non-shadowing luminal contents and gas consistent with normal ingesta. There is no evidence of obstruction, foreign material or infiltrative disease. Pyloric outflow tract appears patent.

The visible small intestines are normal in wall thickness and layering. Small intestinal motility appears adequate (1-3 contractions per min). The lumen of the small intestine is empty with no evidence of obstruction, foreign material or infiltrative disease.

The visible colon is normal in wall thickness (< 0.2 cm) and layering. Contents are consistent with normal formed feces and gas.

### ***Pancreas***

The observed pancreas appears appropriately isoechoic to surrounding omental fat. Visible capsule is smooth and normal in contour. Visible pancreatic parenchyma is homogenous and unremarkable. There is no visible pancreatic duct dilation. There is no evidence of active peripancreatic inflammation.

### ***Free Abdomen***

There is no evidence of free peritoneal effusion noted in these images.

There is no apparent lymphadenopathy noted in these images.

Caudal to the stomach there is a 1.5 cm, round, fluid filled, cystic structure that appears to be associated with the pancreas.

## **ULTRASONOGRAPHIC FINDINGS**

### **Primary Findings**

- **Bilateral adrenomegaly** – consistent with adrenal hyperplasia secondary to pituitary dependent hyperadrenocorticism vs stress or normal variant. Interpret in combination with clinical signs of hyperadrenocorticism.
- **Cystic structure caudal to the stomach** that appears to be a likely benign incidental pancreatic cyst potentially indicative of chronic pancreatitis.

### **Secondary Findings**

- **Gallbladder debris (canine)** - Cholecystic debris is of unknown clinical significance. It can be seen with biliary stasis from fasting or illness. Cholecystic debris is not necessarily related to hepatobiliary disease. Echogenic bile is most commonly an incidental finding in dogs and should be interpreted in combination with clinical signs such as nausea, inappetence, cranial abdominal discomfort and/or laboratory changes such as increased ALP and/or increased Tbili.
- **Heterogenous Liver** – These changes are most consistent with benign processes such as nodular hyperplasia, steroid (vacuolar) hepatopathy, extramedullary hematopoiesis or possibly chronic inflammatory disease and less commonly infiltrative round cell or metastatic neoplasia.

## **INTERPRETATION OF THE FINDINGS & FURTHER RECOMMENDATIONS**

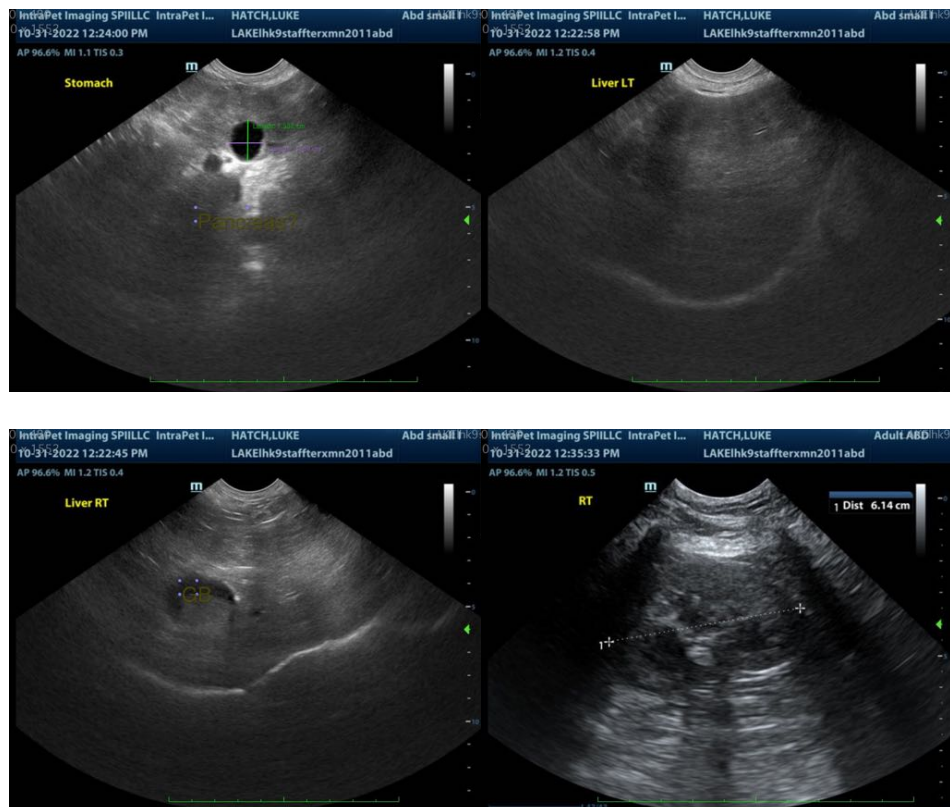
1. A gastrointestinal malabsorption panel (including cobalamin, folate, TLI and PLI) to Texas A&M GI Laboratory is recommended for further evaluation of GI and pancreatic function.
2. The described adrenal gland, liver and gallbladder changes are all suggestive of hyperadrenocorticism. If clinical signs of hyperadrenocorticism, such as polyuria, polydipsia,

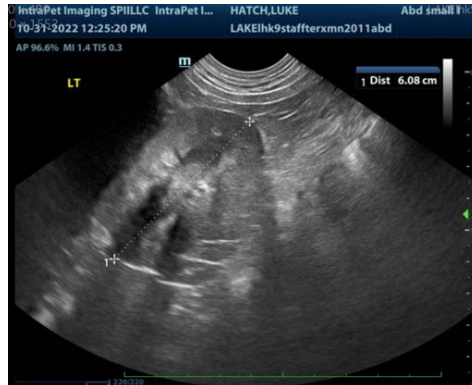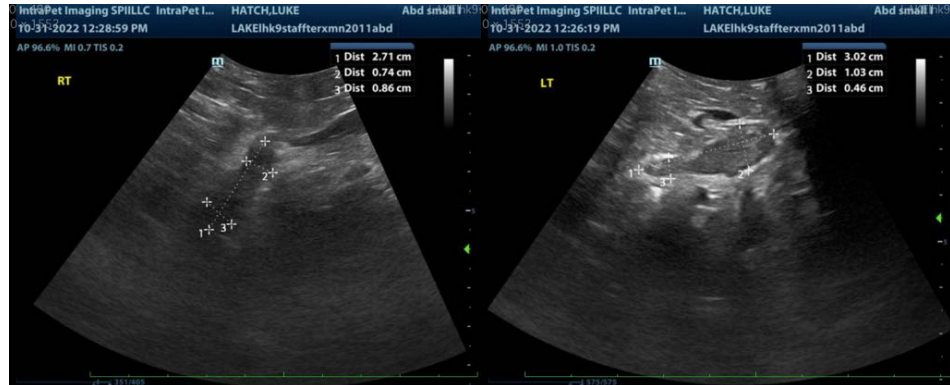polyphagia, panting, hair loss, hypertension, etc. are present, testing for hyperadrenocorticism with a LDDS test is warranted.

If clinical signs are not present, monitoring is recommended with testing pursued when/if clinical signs develop.

If not recently evaluated, blood pressure is recommended.

If not recently evaluated, a urinalysis and, if indicated based on urinalysis results, urine culture are also recommended. If protein is present in an otherwise quiet sediment, protein quantification with a urine protein to creatinine ratio is recommended.





The information and recommendations provided are based on the images presented by the referring veterinarian. No evaluation can be communicated regarding pathology that was not visible in the image/video clips provided.

Thank you for this referral. If the clinical or image interpretation does not parallel your findings or if I can be of any further assistance please contact me.

**Beth Johnson, DVM DACVIM**  
Beth.Johnson@SonoPath.com