



DATE
10/31/22

PRESENTING CLINICAL SIGNS

History: Presented for wellness and check lump. Aspirated showed plasma cell tumor and surgery is advised. Pet has a chronic history of mild ALT elevations. On chronic Carprofen.

PATIENT

Burpee Hatfield

SPECIES

Canine

BREED

Pitbull Mix

SEX

Neutered Male

AGE

1/8/13

WEIGHT

75 Pounds

INTERPRETED BY

Beth Johnson, DVM
DACVIM

HOSPITAL NAME

Everhart VH

REFERRING VET

Dr. Notarangelo

INVOICE

17913

Current Medications: Carprofen 75mg BID for >12 months.
 Lab Results: 10/13/22- ALT 274. 6/14/22 ALT 325, PSL 443.
 Date of Previous IntraPet Ultrasound: No previous.
 Sedation: Not required to complete full diagnostic ultrasound.
 Stat Report: Not requested.
 Imaging Performed By: Stephanie Warga RDCS, RVT.

ULTRASONOGRAPHIC EXAMINATION OF THE ABDOMEN

Urinary System

Urinary bladder is adequately distended with anechoic contents. No masses, inflammatory changes, echogenic sediment or cystoliths are observed. The urinary bladder, trigone and visible pelvic urethra are normal in thickness with a smooth mucosal surface.

Prostate is normal in size, echotexture and echogenicity for a neutered male.

Left kidney is normal is size (7.29 cm), shape and echogenicity. It has smooth peripheral margination. There is a normal 1:3 cortex to medulla ratio with appropriate corticomedullary distinction. There is no evidence of pyelectasia, mineral or infarcts observed.

Right kidney is normal is size (7.46 cm), shape and echogenicity. It has smooth peripheral margination. There is a normal 1:3 cortex to medulla ratio with appropriate corticomedullary distinction. There is no evidence of pyelectasia, mineral or infarcts observed.

Adrenal Glands

Left adrenal gland is normal in size (3.48 cm long x 0.8 cm at cranial pole and 0.86 cm at caudal pole), shape and overall architecture, echogenicity and echotexture. Visible surrounding vasculature appears normal.

Right adrenal gland is normal in size (3.55 cm long x 0.93 cm at cranial pole and 0.91 cm at caudal pole), shape and overall architecture, echogenicity and echotexture. Visible surrounding vasculature appears normal.

Spleen

Spleen is subjectively normal in size with a normal smooth capsular contour. Parenchyma is appropriately finely textured and homogenous with normal echogenicity relative to surrounding tissue (hyperechoic to liver). No focal nodules or masses are observed. Splenic vasculature appears normal.

Liver

Liver is subjectively normal in size with normal smooth curvilinear peripheral contour. Parenchyma is appropriately hypoechoic to the spleen in echogenicity and appropriately mildly coarse and homogenous in echotexture. No focal lesions are observed. Visible vasculature and biliary tree appear normal without distension or congestion.

Gallbladder is moderately distended with anechoic bile as well as suspended and gravity dependent echogenic debris. The wall is smooth without visible thickening. There is no evidence of cystic or CBD dilation. There is no evidence of effusion or inflammation.

Gastrointestinal

The visible stomach wall is normal in thickness and layering. The lumen of the stomach is empty with no evidence of obstruction, foreign material or infiltrative disease. Pyloric outflow tract appears patent.

The visible small intestines are normal in wall thickness and layering. Small intestinal motility appears adequate (1-3 contractions per min). The lumen of the small intestine is empty with no evidence of obstruction, foreign material or infiltrative disease.

The visible colon is normal in wall thickness and layering. Contents are consistent with normal formed feces and gas.

Pancreas

The observed pancreas appears appropriately isoechoic to surrounding omental fat. Visible capsule is smooth and normal in contour. Visible pancreatic parenchyma is homogenous and unremarkable. There is no visible pancreatic duct dilation. There is no evidence of active peripancreatic inflammation.

Free Abdomen

There is no evidence of peritoneal effusion. There is no apparent lymphadenopathy.

ULTRASONOGRAPHIC FINDINGS

Primary Findings

- Unremarkable/normal abdomen

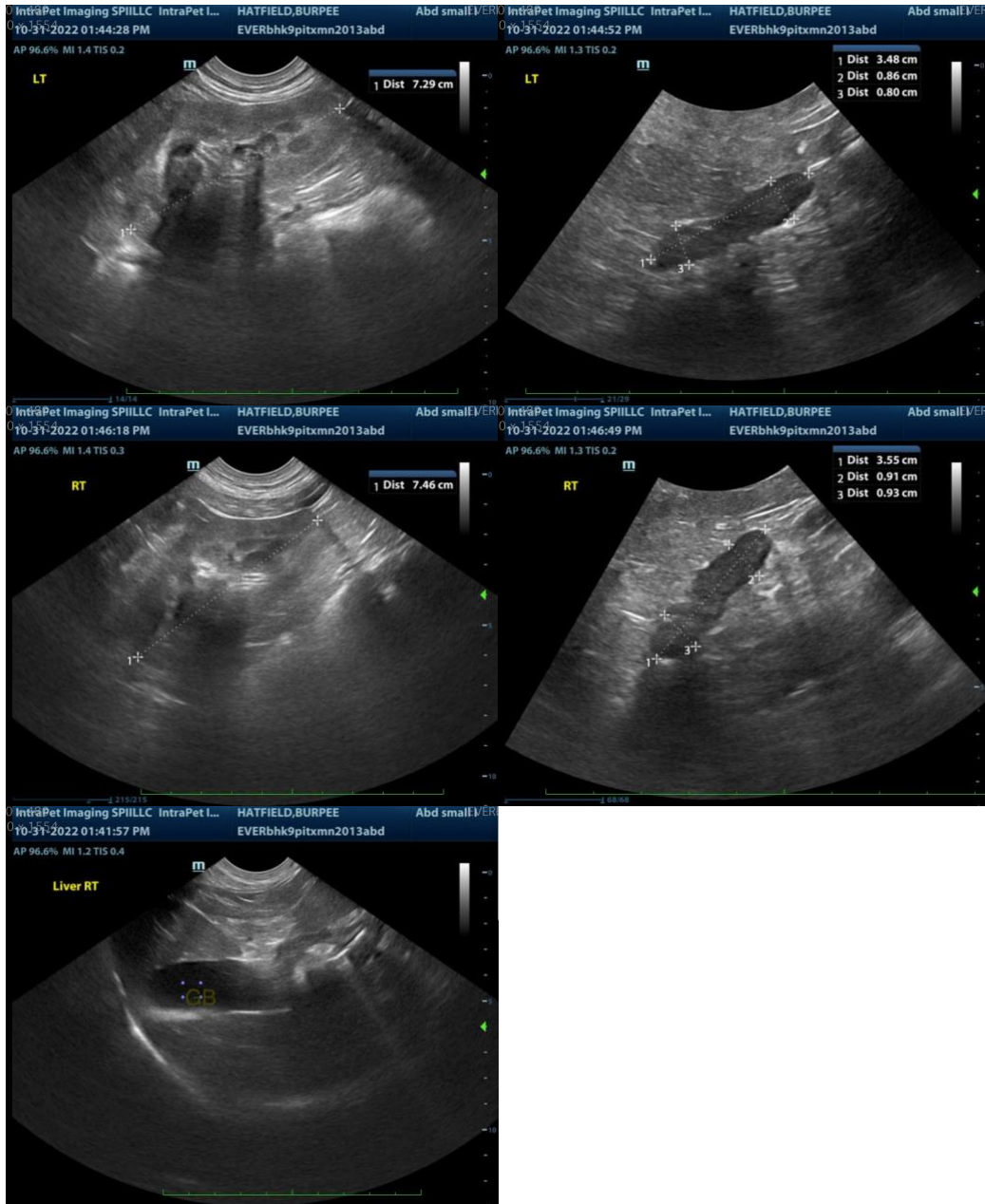
Secondary Findings

- Gallbladder debris - Cholecystic debris is of unknown clinical significance. It can be seen with biliary stasis from fasting or illness. Cholecystic debris is not necessarily related to hepatobiliary disease. Echogenic bile is most commonly an incidental finding in dogs and should be interpreted in combination with clinical signs such as nausea, inappetence, cranial abdominal discomfort and/or laboratory changes such as increased ALP and/or increased Tbili.

INTERPRETATION OF THE FINDINGS & FURTHER RECOMMENDATIONS

Three view thoracic radiographs are recommended for further assessment of cardio-pulmonary status as well as to further evaluate for any evidence of metastatic disease, if not recently evaluated.

Proceed with surgery for mass removal, as reportedly planned.



The information and recommendations provided are based on the images presented by the referring veterinarian. No evaluation can be communicated regarding pathology that was not visible in the image/video clips provided.

Thank you for this referral. If the clinical or image interpretation does not parallel your findings or if I can be of any further assistance please contact me.

Beth Johnson, DVM DACVIM

Beth.Johnson@SonoPath.com