

**DATE**

10/3/22

PRESENTING CLINICAL SIGNS**PATIENT**

George Kraska

History: History of increased ALP/ALT liver values since August 2022. No response to denamarin and course of clavamox which was originally prescribed to treat a UTI. Have increased at recent recheck. Has a suspected mast cell tumor on lateral abdomen (we have to sedate P to aspirate, so has not been confirmed yet). history of severe arthritis, otherwise no significant findings on exam, but P is difficult to examine. No Pu/pd at home. On gabapentin, adequan, and dasuquin for arthritis.

SPECIES

Canine

Current Medications: Denamarin advanced trial – completed, Gabapentin 300mg PO SID at night for pain, Adequan - now on monthly dose 2mL IM, Dasquin advanced daily 1 sid

BREED

Pitbull Mix

Date of Previous IntraPet Ultrasound: No previous.

Sedation: Butorphanol 0.2mg/kg IV, Midazolam 0.15mg/kg IV, and Ketamine 0.5mg/kg IV.

Stat Report: Not requested.

Imaging Performed By: Rachel Brillhart, RDMS.

SEX

Neutered Male

ULTRASONOGRAPHIC EXAMINATION OF THE ABDOMEN**AGE**

2/14/10

Urinary System

Urinary bladder is adequately distended with anechoic contents. No masses, inflammatory changes, echogenic sediment or cystoliths are observed. The urinary bladder, trigone and visible pelvic urethra are normal in thickness with a smooth mucosal surface.

WEIGHT

80 Pounds

Prostate is normal in size, echotexture and echogenicity for a neutered male.

Left kidney is normal is size (6.39 cm), shape and echogenicity. It has smooth peripheral margination. There is a normal 1:3 cortex to medulla ratio with appropriate corticomedullary distinction. There is no evidence of pyelectasia, or infarcts observed. Non-obstructive linear multifocal hyperechoic diverticular foci with acoustic shadowing are noted.

INTERPRETED BYBeth Johnson, DVM
DACVIM

Right kidney is normal is size (7.15 cm), shape and echogenicity. It has smooth peripheral margination. There is a normal 1:3 cortex to medulla ratio with appropriate corticomedullary distinction. There is no evidence of pyelectasia, or infarcts observed. Non-obstructive linear multifocal hyperechoic diverticular foci with acoustic shadowing are noted.

HOSPITAL NAME

Heart + Paw

Adrenal Glands

Left adrenal gland is normal in size (3.4 cm long x 0.8 cm at cranial pole and 0.9 cm at caudal pole), shape and overall architecture, echogenicity and echotexture. Visible surrounding vasculature appears normal.

REFERRING VET

Dr. Kraselski

Right adrenal gland is normal in size (3.46 cm long x 0.82 cm at cranial pole and 0.87 cm at caudal pole), shape and overall architecture, echogenicity and echotexture. Visible surrounding vasculature appears normal.

INVOICE

17581

Spleen

Spleen is subjectively large in size with a swollen and scalloped/undulating capsular contour. Multifocal coalescing nodules are noted throughout the parenchyma. Splenic vasculature appears normal. Enhanced hyperechoic surrounding fat is noted.

Liver

Liver is subjectively enlarged with mildly irregular margins. Parenchyma is heterogenous characterized by multiple poorly defined hypoechoic nodules within otherwise hyperechoic liver parenchyma. Visible vasculature and biliary tree appear normal without distension or congestion.

Gallbladder is non-distended in size. The wall is smooth without visible thickening. Luminal contents are primarily anechoic. There is no evidence of cystic or common bile duct dilation.

Gastrointestinal

The visible stomach wall is normal in thickness and layering. The lumen of the stomach is empty with no evidence of obstruction, foreign material or infiltrative disease. Pyloric outflow tract appears patent.

The visible small intestines are normal in wall thickness and layering. Small intestinal motility appears adequate (1-3 contractions per min). The lumen of the small intestine is empty with no evidence of obstruction, foreign material or infiltrative disease.

The visible colon is normal in wall thickness and layering. Contents are consistent with normal formed feces and gas.

Pancreas

The observed pancreas appears appropriately isoechoic to surrounding omental fat. Visible capsule is smooth and normal in contour. Visible pancreatic parenchyma is homogenous and unremarkable. There is no visible pancreatic duct dilation. There is no evidence of active peripancreatic inflammation.

Free Abdomen

There is no evidence of free fluid. Mild sublumbar lymphadenopathy is noted.

ULTRASONOGRAPHIC FINDINGS

Primary Findings

- Honeycomb Spleen – This finding is strongly suggestive of infiltrative disease such as round cell neoplasia. Benign disease cannot be ruled out but is considered less likely.
- Heterogenous Liver – These changes are most consistent with benign processes such as nodular hyperplasia, steroid (vacuolar) hepatopathy, extramedullary hematopoiesis or possibly chronic inflammatory disease and less commonly infiltrative round cell or metastatic neoplasia.
- Sublumbar lymphadenopathy, rule outs for which include both reactive nodes, as well as infiltrative neoplasia, including mast cell tumor given this patients history.

Secondary Findings

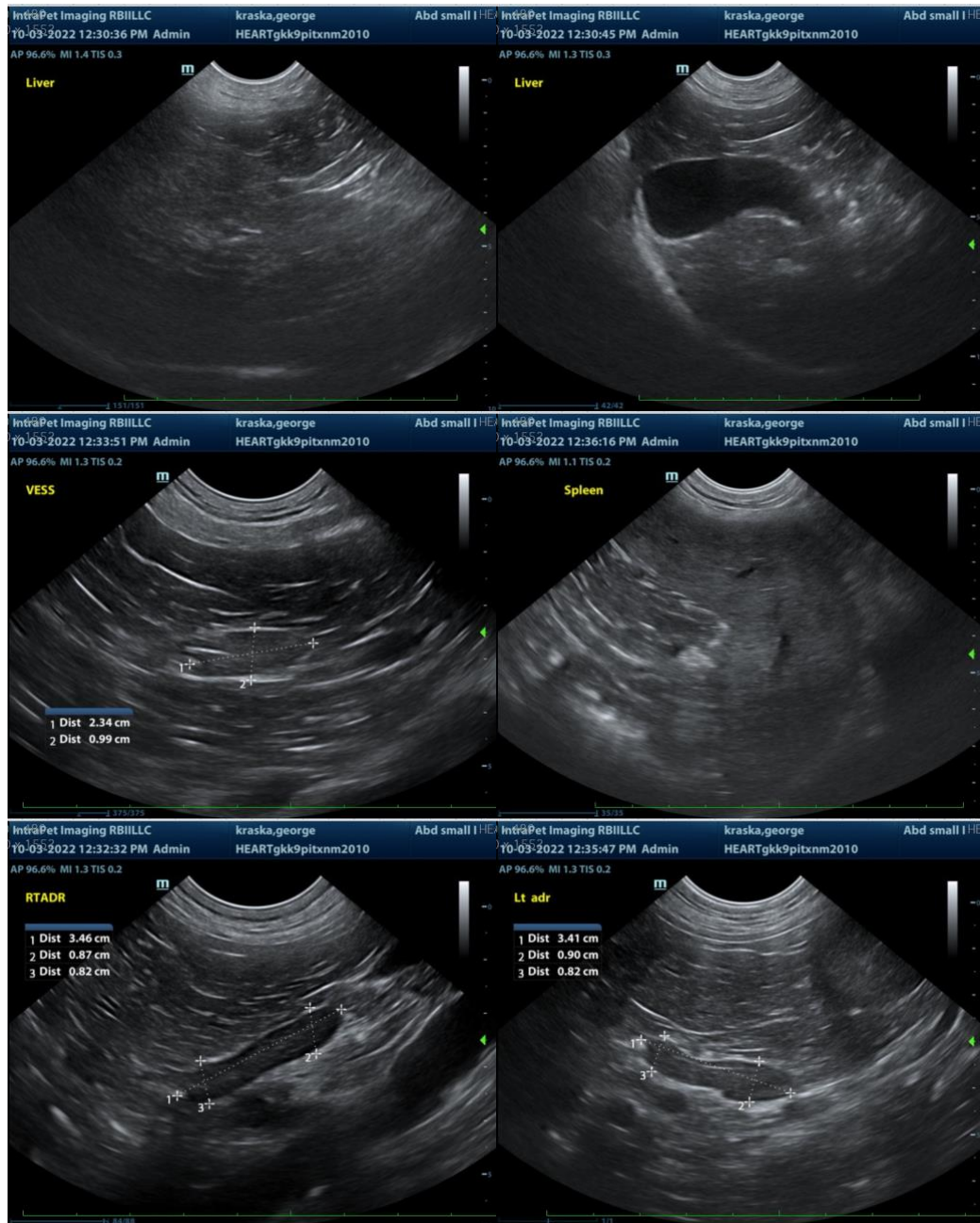
- Nonobstructive dystrophic mineralization bilaterally in the kidneys

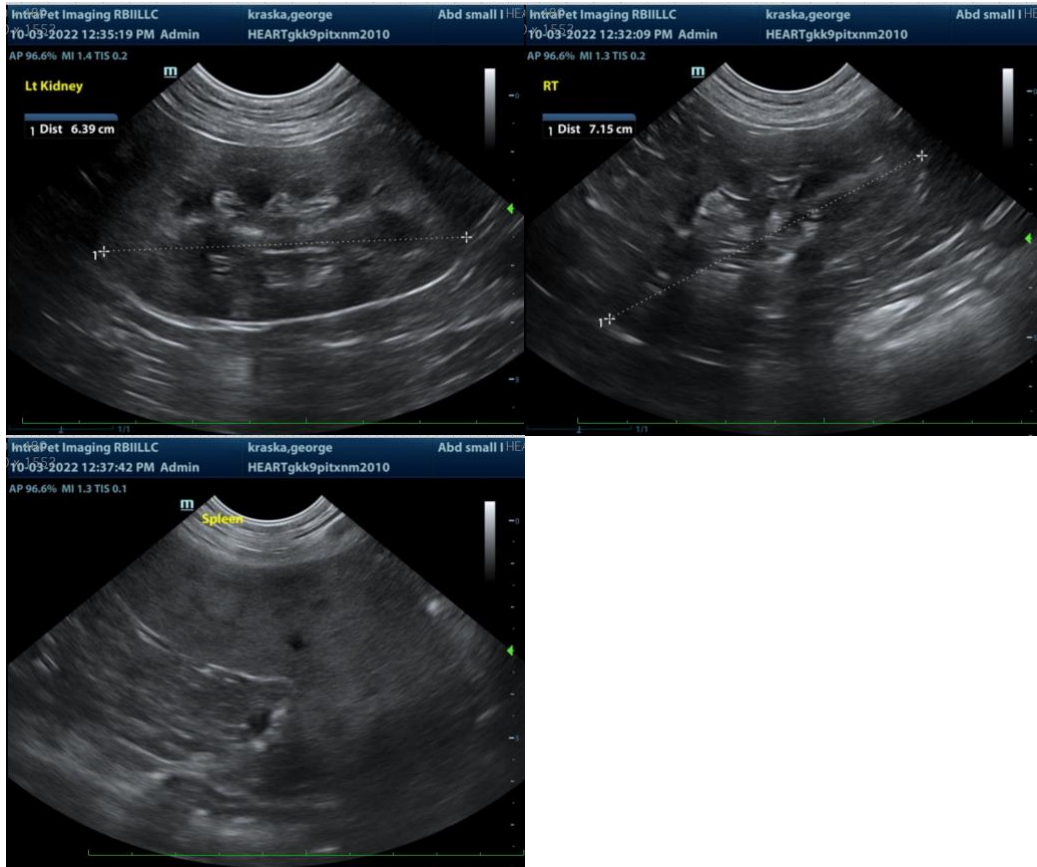
INTERPRETATION OF THE FINDINGS & FURTHER RECOMMENDATIONS

Recommendations for this patient, given the suspicion for possible mast cell tumor, include a fine needle aspirate of the spleen, as well as the liver if patients coagulation status is appropriate. Additionally, fine needle aspirate of the sublumbar lymph node could be considered if it can safely be reached.

Premedication with Diphenhydramine is recommended prior to aspirating.

Beyond testing for mast cell tumor, recommendations for this patients reportedly increased liver enzymes are dependent on whether the pattern is primarily cholestatic versus hepatocellular injury in origin. If primarily hepatocellular in origin, testing for Leptospirosis could be considered.





The information and recommendations provided are based on the images presented by the referring veterinarian. No evaluation can be communicated regarding pathology that was not visible in the image/video clips provided.

Thank you for this referral. If the clinical or image interpretation does not parallel your findings or if I can be of any further assistance please contact me.

Beth Johnson, DVM DACVIM
Beth.Johnson@SonoPath.com