



**PATIENT**

Bentley Swenski

**SPECIES**

Canine

**BREED**

Pug

**SEX**

Castrated Male

**AGE**

14 Years

**WEIGHT**

12.7 kg

**INTERPRETED BY**

Beth Johnson, DVM  
DACVIM

**IMAGING PERFORMED BY**

Dr. Laura de Cordon

**HOSPITAL NAME**

Mason Dixon Animal  
Emergency Hospital

**REFERRING VET**

Dr. Laura de Cordon

**INVOICE**

42384

**DATE**

10/27/22

**PRESENTING CLINICAL SIGNS**

Vomiting intermittently for a couple days but tonight around 7pm. Had pt outside at 7am and 12 pm and vomited twice. Hx of ear infection pt was tilting head to the right and had head lowered  
Abnormal PE/Chem/CBC/UA Results: Chem 6 (initial BW) ALT 190, BUN 30, ALP >993, BG 496, Na 135 L, Cl 91L Chem Plus: BUN 32.8 H, Creat WNL, BG 535, Tchol >450, ALT 207, AST 111, ALP >993, GGT 15, lipase not reading, TG 164 Lytes: Na 136 L, Cl 93 L CBC: WBC 18.42, neuts 16.59 BG: 473 BP: 118 cPLI: Abnormal Serum ketones: 80 Urinalysis Cystocentesis: Sediment: WBC <1 / Field Bilirubin: Neg RBC <1 / Field Sq Epi: <1 / Field Crystal: Calcium Oxalate Dihydrate Few Non Sq Epithelial: <1 / Field Casts Fine Granular: 1 or more / Field Urobilinogen Normal Bacteria: Cocci Present Ketones ++ Appearance Slightly Hazy USG 1.028 Collection Method: Cystocentesis Color: Yellow PH 5 Protein ++ Glucose 1000 mg/dl Leukocytes Neg Blood + Radiographs 2 view AXR: Large number of small stones in urinary bladder. Liver or spleen enlarged with caudal displacement of intestines.

**ULTRASONOGRAPHIC EXAMINATION OF THE ABDOMEN**

**Urinary System**

Urinary bladder is adequately distended. It has a normal uniform wall thickness. Contents include primarily anechoic fluid with occasional echogenic non-shadowing debris, most consistent with exfoliated cells, mucous and/or small blood clots. Both sterile inflammation as well as urinary tract infection can also present with echogenic debris. Too numerous to count small cystoliths are present. No masses observed. The trigone and visible pelvic urethra are normal in thickness with a smooth mucosal surface.

The area of the prostate is examined without evident pathology.

The right kidney is normal in size (5.5 cm), shape and echogenicity. It has smooth peripheral margination. There is a normal 1:3 cortex to medulla ratio with appropriate corticomedullary distinction. There is no evidence of pyelectasia or infarcts observed. A hyperechoic band parallel to the corticomedullary border is present. Non-obstructive areas of mineralization/nephroliths are noted.

The left kidney is normal in size (5.0 cm), shape and echogenicity. It has smooth peripheral margination. There is a normal 1:3 cortex to medulla ratio with appropriate corticomedullary distinction. There is no evidence of pyelectasia or infarcts observed. A hyperechoic band parallel to the corticomedullary border is present. Non-obstructive areas of mineralization/nephroliths are noted.

**Adrenal Glands**

The right adrenal gland is unable to be well visualized in these images.

The left adrenal gland is normal in size (0.40 cm at the cranial pole and 0.44 cm at the caudal pole), shape and contour. Corticomedullary structure is unremarkable. Visible surrounding vasculature appears normal.

**Spleen**

The spleen is subjectively normal in size with a normal smooth capsular contour. Parenchyma is appropriately finely textured and homogenous with normal echogenicity relative to surrounding tissue (hyperechoic to liver). No focal nodules or masses are observed. Splenic vasculature appears normal.

**Liver**

Liver is subjectively enlarged (swollen contour) without disruption of architecture. It has a normal homogenous echotexture. Parenchyma is diffusely hyperechoic characterized by less prominent than normal portal vein walls and increased echogenicity relative to the spleen and falciform fat. No focal



**PATIENT**

Bentley Swenski

lesions are observed. Visible vasculature and biliary tree appear normal without distension or congestion.

The gallbladder is non-distended in size. The wall is smooth without visible thickening. Luminal contents are primarily anechoic. There is no evidence of cystic or common bile duct dilation.

**SPECIES**

Canine

**Gastrointestinal**

The stomach wall is normal in thickness (canine < 0.5 cm and feline < 0.4 cm) and layering. The stomach is markedly distended with primarily fluid and some echogenic contents, consistent with normal ingesta/chyme. There is no evidence of foreign material present in these images.

**BREED**

Pug

The visible small intestines are normal in wall thickness and layering (canine duodenum < 0.5 cm and feline duodenum < 0.4 cm; other < 0.3 cm). Small intestinal motility appears adequate (1-3 contractions per min). The lumen of the small intestine is empty with no evidence of obstruction, foreign material or infiltrative disease.

**SEX**

Castrated Male

The visible colon is normal in wall thickness (< 0.2 cm) and layering. Contents are consistent with normal formed feces and gas.

**AGE**

14 Years

**Pancreas**

The observed pancreas is prominent (enlarged) in size, hypoechoic to surrounding tissue and irregular in shape with a swollen undulating contour. Enhanced hyperechoic ill-defined surrounding fat is noted.

**WEIGHT**

12.7 kg

**Free Abdomen**

There is no evidence of free peritoneal effusion noted in these images.

There is no apparent lymphadenopathy noted in these images.

**INTERPRETED BY**

Beth Johnson, DVM  
DACVIM

**PRIMARY FINDINGS**

- Acute pancreatitis with suspected secondary gastric stasis/ileus
- **Hyperechoic hepatomegaly** - This appearance is non-specific and most consistent with a benign steroid (endocrine) or vacuolar hepatopathy or reactive or idiopathic hepatopathy. Inflammatory and/or infiltrative disease (such as round cell neoplasia) are also possible, but considered less likely.
- **Bilateral medullary rim sign** - This finding is of unknown clinical significance and can be a normal variant, often idiopathic. Medullary rim sign can be present with renal disease including FIP, lymphoma, hypercalcemic nephropathy, Leptospirosis, tubular disease, other and should be interpreted in combination with other more specific indications of kidney disease such as isosthenuria, proteinuria, azotemia, etc. This is a common incidental finding in patients with diabetes mellitus.

**IMAGING PERFORMED BY**

Dr. Laura de Cordon

**HOSPITAL NAME**

Mason Dixon Animal  
Emergency Hospital

**REFERRING VET**

Dr. Laura de Cordon

**SECONDARY FINDINGS**

- Urinary bladder debris with cystoliths
- Non-obstructive nephrolithiasis bilaterally in the kidneys

**INVOICE**

42384

**DATE**

10/27/22



**PATIENT**

Bentley Swenski

**SPECIES**

Canine

**BREED**

Pug

**SEX**

Castrated Male

**AGE**

14 Years

**WEIGHT**

12.7 kg

**INTERPRETED BY**

Beth Johnson, DVM  
DACVIM

**IMAGING PERFORMED BY**

Dr. Laura de Cordon

**HOSPITAL NAME**

Mason Dixon Animal  
Emergency Hospital

**REFERRING VET**

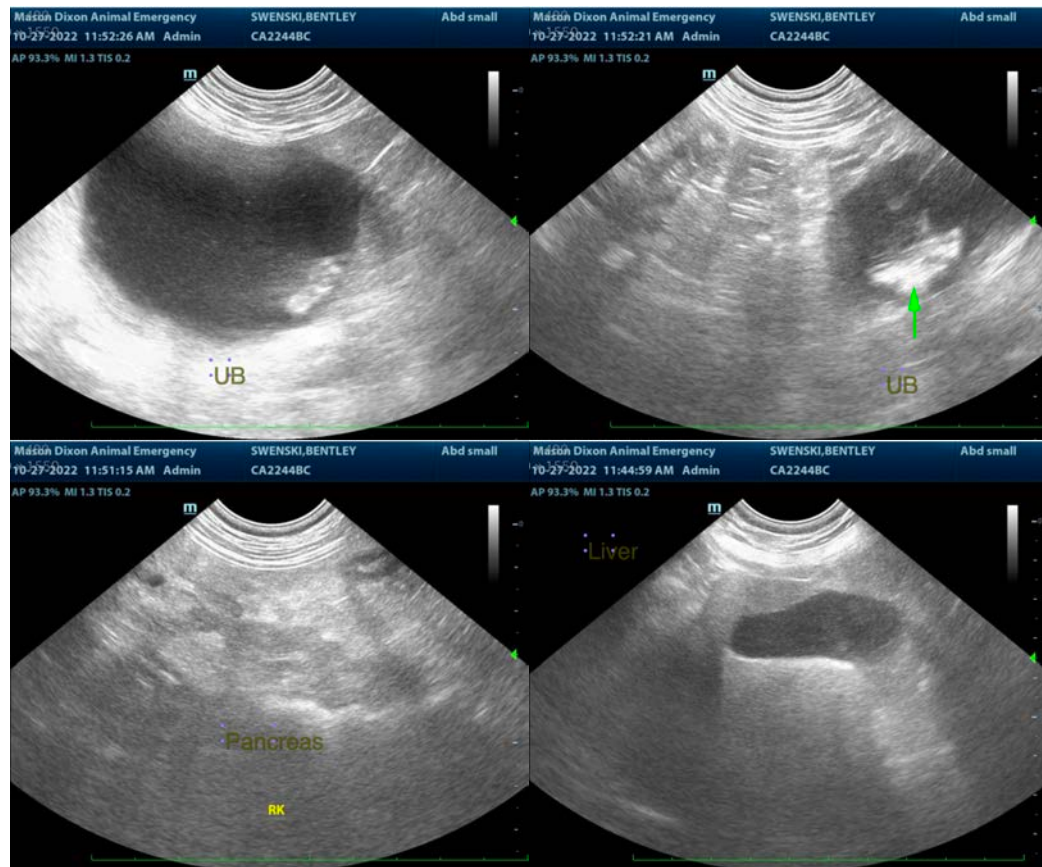
Dr. Laura de Cordon

**INTERPRETATION OF THE FINDINGS & FURTHER RECOMMENDATIONS**

This patient's clinical signs are likely due to a combination of acute pancreatitis, diabetic ketoacidosis, +/- current urinary tract infection. Recommendations include (not recently evaluated) a urine culture as well as a quantitative PLI.

In the meantime, medical management of pancreatitis with anti-emetics, gastroprotectants, appetite stimulants or nutritional support as needed, pain management, broad spectrum antibiotics, and fluid therapy is recommended. If possible, a fresh frozen plasma transfusion and hyperbaric oxygen therapy (HBOT) could be beneficial. Monitoring of the pancreas with power doppler is recommended to identify possible necrosis as well as other potential sequelae such as abscesses, etc.

In addition to therapy described above, short-acting insulin is recommended with close monitoring of blood glucoses and ketones, etc., until ketones have resolved and patient is reliably eating, at which time transition to a more normal longer-acting insulin for at-home use can be considered.



**INVOICE**

42384

**DATE**

10/27/22



**PATIENT**

Bentley Swenski

**SPECIES**

Canine

**BREED**

Pug

**SEX**

Castrated Male

**AGE**

14 Years

**WEIGHT**

12.7 kg

**INTERPRETED BY**

Beth Johnson, DVM  
DACVIM

**IMAGING PERFORMED BY**

Dr. Laura de Cordon

**HOSPITAL NAME**

Mason Dixon Animal  
Emergency Hospital

**REFERRING VET**

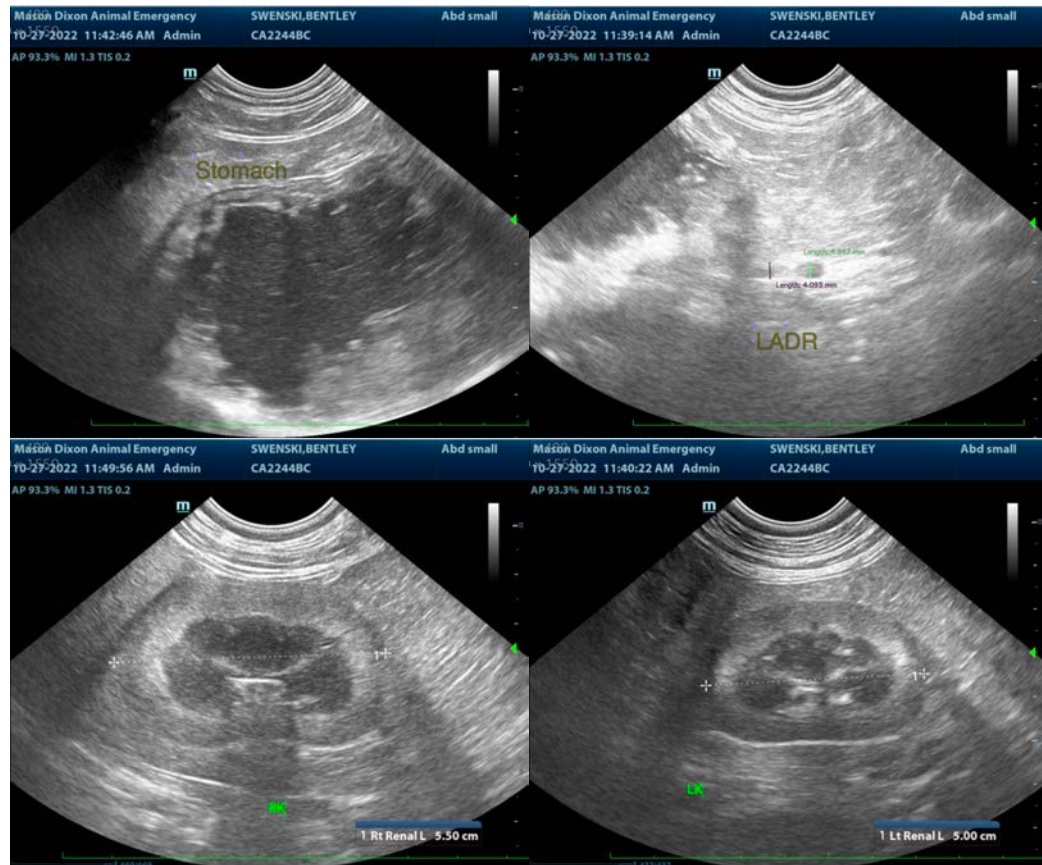
Dr. Laura de Cordon

**INVOICE**

42384

**DATE**

10/27/22



The information and recommendations provided are based on the images presented by the referring veterinarian/sonographer. No evaluation can be communicated regarding pathology that was not visible in the image/video clips provided.

Thank you for this referral. If the clinical or image interpretation does not parallel your findings or if I can be of any further assistance please contact me.

**Beth Johnson, DVM, DACVIM**  
Beth.Johnson@sonopath.com