



PATIENT

Tasha Dickinson/Walsh

SPECIES

Feline

BREED

DSH

SEX

Spayed Female

AGE

14 Years

WEIGHT

10 Pounds

INTERPRETED BY

Beth Johnson, DVM
DACVIM

IMAGING PERFORMED BY

Christina

HOSPITAL NAME

Animal Health VC

REFERRING VET

Dr. Rodriguez

INVOICE

42383

DATE

10/26/22

PRESENTING CLINICAL SIGNS

Presented 10/24/22 for not eating or drinking, lethargy, weakness and weight loss. Bloodwork sent out, SQ fluids and cerenia given. O began giving entyce that she had at home for another pet, ate very small amount. Bloodwork revealed HCT - 25%, T4 - 0.5, Amylase 1346, all other values normal. P brought in for US today, entire abdomen painful for scan. P was sedated with Torb IV.

ULTRASONOGRAPHIC EXAMINATION OF THE ABDOMEN

Urinary System

The urinary bladder is moderately distended with anechoic contents. No masses, inflammatory changes, echogenic sediment or cystoliths are observed. The urinary bladder, trigone and visible pelvic urethra are normal in thickness with a smooth mucosal surface.

The right kidney is normal in size (3.97 cm), shape and echogenicity. It has smooth peripheral margination. There is a normal 1:3 cortex to medulla ratio with appropriate corticomedullary distinction. There is no evidence of pyelectasia, mineral or infarcts observed.

The left kidney is normal in size (3.91 cm), shape and echogenicity. It has smooth peripheral margination. There is a normal 1:3 cortex to medulla ratio with appropriate corticomedullary distinction. There is no evidence of pyelectasia, mineral or infarcts observed.

Adrenal Glands

The right adrenal gland is unable to be visualized due to patient temperament/discomfort during the exam.

The left adrenal gland is normal in size (1.76 cm long x 0.32 cm at the cranial pole and 0.27 cm at the caudal pole), shape and contour. Corticomedullary structure is unremarkable. Visible surrounding vasculature appears normal.

Spleen

The spleen is subjectively normal in size with a normal smooth capsular contour. Parenchyma is appropriately finely textured and homogenous with normal echogenicity relative to surrounding tissue (hyperechoic to liver). No focal nodules or masses are observed. Splenic vasculature appears normal.

Liver

Liver is subjectively enlarged (swollen contour). Mild parenchymal remodeling with diffusely mildly coarse architecture and increased portal markings is present. No focal nodules or masses are observed. Visible vasculature and biliary tree appear normal without distension or congestion.

The gallbladder is non-distended in size. The wall is smooth without visible thickening. Luminal contents are primarily anechoic. There is no evidence of cystic or common bile duct dilation.

Gastrointestinal

The stomach wall is not well visualized in these images.

The visible small intestines are normal in wall thickness and layering (canine duodenum < 0.5 cm and feline duodenum < 0.4 cm; other < 0.3 cm). Small intestinal motility appears adequate (1-3 contractions per min). The lumen of the small intestine is empty with no evidence of obstruction, foreign material or infiltrative disease.



PATIENT

Tasha Dickinson/Walsh

The visible colon is normal in wall thickness (< 0.2 cm) and layering. Contents are consistent with normal formed feces and gas.

Pancreas

SPECIES

Feline

The observed pancreas is prominent (enlarged) in size, hypoechoic to surrounding tissue and irregular in shape with a swollen undulating contour. Pancreatic duct dilation is noted. Enhanced hyperechoic ill-defined surrounding fat is noted.

BREED

DSH

Free Abdomen

There is a small amount of anechoic free fluid noted, as well as diffusely enhanced hyperechoic mesenteric fat throughout the entire abdomen, which partially limits full visualization of some of the organs and could result in missed pathology (for example, the stomach is not well visualized).

SEX

Spayed Female

There is no apparent lymphadenopathy noted in these images.

ULTRASONOGRAPHIC FINDINGS

AGE

14 Years

- **Hypoechoic hepatomegaly** – This appearance is consistent with an acute hepatopathy or acute cholangiohepatitis. Infiltrative neoplasia (round cell neoplasia) should also be considered.

WEIGHT

10 Pounds

- Acute pancreatitis

- A small amount of free fluid is present, but the remainder of the abdomen is difficult to fully visualized due to markedly enhanced hyperechoic mesenteric fat, which could be secondary to pancreatitis. However, other pathology cannot be definitively ruled out based on these images at this time.

INTERPRETED BY

Beth Johnson, DVM
DACVIM

INTERPRETATION OF THE FINDINGS & FURTHER RECOMMENDATIONS

Further evaluation of the gastrointestinal tract and pancreas is recommended in the form of a gastrointestinal malabsorption panel (including cobalamin, folate, TLI and PLI) to Texas A&M GI Laboratory.

IMAGING PERFORMED BY

Christina

A fine needle aspirate of the liver could also be considered if patient's coagulation status is appropriate. However, given reportedly normal liver enzymes, etc., that diagnostic is likely of lower yield.

HOSPITAL NAME

Animal Health VC

Options for further evaluation of this patient include additional imaging in the form of an abdominal CT scan to help better differentiate possible pathology in the midst of the enhanced hyperechoic mesentery, or empirical supportive/symptomatic medical management of presumed acute pancreatitis with antiemetics, gastroprotectants, appetite stimulants, or other nutritional support up to and including a feeding tube if necessary, pain management, fluid therapy, broad-spectrum antibiotics, etc. could be initiated now with recheck imaging as the patient responds clinically and is more comfortable, etc., especially if clinical signs persist.

REFERRING VET

Dr. Rodriguez

If not already evaluated, a urinalysis and, if indicated based on urinalysis results, urine culture are recommended. If protein is present in an otherwise quiet sediment, protein quantification with a urine protein to creatinine ration is recommended.

INVOICE

42383

DATE

10/26/22



PATIENT

Tasha Dickinson/Walsh

SPECIES

Feline

BREED

DSH

SEX

Spayed Female

AGE

14 Years

WEIGHT

10 Pounds

INTERPRETED BY

Beth Johnson, DVM
DACVIM

IMAGING PERFORMED BY

Christina

HOSPITAL NAME

Animal Health VC

REFERRING VET

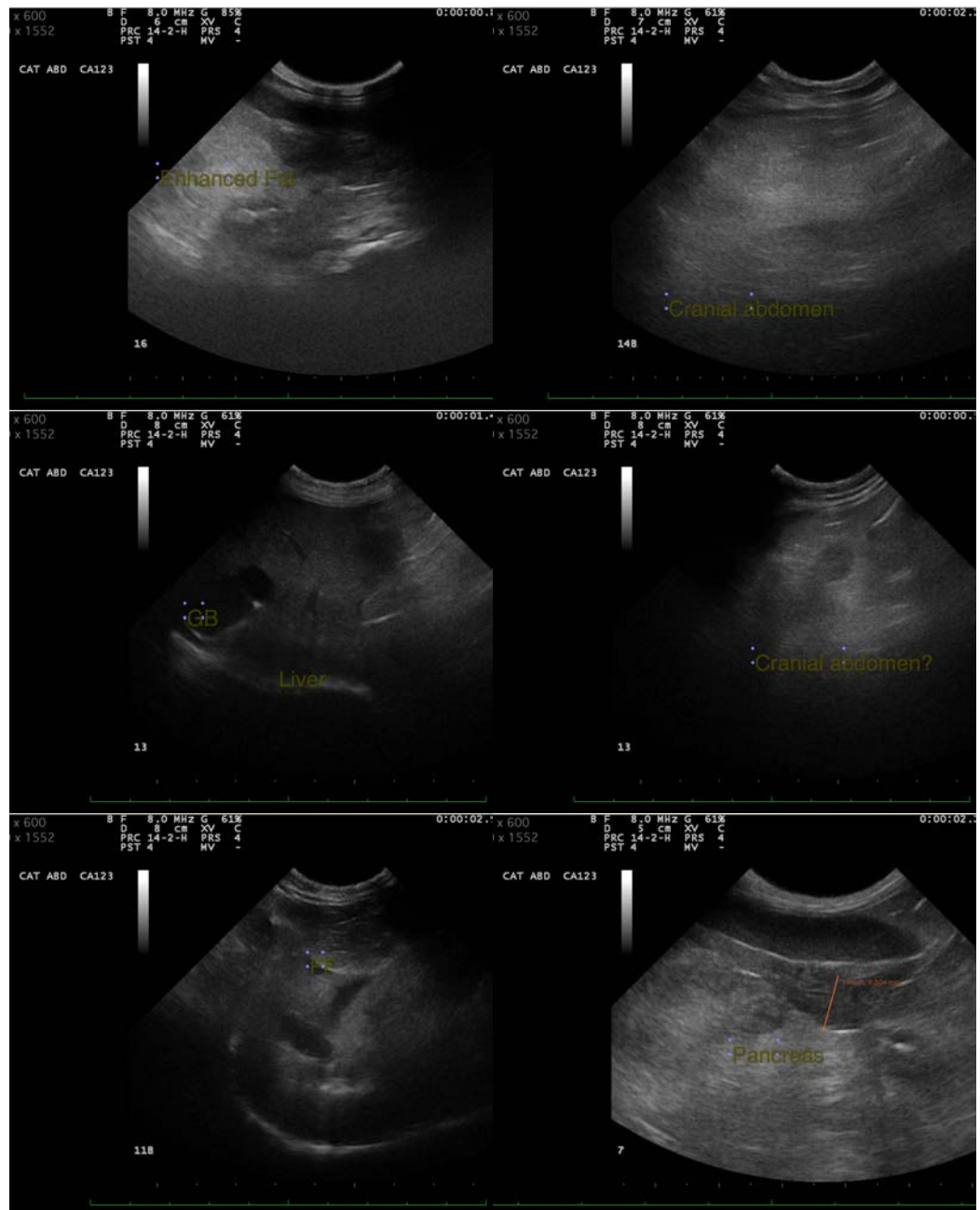
Dr. Rodriguez

INVOICE

42383

DATE

10/26/22





PATIENT

Tasha Dickinson/Walsh

SPECIES

Feline

BREED

DSH

SEX

Spayed Female

AGE

14 Years

WEIGHT

10 Pounds

INTERPRETED BY

Beth Johnson, DVM
DACVIM

IMAGING PERFORMED BY

Christina

HOSPITAL NAME

Animal Health VC

REFERRING VET

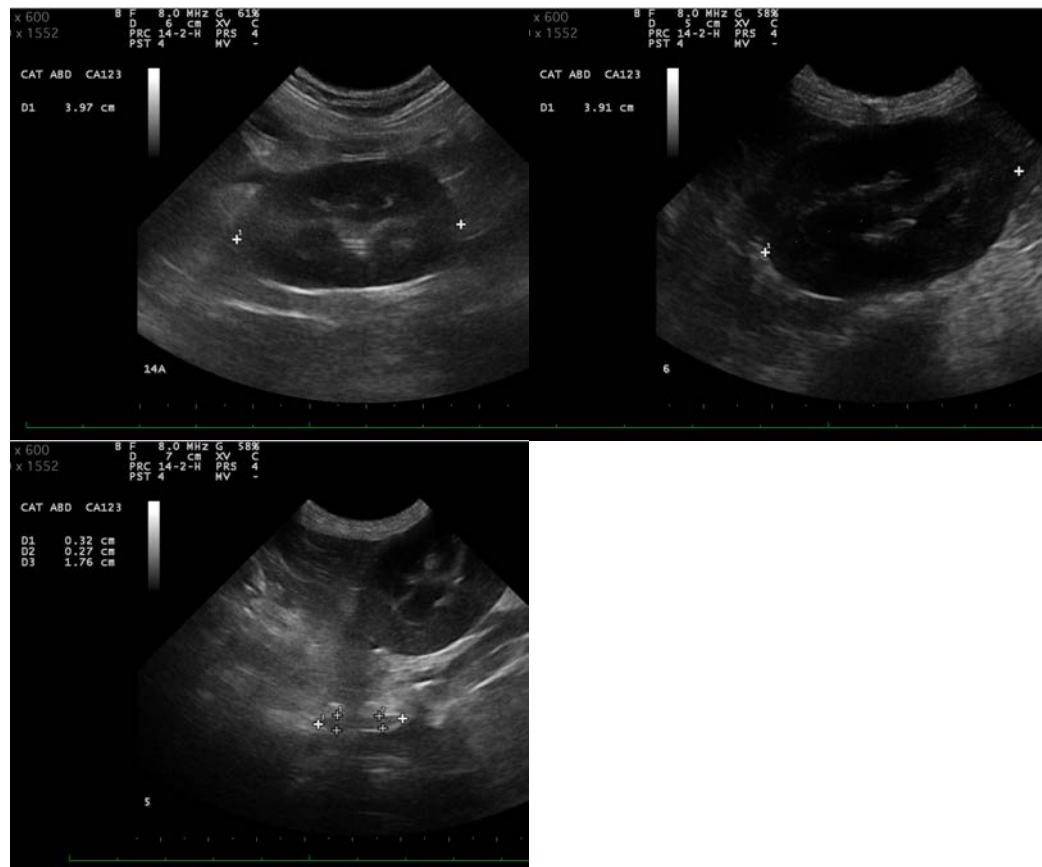
Dr. Rodriguez

INVOICE

42383

DATE

10/26/22



The information and recommendations provided are based on the images presented by the referring veterinarian/sonographer. No evaluation can be communicated regarding pathology that was not visible in the image/video clips provided.

Thank you for this referral. If the clinical or image interpretation does not parallel your findings or if I can be of any further assistance please contact me.

Beth Johnson, DVM, DACVIM
Beth.Johnson@sonopath.com